

Combined orthotopic heart transplantation and prophylactic ascending aorta replacement in a Marfan patient

Bir Marfan hastasında kombine ortotopik kalp nakli ve profilaktik çıkan aort replasmanı

Kaan Kirali, Ercan Eren, İlker Mataracı, Deniz Çevirme

Department of Cardiovascular Surgery, Kartal Koşuyolu Heart Education and Research Hospital, İstanbul

Prophylactic replacement of the ascending aorta during orthotopic heart transplantation in a Marfan patient has not been previously reported. In our clinic, a 37-year-old Marfan patient with a borderline dilatation of the ascending aorta (4.5 cm) underwent replacement of the ascending aorta during successful heart transplantation to prevent further complications in the ascending aorta.

Key words: Ascending aorta replacement; heart transplantation; Marfan syndrome.

Progressive aortic dilatation, with or without associated aortic valve incompetence, represents the most common cardiovascular manifestation requiring surgical treatment in Marfan patients. Elective prophylactic replacement of the ascending aorta is the first choice for surgical treatment in these patients.^[1] Aortic valve sparing or replacement depends on the aortic root and annulus pathology. A few patients may present with various additional cardiac pathologies, e.g. mitral valve regurgitation^[2] or dilatative cardiomyopathy.^[3] Aortic dissection or rupture is uncommon in cardiac allograft recipients, but it is a potential complication in those with Marfan syndrome, especially before^[3] or after heart transplantation.^[4] However, there are a couple of papers reporting simultaneous surgical repair of a complicated ascending aortic aneurysm in Marfan recipients.^[5,6] We report the first prophylactic ascending aorta replacement during the orthotopic heart transplant in a Marfan recipient with borderline aortic dilatation.

CASE REPORT

A 37-year-old male patient had suffered from palpitation, exertional dyspnea, and thoracic pain since 2004. He had been followed up for moderate aortic and mitral valve insufficiency, but he had developed refractory heart

Bir Marfan hastasında ortotopik kalp nakli sırasında profilaktik çıkan aort replasmanı uygulaması daha önce literatürde bildirilmemiştir. Kliniğimizde sınırdan çıkan aort dilatasyonu (4.5 cm) bulunan 37 yaşındaki bir Marfan hastasına, ileride gelişebilecek çıkan aort komplikasyonlarından koruma amacı ile başarılı kalp nakli sırasında çıkan aort replasmanı uygulandı.

Anahtar sözcükler: Çıkan aort replasmanı; kalp nakli; Marfan sendromu.

failure. During the follow-up period, he had multiple ventricular fibrillation attacks despite appropriate medical therapy. An automatic cardioverter-defibrillator was implanted in 2006 for the treatment of biventricular heart failure and to prevent intractable ventricular fibrillation episodes. He was referred to our hospital for cardiac transplantation due to end-stage cardiomyopathy in May 2007. He was treated for refractory heart failure in our intensive care unit for three weeks. A chest roentgenogram showed an enlarged cardiac silhouette with mediastinal widening (Figure 1a). Further echocardiographic examinations revealed a severe left ventricle failure with an ejection fraction of 20%, and the end-systolic and end-diastolic diameters of the left ventricle were 5.9 cm and 6.7 cm, respectively (Figure 2a). Moderate insufficiency for three leaflets (mitral, aortic and tricuspid) and borderline dilatation of the ascending aorta (4.4 cm) were observed upon echocardiographic examination. Computed tomography (CT) scans of the chest revealed a borderline dilatation of the ascending aorta (4.5 cm) without any dissection. He underwent orthotopic heart transplantation on May 29th, 2007. The cardiopulmonary bypass was established via bicaval cannulas and proximal arcus aorta. The donor heart was procured using a standard technique

Received: May 4, 2009 *Accepted:* August 10, 2009

Correspondence: Kaan Kirali, M.D. Kartal Koşuyolu Yüksek İhtisas Eğitim ve Araştırma Hastanesi Kalp ve Damar Cerrahisi Kliniği, 34846 Kartal, İstanbul, Turkey. Tel: +90 216 - 459 44 40 e-mail: imkkirali@yahoo.com

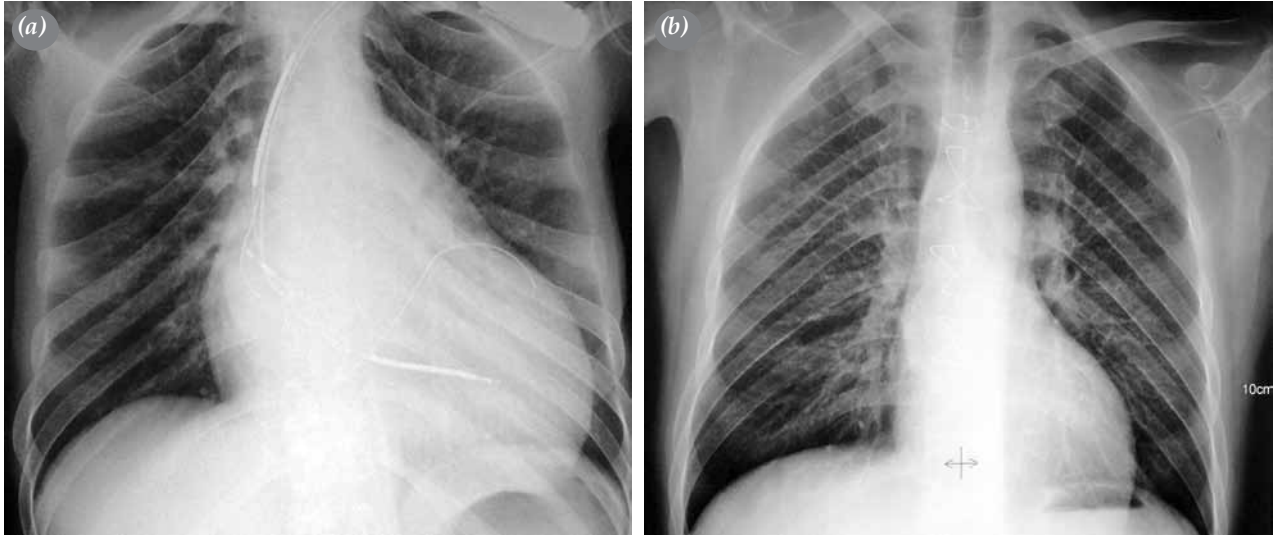


Figure 1. (a) Chest roentgenogram shows the cardiac enlargement with a normal silhouette of the ascending aorta and permanent defibrillator preoperatively. (b) Postoperative chest film shows a normal sized heart with ascending aorta.

allowing excess length of the donor aorta in order to reconstruct the recipient ascending aorta. When the donor heart arrived at the theater, we immediately began continuous retrograde isothermic blood cardioplegia to perfuse the donor heart until the cross-clamp was removed. The aorta was cross-clamped at the proximal end of the arcus aorta (in front of the brachiocephalic branch), and the recipient's heart with the whole dilated ascending aorta was excised. The patient was cooled systemically to 28 °C and orthotopic implantation was performed using a bicaval technique. A 28-mm tube graft (Vascutek Ltd, Inchinnan, Scotland, UK) was anastomosed between the donor aorta and recipient arcus aorta. The operation was finished in a standard manner.

At the end of the transplantation, the pacemaker was removed. Total cross-clamp time was 96 minutes, bypass time was 135 minutes, and both cold and total ischemic times of the donor heart were similar (145 minutes). Cyclosporine A, prednisone, and azathioprine were given for immunosuppression. At the first year control (Figure 1b), a chest film showed a normal cardiac silhouette, and echocardiography (Figure 2b) and CT scan revealed good left ventricular function without any complication of the intrathoracic aorta.

DISCUSSION

The main cause of death in Marfan patients is a fatal complication of the intrathoracic aorta, and the

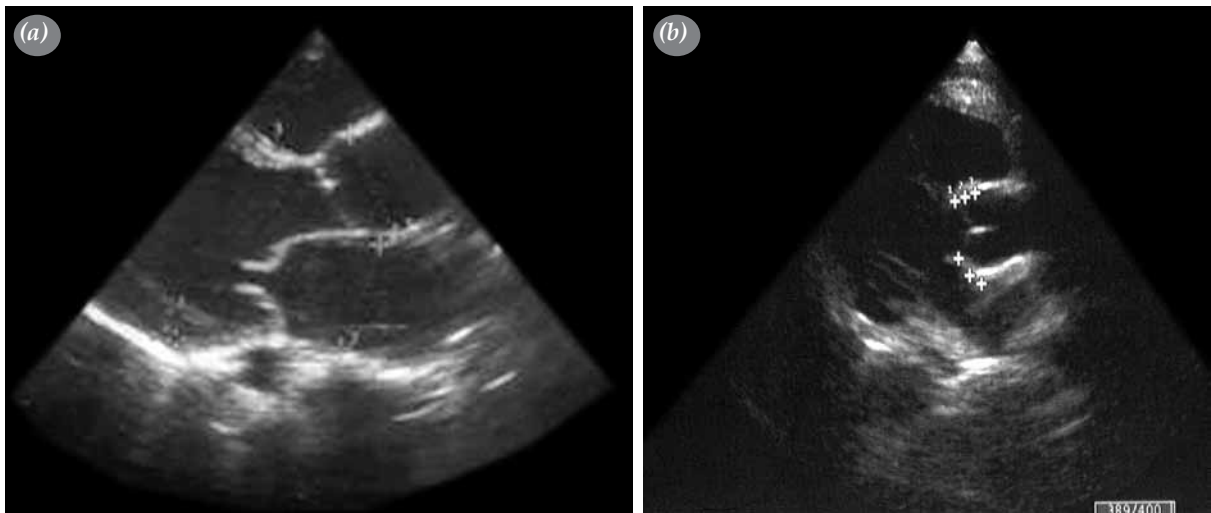


Figure 2. (a) Preoperative echocardiography shows severe heart failure. (b) Postoperative control echocardiography shows normal ventricular functions and normal donor's aortic root.

biggest improvement in life expectancy seen in Marfan syndrome is attributable to early recognition of thoracic aorta pathologies. As we reported previously, the long-term survival rate was 92% at 12 years, and aggressive surgical intervention did not impair surgical outcome while decreasing reoperation risk in Marfan patients.^[7] Prophylactic replacement of the ascending aorta must be the first choice for the treatment of Marfan patients. On the other hand, primary cardiomyopathy or long-standing underlying valvular disease may lead to development of end-stage heart disease in Marfan patients. Structural and functional abnormalities of the fibrillin-1 gene may play a role in the development of this type of heart failure.^[8]

The long-term survival rates for adult heart transplantation show that heart transplantation is the first choice for the treatment of end-stage heart failure. One-year and 10-year survival rates are approximately 80%^[9,10] and 50%^[10] respectively. Knosalla et al.^[3] concluded that heart transplantation could be performed in Marfan patients with good long-term survival just as it can be done in patients without Marfan syndrome. They found the incidence of Marfan recipients as 0.7% in 1459 primary orthotopic heart transplantations, and they calculated the survival rate as 80% at one year and 64% at 10 years. As they maintained, the close follow-up and timely operation of aortic pathologies is mandatory.

We have performed 61 orthotopic heart transplantations since 1989, and the incidence of Marfan recipients is 1.58% in our practice. This case represents an unusually high-risk patient due to the presence of borderline dilatation of the ascending aorta without any complication. His primary cardiomyopathy developed independent of the underlying valvular disease, and the dilatation of the ascending aorta begun de novo. Because he had a borderline dilatation of the ascending aorta, we replaced it with a tubular graft to prevent later complications. After the first postoperative year, we examined him using a thoracoabdominal computed tomogram to see whether a new aortic pathology had developed or not, and we found his aorta to be normal in size and anatomy.

In the future, more transplant centers will be asked to evaluate Marfan recipients with intrathoracic aortic pathology. We believe that prophylactic replacement of the ascending aorta with borderline dilatation during orthotopic heart transplantation is the best way to improve the long-term survival in Marfan patients by

preventing vascular complications. For this reason, we suggest that Marfan patients with end-stage heart failure, with or without intrathoracic aortic pathology, should not be refused for heart transplantation, and they should be referred to centers with experience in both heart transplantation and aortic surgery.

Declaration of conflicting interests

The authors declared no conflicts of interest with respect to the authorship and/or publication of this article.

Funding

The authors received no financial support for the research and/or authorship of this article.

REFERENCES

1. Groenink M, Lohuis TA, Tijssen JG, Naeff MS, Hennekam RC, van der Wall EE, et al. Survival and complication free survival in Marfan's syndrome: implications of current guidelines. *Heart* 1999;82:499-504.
2. Bozbuga N, Erentug V, Kıralı K, Akinci E, Yakut C. Surgical management of mitral regurgitation in patients with Marfan syndrome. *J Heart Valve Dis* 2003;12:717-21.
3. Knosalla C, Weng YG, Hammerschmidt R, Pasic M, Schmitt-Knosalla I, Grauhan O, et al. Orthotopic heart transplantation in patients with Marfan syndrome. *Ann Thorac Surg* 2007;83:1691-5.
4. Englesbe MJ, Wu AH, Clowes AW, Zierler RE. The prevalence and natural history of aortic aneurysms in heart and abdominal organ transplant patients. *J Vasc Surg* 2003;37:27-31.
5. Chu SH, Chien CY, Hsu RB, Chen MF, Chen YS, Ko WJ, et al. Combined heart transplantation and resection of dissecting aneurysm of ascending aorta and aortic arch: a case report. *Ann Thorac Cardiovasc Surg* 2000;6:61-4.
6. Kocher AA, Ehrlich MP, Widhalm G, Wolner E, Laufer G. Cardiac transplantation and simultaneous surgical repair of an aortic aneurysm. *Ann Thorac Surg* 1999;68:1391-2.
7. Kıralı K, Erentuğ V, Rabuş MB, İzgi A, Bozbuğa NU, Erkanlı K, et al. Extensive aortic surgery in Marfan syndrome: 16-year experience. *Asian Cardiovasc Thorac Ann* 2003;11:337-41.
8. Dean JC. Marfan syndrome: clinical diagnosis and management. *Eur J Hum Genet* 2007;15:724-33.
9. Kıralı K, Mansuroğlu D, Ömeroğlu SN, Tuncer A, Eren E, Toker ME, et al. 12-year Koşuyolu experience in cardiac transplantation. *Turkish J Thorac Cardiovasc Surg* 2001;9:62-7.
10. Taylor DO, Edwards LB, Boucek MM, Trulock EP, Deng MC, Keck BM, et al. Registry of the International Society for Heart and Lung Transplantation: twenty-second official adult heart transplant report-2005. *J Heart Lung Transplant* 2005;24:945-55.