

Primary cardiac angiosarcoma and diffuse pulmonary hemorrhage: a case report

Primer kardiyak anjiyosarkom ve diffüz pulmoner hemoraji: Olgu sunumu

Melih Büyüksirin,¹ Necmettin Yakut,⁴ Gülrü Polat,¹ Adnan Kazım Usalan,¹
Tayfun Gökdoğan,² Nur Yücel,¹ Ali Küpeli³

¹Department of Chest Diseases, Dr. Suat Seren Chest Diseases and Chest Surgery, Training and Research Hospital, İzmir;

²Department of Cardiovascular Surgery, İzmir Atatürk Training and Research Hospital, İzmir;

³Department of Pathology, Solar Pathology Laboratory, İzmir;

⁴Department of Cardiovascular Surgery, Private Gazi Hospital, İzmir

Primary cardiac angiosarcoma is a very rare malignant tumor with very poor prognosis. Symptoms of the disease are nonspecific. One of the rare clinical presentations is diffuse pulmonary hemorrhage. A 61-year-old male was admitted to our clinic with the complaints of right side pain lasting for 10 days, cough and hemoptysis. The chest X-ray showed bilateral nodular lesions and increased cardiothoracic index. Thoracic computed tomography revealed cardiomegaly, showing a mass in 7x5 cm in the anterolateral right atrium with ground-glass appearance, predominantly in the mid and lower zones of bilateral lung fields. Echocardiography showed dilatation and hypertrophy of the left ventricle. The case underwent surgery with the initial diagnosis of myxoma. During surgery, cardiac angiosarcoma was diagnosed. The patient died due to respiratory failure soon after surgery. In this article, we present a case report, discussing the details of the diagnostic process based on pulmonary symptoms along with certain challenges.

Key words: Angiosarcoma; diffuse pulmonary hemorrhage; heart neoplasm.

Primary cardiac neoplasms are rare entities with an autopsy incidence ranging from 0.001-0.03%.^[1] About 75% of primary tumors are benign with 75% of these being atrial myxomas.^[2] The malignancy rate of primary cardiac tumors is 25%, and one third of these tumors are angiosarcomas. The nonspecific presentation often delays diagnosis and surgical intervention. The most common symptoms are dyspnea, thoracoabdominal

Primer kardiyak anjiyosarkom, çok kötü seyreden, oldukça nadir görülen kötü huylu bir tümördür. Hastalık semptomları nonspesifiktir. Ender klinik görünümünden biri de, diffüz pulmoner hemorajidir. Altmış bir yaşında erkek olgu, 10 gündür devam eden sağ yan ağrısı, öksürük ve kan tükürme yakınmaları ile kliniğimize başvurdu. Akciğer grafisinde iki taraflı nodüler lezyonlar ve kardiyotorasik indekste artış izlendi. Toraks bilgisayarlı tomografide, kardiyomegali, sağ atrium anterolateral komşuluğunda 7x5 cm kitle lezyonu, her iki akciğerde orta ve alt zonlarda buzlu cam görünümleri izlendi. Ekokardiyografide sol ventrikül dilate ve hipertrofik idi. Olgu miksuma ön tanısı ile ameliyat edildi. Ameliyat sırasında kardiyak anjiyosarkom saptandı. Hasta, ameliyattan kısa bir süre sonra, solunum yetmezliği nedeniyle kaybedildi. Bu makalede, birtakım tanısız zorluklar ile birlikte, pulmoner semptomlar göz önünde bulundurularak yürütülen tanısız sürecin ayrıntılı olarak irdelenmesi amacıyla bir olgu çalışması sunuldu.

Anahtar sözcükler: Anjiyosarkom; diffüz pulmoner hemoraji; kalp tümörü.

pain, lack of appetite, fatigue, hemoptysis, nausea, vomiting, fever, weight loss, and night sweats.^[3] Diffuse pulmonary hemorrhage is rarely the presenting manifestation of angiosarcoma.^[4]

Our case consulted with complaints of chest pain, cough, and hemoptysis. The disease progressed with pulmonary alveolar hemorrhage. The case was operated on with the prediagnosis of myxoma. Cardiac

Received: May 21, 2009 Accepted: September 23, 2009

Correspondence: Gülrü Polat, M.D. Dr. Suat Seren Göğüs Hastalıkları ve Cerrahisi Eğitim ve Araştırma Hastanesi, Göğüs Hastalıkları Kliniği, 35110 Yenisehir, İzmir, Turkey. Tel: +90 232 - 433 33 33 e-mail: gulruerbay@yahoo.com

angiosarcoma was identified intraoperatively. We present the case because of the difficulties in the diagnosis, diagnosis by pulmonary symptoms, and death by respiratory failure within a short time.

CASE REPORT

A 61-year-old man consulted with chest pain, cough, and hemoptysis which had lasted for 10 days. There were no special features in the patient's past history. He had smoked 90 pack-years. His blood pressure was 130/80 mmHg with a body temperature of 36.8 °C, pulse rate of 100/minute, and respiration rate of 16/minute. Bilateral rales were heard over the base of the lungs. The heart was tachycardic. The leukocyte count was 7400/mm³, erythrocyte was 3380x10³/mm³, hemoglobin was 9.9 gr/dl, and platelet count was 274x10³/mm³. Routine biochemical values were in the normal range. Arterial blood gas values on room air were: pO₂ 84.0 mmHg, pCO₂ 31.0 mmHg, pH 7.44. A chest X-ray showed bilateral nodular infiltrates and an increase in cardiothoracic index (Figure 1). Thoracic computed tomography (CT) showed a 5x7 cm mass in the right atrium and ground-glass appearance in the middle and lower zones (Figure 2). The left ventricle was dilated and hypertrophic on echocardiography (ECHO). Blood was noticed without any endobronchial lesion on fiberoptic bronchoscopy (FOB). A parenchymal biopsy was not performed because of the risk of hemorrhage. Hemosiderin-loaded macrophages among leucocytes were observed by bronchoalveolar lavage (BAL). At this point, the patient's dyspnea had progressed, which was also observed on chest X-ray. The hemoglobin level had fallen to 6.7 gr/dl. Repeat blood tests showed pO₂ 79.6 mmHg, pCO₂ 37 mmHg, pH 7.46, a transfer factor of the lung for carbon monoxide (TLCO) of 166%, and a gas transfer coefficient [Kco(Hb)] of

189%. Antinuclear antibody (ANA) was borderline positive, and the anti-deoxyribonucleic acid (anti-DNA), perinuclear antineutrophil cytoplasmic antibodies (pANCA), and antineutrophil cytoplasmic antibody (cANCA) values were negative. We evaluated the case as diffuse pulmonary hemorrhage and started 1gr/day methylprednisolone for three days which decreased to 50 mg/day orally afterwards. In addition, two units of erythrocyte suspension were given. The patient became better after five days. We also observed regression via chest X-ray. The TLCO value also regressed to 110%. Repeat ECHO revealed a 4x7 cm mass in the right atrium. Because we observed clinical and laboratory regression, we evaluated the patient as pseudovasculitis secondary to myxoma and undertook surgery via a median sternotomy. During the operation, tumor tissue was found which covered the surface of the right atrium and all of the anterolateral pericardium reaching over the right ventricle, which was fragile and necrotic. The tumor was totally excised. A pathological examination revealed the presence of angiosarcoma. Three weeks after the operation, pleural effusion on the right side and bilateral infiltration were observed on the chest X-ray. This effusion was hemorrhagic, but no malignant cells were detected cytologically. Positron emission tomography (PET) was performed. Fluorodeoxyglucose (FDG) involvement was very high in the right atrium, but it was not high in the lung parenchyma. Positron emission tomography showed no other primary origin site or metastasis. Nevertheless, the patient's general condition deteriorated, and he died from respiratory failure within a short period of time.

DISCUSSION

The prognosis for primary cardiac angiosarcomas is poor despite noninvasive radiographic methods and early surgical intervention. Life expectancy is less than six months.^[3] There is very high metastatic potential,

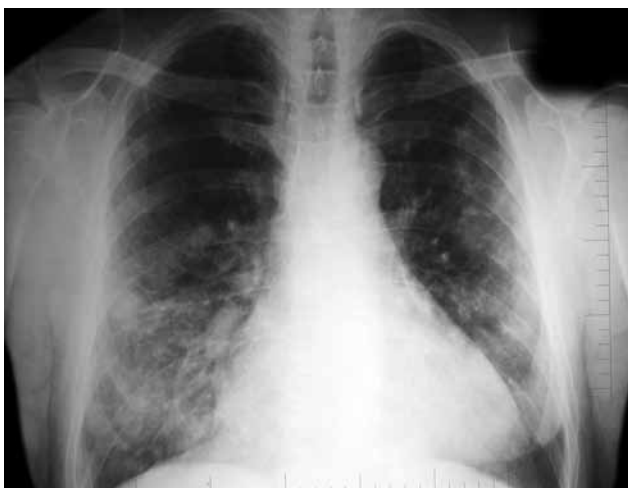

Figure 1. The chest X-ray at admission.

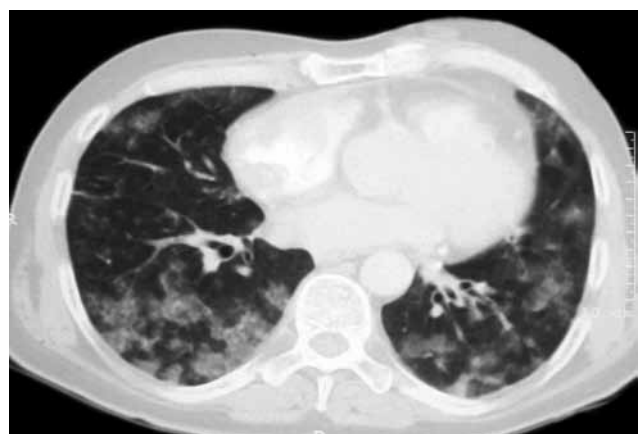


Figure 2. The thoracic computed tomography at admission.

especially directed toward the lung and liver.^[5] Most of the patients presented with symptoms of pericardial disease or right-sided congestive heart failure. Usually, cardiomegaly and electrocardiographic changes were observed. Many authors have stressed the constancy of symptoms and clinical signs.^[3,6]

Zwaveling et al.^[6] made a tentative diagnosis of idiopathic pulmonary hemosiderosis in their case because they had seen bilateral nodular infiltration on a chest X-ray, had heard bilateral rales over the lungs, and had noticed the patient complaining of hemoptysis and anemia. However, within a short period of time, respiratory failure developed, the hemoglobin level fell, and a thoracotomy was performed to obtain a histological diagnosis in which a biopsy yielded the angiosarcoma result. Twelve days later, the patient died of respiratory failure. At postmortem examination, cardiac angiosarcoma was found infiltrating the atrial wall. They concluded that although angiosarcoma of the heart is a rare tumor, its presence should be suspected in patients with hemoptysis and nodular chest X-ray abnormalities, even in the absence of symptoms of right-sided cardiac disease.^[6]

Our patient consulted with pulmonary symptoms and findings. Because of the hemosiderin-loaded macrophages observed in BAL, the existence of anemia and hemoptysis, and a mass in the right atrium, we first thought the patient had myxoma complicated with pseudovasculitis.^[7,8] Cardiac mass could not be accurately recognized despite two transthoracic and one transesophageal echocardiographies (ECHOs). Bic et al.^[5] reported patients who consulted with pulmonary infiltrates diagnosed as angiosarcoma by open lung biopsy and who died because of respiratory failure after a short period of time. The primary cardiac tumor was diagnosed only at autopsy. Despite four successive ECHOs performed by three different physicians, a diagnosis of intracardiac tumor was never suggested. The ECHOs were reexamined after the diagnosis was established, and no evidence of an intracardiac tumor was observed. The limited sensitivity of ECHO in the diagnosis of cardiac tumors has been observed previously. No definitive interpretation has been given to explain this discrepancy; however, varied and atypical echogenicity along with the concentric development of the tumor have been suggested as contributory factors.

Classic clinical features of diffuse pulmonary hemorrhage include hemoptysis, anemia, and diffuse radiographic infiltrates. The most common causes are Goodpasture syndrome, vasculitis, such as Wegener's granulomatosis and microscopic polyangiitis (MPA), and connective tissue diseases, including systemic

lupus erythematosus and idiopathic pulmonary hemosiderosis. Diffuse pulmonary hemorrhage is rarely the presenting manifestation of angiosarcoma.^[4-6] Adem et al.^[4] evaluated 16 patients and concluded that diffuse pulmonary hemorrhage is a rare presentation of angiosarcoma and that angiosarcoma should be included in the differential diagnosis of diffuse pulmonary hemorrhage, especially in young adults. In these cases, metastatic angiosarcoma was diagnosed by open lung biopsy or at autopsy. A transbronchial lung biopsy was performed in five patients, but the results were nondiagnostic. The primary tumor was found in the right atrium in seven cases at autopsy. In our patient, because we observed clinical and laboratory regression after steroid therapy, we evaluated the patient as having pseudovasculitis secondary to myxoma and proceeded to operate. A right atrium angiosarcoma was detected intraoperatively. We emphasize that difficulties exist in the diagnosis of cardiac angiosarcoma along with the clinical presentation of diffuse pulmonary hemorrhage.

The therapy for primary cardiac tumors is still controversial, but surgery represents the therapy of choice in cases of localized disease and is conditioned by the site of a tumor and by the frequent presence of metastases. The survival percentage in patients treated with surgery ranges from two to 55 months with a median survival of 14 months. Despite adverse prognostic data, there are reported cases of patients with angiosarcoma treated with only partial resection followed by chemotherapy and radiotherapy who survived for 34 or even 53 months.^[9,10] However, Antonuzzo et al.^[11] reported the case in which the tumor was partially excised and a four cycles of chemotherapy were given. The patient died after three months. The most frequently used chemotherapy regimens are cyclophosphamide or doxorubicin or vincristine or dacarbazine or mitomycin-C along with cisplatin.^[3] Sinatra et al.^[12] reported that the combination of surgical resection and radiation can reduce the mass and eliminate symptoms despite an incomplete resection.

In conclusion, primary cardiac angiosarcoma is a fatal disease, and the prognosis is usually bad.

Declaration of conflicting interests

The authors declared no conflicts of interest with respect to the authorship and/or publication of this article.

Funding

The authors received no financial support for the research and/or authorship of this article.

REFERENCES

1. Dein JR, Frist WH, Stinson EB, Miller DC, Baldwin JC, Oyer PE, et al. Primary cardiac neoplasms. Early and late results of surgical treatment in 42 patients. *J Thorac Cardiovasc Surg* 1987;93:502-11.
2. Vander Salm TJ. Unusual primary tumors of the heart. *Semin Thorac Cardiovasc Surg* 2000;12:89-100.
3. Herrmann MA, Shankerman RA, Edwards WD, Shub C, Schaff HV. Primary cardiac angiosarcoma: a clinicopathologic study of six cases. *J Thorac Cardiovasc Surg* 1992;103:655-64.
4. Adem C, Aubry MC, Tazelaar HD, Myers JL. Metastatic angiosarcoma masquerading as diffuse pulmonary hemorrhage: clinicopathologic analysis of 7 new patients. *Arch Pathol Lab Med* 2001;125:1562-5.
5. Bic JF, Fade-Schneller O, Marie B, Neimann JL, Anthoine D, Martinet Y. Cardiac angiosarcoma revealed by lung metastases. *Eur Respir J* 1994;7:1194-6.
6. Zwaveling JH, van Berkhout FT, Haneveld GT. Angiosarcoma of the heart presenting as pulmonary disease. *Chest* 1988;94:216-8.
7. Nishio Y, Ito Y, Iguchi Y, Sato H. MPO-ANCA-associated pseudovasculitis in cardiac myxoma. *Eur J Neurol* 2005;12:619-20.
8. Chaudhry AA, Dobson CM, Simpson FG. Pulmonary haemosiderosis associated with left atrial myxoma. *Thorax* 1991;46:539-40.
9. Percy RF, Perryman RA, Amornmarn R, Lammert N, Conetta DA, Bass TA, et al. Prolonged survival in a patient with primary angiosarcoma of the heart. *Am Heart J* 1987;113:1228-30.
10. Nakamichi T, Fukuda T, Suzuki T, Kaneko T, Morikawa Y. Primary cardiac angiosarcoma: 53 months' survival after multidisciplinary therapy. *Ann Thorac Surg* 1997;63:1160-1.
11. Antonuzzo L, Rotella V, Mazzoni F, Doni L, Bianchini D, Garbini F, et al. Primary cardiac angiosarcoma: a fatal disease. *Case Report Med* 2009;2009:591512.
12. Sinatra R, Brancaccio G, di Gioia CR, De Santis M, Sbraga F, Gallo P. Integrated approach for cardiac angiosarcoma. *Int J Cardiol* 2003;88:301-4.