

## **Intracavitary aspergilloma after hydatid cyst surgery: a case report**

*Akciğer kist hidatik cerrahisi sonrasında intrakaviter aspergilloma: Olgu sunumu*

**Hakan Kiral,<sup>1</sup> İrfan Yalçınkaya,<sup>1</sup> Mustafa Küpeli,<sup>1</sup> Recep Demirhan<sup>2</sup>**

<sup>1</sup>Department of Thoracic Surgery, Süreyyapaşa Chest Disease and Chest Surgery  
Training and Research Hospital, İstanbul, Turkey;

<sup>2</sup>Department of Thoracic Surgery, Dr. Lütfi Kırdar Kartal Training and Research Hospital, İstanbul, Turkey

The patient who underwent cystotomy and capitonage surgery of right lung due to a hydatid cyst four years ago in another centre was admitted to our clinic with the complaint of recurrent hemoptysis. Chest computed tomography revealed a cavitory lesion located in the posterior segment of the right lower lobe. Rethoracotomy and right lower lobectomy were performed in the patient for hemoptysis and cavitory lesion. Pathological examination showed bronchiectasis, intraparenchymal hemorrhage and intracavitary aspergilloma. Aspergilloma may develop within residual cavities after pulmonary surgery for hydatid cyst. In this article, a very rare case was presented to emphasize the significance of this pathology for surgical technique, follow-up and treatment.

**Key words:** Aspergilloma; capitonage; cystotomy; pulmonary hydatid cyst.

Hydatid cyst is a zoonotic disease caused by *Echinococcus granulosus* while *Aspergillus* is a saprophytic fungus which leads to allergic pulmonary aspergillosis and aspergilloma along with semi-invasive and invasive aspergillosis.<sup>[1]</sup> Pulmonary aspergilloma generally develops within a previously existing cavity in the lungs. Tuberculosis, sarcoidosis, bronchiectasis, and some other cavitory pulmonary diseases may be complicated with aspergilloma. Tuberculosis is the disease which is most commonly accompanied by aspergilloma, but its concurrence with *Aspergillus* and hydatid cyst is a rare condition. In the literature, there are only a few case reports regarding this concurrence.

### **CASE REPORT**

A 20-year-old male was admitted to our department complaining of recurrent hemoptysis. Four years

Dört yıl önce başka bir merkezde sağ akciğerde kist hidatik nedeniyle kistotomi ve kapitonaj ameliyatı yapılan hasta, tekrarlayan hemoptizi yakınması ile kliniğimize başvurdu. Göğüs bilgisayarlı tomografide sağ alt lob posterior segmentte yerleşik kaviter lezyon tespit edildi. Hastaya, hemoptizi ve kaviter lezyon nedeniyle, tekrar torakotomi ve sağ alt lobektomi yapıldı. Patolojik inceleme bronşektazi, parenkim içi hemoraji ve intrakaviter aspergilloma olduğunu ortaya çıkardı. Kist hidatik ameliyatları sonrası kalan rezidüel boşlukların içinde de aspergilloma gelişebilir. Bu yazıda cerrahi teknik, takip ve tedavide bu patolojinin dikkate alınması gerektiğini vurgulamak amacıyla, çok nadir rastlanan bir olgu sunuldu.

**Anahtar sözcükler:** Aspergilloma; kapitonaj; kistotomi; pulmoner kist hidatik.

previously, he had undergone a cystotomy and capitonage at another center with no perioperative and postoperative complications. The patient had complained of cough and bloody sputum two years before arriving at our facility, but he recovered from this spontaneously within a short period of time. His cough and hemoptysis developed suddenly seven months prior to his admission, and he had a hemorrhage of about 200 ml.

A bit later, he had occasional small amounts of hemoptysis, which ultimately resulted in his referral to our department for surgical evaluation. The patient's history revealed nothing special except for the previously mentioned pulmonary surgical procedure due to a hydatid cyst. The physical examination findings were normal, and no special features were determined by routine laboratory examination. Computed tomography (CT) revealed a cavitory lesion located on the posterior

*Received:* August 17, 2009 *Accepted:* November 12, 2009

Correspondence: Hakan Kiral, M.D. Süreyyapaşa Göğüs Hastalıkları ve Göğüs Cerrahisi Eğitim ve Araştırma Hastanesi, 34844 Maltepe, İstanbul, Turkey. Tel: +90 216 - 421 42 00 e-mail: kiralhakan@yahoo.com

segment of the right lower lobe that was compatible with the previous surgery. It was 3x3x2 cm in size with a thick wall and irregular internal and external borders. Radiodense areas were seen within the cavity (Figure 1). A fiberoptic bronchoscopy was performed, and the findings were normal. A bronchoalveolar lavage was taken and sent for specific and nonspecific examinations, and the results were reported as negative.

A rethoracotomy was performed due to a persistent hydatid cyst cavity leading to hemoptysis, and this revealed the dense adhesions of the lower lobe to the chest wall. After adhesiolysis of the lung, the cavitory lesion was found to be palpable within the lower lobe. At first, a wedge resection was thought to be appropriate. However, the pulmonary lesion could not be completely resected by either a wedge resection or segmentectomy. In addition, pulmonary function is permissive for a lobectomy, and a right lower lobectomy was performed. The postoperative period was uneventful, so the patient was discharged on seventh postoperative day. A histopathological examination of the lower lobectomy material revealed bronchiectasis, intraparenchymal hemorrhage, and intracavitary aspergilloma (Figure 2). Follow-up physical and radiological examinations in the 18<sup>th</sup> postoperative month were found to be normal.

**DISCUSSION**

Many cavitory pulmonary diseases, including tuberculosis, sarcoidosis, bronchiectasis, bronchial cysts, and bullae, may form a convenient environment for aspergilloma. Among these diseases, tuberculosis is the most commonly associated condition.<sup>[2]</sup> Insufficient drainage is believed to facilitate the development of *Aspergillus* on the wall of such cavities. Immune

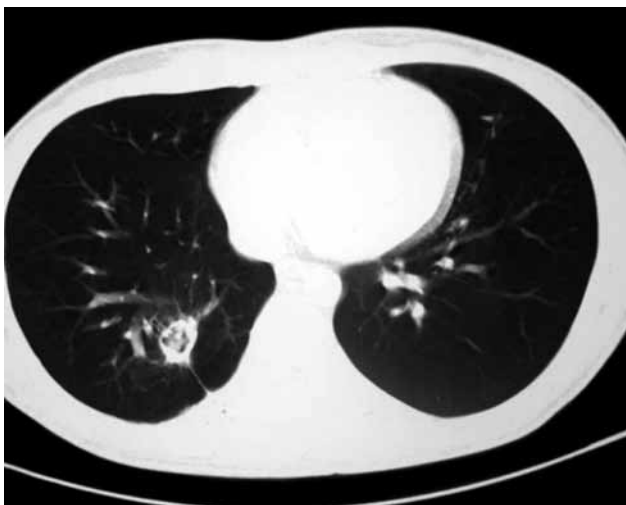deficiency or pulmonary structural deformities are predisposing factors for aspergillosis.

*Aspergillus* tends to invade vessel walls; therefore, the most frequent symptom seen in pulmonary *Aspergillus* is hemoptysis. When our patient was admitted, the only symptom was hemoptysis, and this had been continuing intermittently for the previous two years.

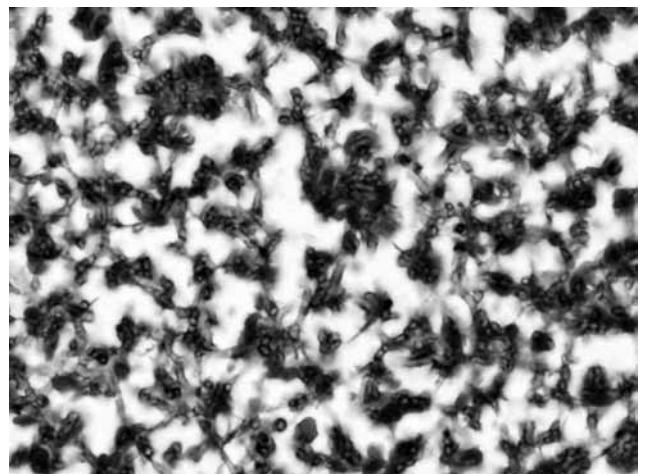
Radiological imaging methods are very effective in both *Echinococcus* and *Aspergillus*. In aspergilloma, the typical image is of a mobile intracavitary mass with a peripheral air crescent.<sup>[3]</sup> However, the sensitivity and specificity of imaging methods needed to determine the *Aspergillus* colonies within a hydatid cyst are unclear.

Aspergilloma may be seen within residual cavities which develop after surgery as well as in patients with a hydatid cyst if it spontaneously ruptures. The amount of time required for the onset of aspergilloma varies. Some cases have been admitted with aspergilloma many years after cystotomies, but it has developed in other patients after only six months.<sup>[4-6]</sup>

The goal of surgical treatment for a hydatid cyst in the lung is to avoid resection and protect pulmonary parenchyma. This is achieved by removing of the cyst membrane, suturing the bronchial openings, and obliterating the residual cavities with sutures (capitonnage). Some surgeons have suggested that the residual cavity eventually obliterates, so good results can also be obtained without capitonnage. However, the cavity remains if the cystic cavity is left open or previously sutured bronchial openings are reopened, and this cavity may form the basis for potential aspergilloma development.<sup>[4]</sup> Similarly, in our case, although capitonnage was reported, the cystic cavity was



**Figure 1.** A thick wall and irregular internal and external borders along with radiodense areas were seen within the cavity.



**Figure 2.** Histological findings, showed aspergillus hyphae with double-contour among the erythrocytes and neutrophil leucocytes (H-E x 40).

not obliterated. As a results, aspergilloma colonizing within this cavity caused severe hemoptysis.

The recommended surgical method for aspergilloma is anatomical resection for patients with adequate pulmonary function. The amount of resection is based on the extent of the underlying disease, the localization of the aspergilloma, and the patient's pulmonary reserve. Cavernostomy or the insertion of an intracavitary antifungal agent may be advised if resection is not possible due to impaired pulmonary function.<sup>[5]</sup> A wedge resection or segmentectomy could not provide proper treatment in our patient. For this reason, a right lower lobectomy was performed.

If the surgeon is sure of the existence of a hydatid cyst, he may not take into consideration the pathology report, but sufficient sampling of the excised specimens and careful examination of the sections stained with hematoxylin and eosin (H-E) are crucial. In a retrospective study which reevaluated 100 cases with a hydatid cyst pathologically, two cases with concomitant aspergillosis and a hydatid cyst were seen.<sup>[1]</sup> Therefore, it should be kept in mind that special care must be given to the examination of surgical specimens in order to note any further vital complications.

Finally, whether the surgical method includes capitonnage or not, it is worth noting that an opportunistic aspergilloma infection may occur within the residual cavities that remain after a hydatid

cyst operation. Therefore, surgeons should strive to completely obliterate the cystic cavities during surgery.

#### **Declaration of conflicting interests**

The authors declared no conflicts of interest with respect to the authorship and/or publication of this article.

#### **Funding**

The authors received no financial support for the research and/or authorship of this article.

#### **REFERENCES**

1. Koçer NE, Kibar Y, Güldür ME, Deniz H, Bakir K. A retrospective study on the coexistence of hydatid cyst and aspergillosis. *Int J Infect Dis* 2008;12:248-51.
2. Zmeili OS, Soubani AO. Pulmonary aspergillosis: a clinical update. *QJM* 2007;100:317-34.
3. John BV, Jacob M, Abraham OC, Thomas S, Thankachan R, Shukla V. Aspergilloma in a hydatid cavity. *Trop Doct* 2007;37:112-4.
4. Vasquez JC, Montesinos E, Rojas L, Peralta J, Delarosa J, Leon JJ. Surgical management of *Aspergillus* colonization associated with lung hydatid disease. *Ann Thorac Cardiovasc Surg* 2008;14:116-8.
5. Ulaşan NG, Dural K, Yildirim E, Ozisik K, Sakinci U. An intracavitary aspergilloma after echinococcal cystectomy. *J Cardiovasc Surg (Torino)* 2003;44:289-90.
6. Aydemir B, Aydemir C, Okay T, Celik M, Dogusoy I. An aspergilloma in an echinococcal cyst cavity. *Thorac Cardiovasc Surg* 2006;54:353-5.