

An intrabronchial inflammatory myofibroblastic tumor treated with argon plasma and cryotherapy

Argon plasma koagülasyon ve kriyoterapi ile tedavi edilen intrabronşiyal inflamatuvar miyofibroblastik tümör

Sinem Nedime Sökücü,¹ Ahmet Levent Karasulu,¹ Levent Dalar,¹ Neslihan Fener,² Sedat Altın¹

Departments of ¹Chest Diseases and ²Pathology, Yedikule Chest Diseases and Thoracic Surgery Training and Research Hospital, Istanbul, Turkey

Inflammatory myofibroblastic lung tumor is a rare and non-malignant neoplasm which can either be asymptomatic or be characterized by variable clinical expressions. It is a benign lesion, most likely reactive in nature. Its basic morphological characteristic is spindle cell (myoblasts and fibroblasts) proliferation which vary in number and type of inflammatory cells. In this article, we present an 18-year-old female patient with an intratracheal inflammatory pseudotumor arising from the right tracheobronchial angle.

Key words: Cryotherapy; endobronchial ultrasound; inflammatory myofibroblastic tumor.

Inflammatory myofibroblastic tumor (IMT), also called inflammatory pseudotumor, is a rare benign tumor composed of spindle cells with a varied infiltrate of inflammatory cells and fibrous tissue.^[1] There have been many reported cases of IMT in every organ system; however, occurrences in the bronchus are rare. We report a rare case of IMT located in the entrance of the right main bronchus. A rigid bronchoscopy was used for diagnostic and treatment purposes, and the diagnosis was confirmed by the histopathology and computed tomography (CT).

CASE REPORT

An eighteen-year-old female presented with a one-year history of progressive dyspnea and cough. There were no other symptoms. Her medical and family history was unremarkable, and in her physical examination,

İnflamatuvar miyofibroblastik akciğer tümörü nadir görülür, malign olmayan, asemptomatik veya çeşitli klinik bulgularla seyreden bir tümördür. Muhtemelen reaktif doğaya sahip benign bir lezyondur. Temel morfolojik özelliği değişken sayıda ve tipte inflamatuvar hücrelerle birlikte işi hücre (miyoblastlar ve fibroblastlar) proliferasyonudur. Bu yazıda, sağ trakeobronşiyal açıdan kaynaklanan inflamatuvar psödötümör saptanan 18 yaşında bir kadın hasta sunuldu.

Anahtar sözcükler: Kriyoterapi; endobronşiyal ultrason; inflamatuvar miyofibroblastik tümör.

her vital signs were normal. On auscultation, her breathing sounds were diminished on the right side, and rare bibasilar rales were detected. Her other physical examination findings revealed no abnormalities.

No pathological finding was detected in the biochemical parameters except for a white blood cell (WBC) count of 17,000/ μ L. The arterial blood gas analysis was normal, but in her respiratory function test, the functional vital capacity (FVC) was 1.72L (49%), the functional expiratory volume at 1 second (FEV1) was 1.35 (44%), and the FEV1/FVC was 78.5%. She had been treated with antibiotics (second-line cephalosporins) previously, and the sputum analysis for acid-fast bacteria was negative. A chest X-ray revealed non-homogenous infiltration in the right paracardiac location and volume loss in the right lung. Thoracic CT revealed a 1.5 cm mass or foreign body with smooth



Available online at
www.tgkdc.dergisi.org
doi: 10.5606/tgkdc.dergisi.2012.129
QR (Quick Response) Code

Received: December 9, 2009 Accepted: March 8, 2010

Correspondence: Sinem Nedime Sökücü, M.D. Yedikule Göğüs Hastalıkları ve Göğüs Cerrahisi Eğitim ve Araştırma Hastanesi, Göğüs Hastalıkları Kliniği, 34020 Zeytinburnu, Istanbul, Turkey.

Tel: +90 212 - 664 17 00 / 1330 e-mail: sinemtimur@yahoo.com

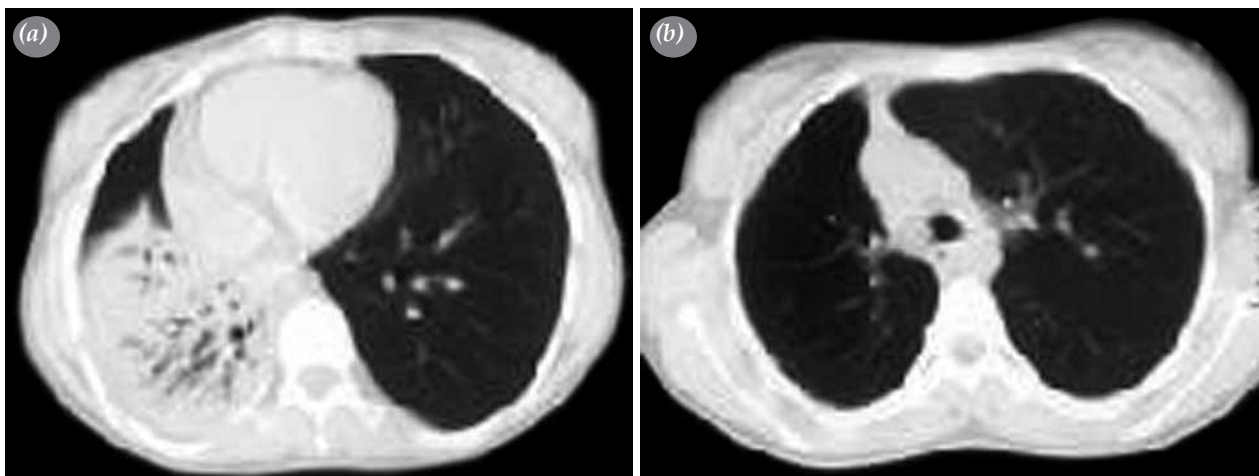


Figure 1. Contrast-enhanced axial computed tomography image displayed in the soft-tissue window setting (a) demonstrates heterogenous consolidation in the right lower zone and (b) an endobronchial mass lesion in the right main bronchus entrance.

margins located in the right main bronchus entrance (Figure 1a). Volume loss was detected in the right hemithorax, and parenchymal consolidation containing air bronchograms was detected in the right lower lobe with pleural effusion (Figure 1b).

A fiberoptic bronchoscopy under local anesthesia showed an intraluminal polypoid, reddish mass arising from the right main bronchus which was causing near total obstruction (Figure 2a). A rigid bronchoscopy was done since the patient was thought to have an increased risk of bleeding. The endobronchial 1.5 cm mass was covered by shiny, gray mucosa. The mass was cored out after coagulation with argon plasma under general anesthesia. After hemostasis with the argon plasma coagulation, cryotherapy was applied to a large area (Figure 2b).

The spindle tumor cells seen in hematoxylin-eosin (H-E) staining were strongly positive for vimentin and smooth muscle actin, but they were negative for desmin, pancytokeratin, thyroid transcription factor 1 (TTF-1), chromogranin, the cell adhesion molecule CD 56, and synaptophysin in immunohistochemical stainings. The S-100 protein was not evaluated for technical reasons (Figure 3). In the end, the patient was diagnosed as having IMT.

In our patient, following resection by a rigid bronchoscope, immediate symptomatic improvement was noted in the post-anesthesia recovery room. In the respiratory function tests, the FVC improved from 1.72 (49%) to 2.71 (66%), and the FEV₁ improved from 1.35 (44%) to 2.44 (68%). A control bronchoscopy was done with an endobronchial ultrasound (EBUS) radial probe

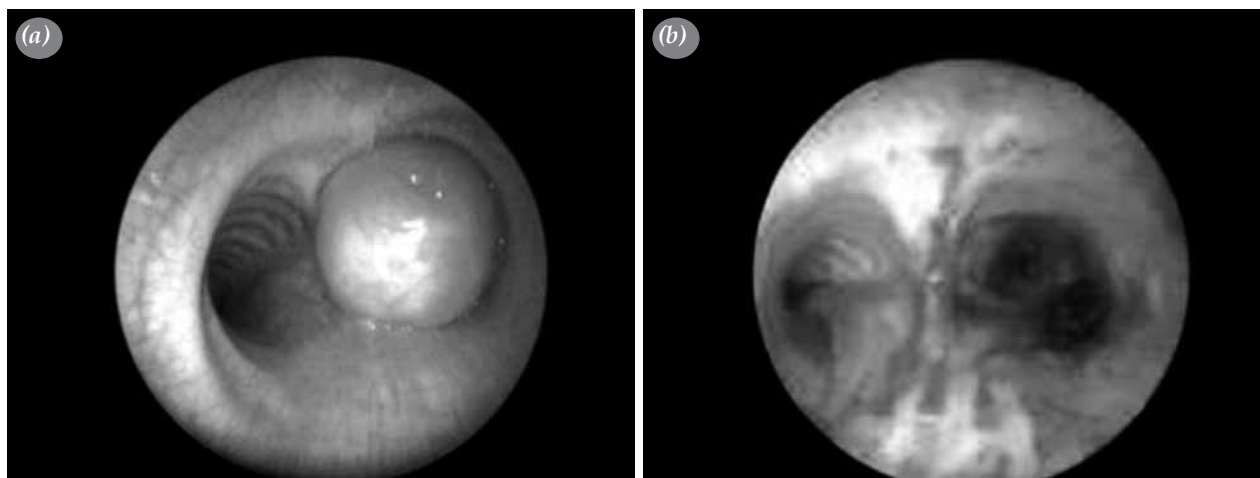


Figure 2. Bronchoscopic images (a) reveal near 100% reduction of the airway diameter of the right main bronchus, and (b) the airway opened after rigid bronchoscopy.




Figure 3. In immunohistochemical stainings, the spindle tumor cells were strongly positive for smooth muscle actin (original x 100).

one week after the procedure, and all the wall elements were observed to be intact with no invasion. There was no recurrence, and there was a full regression of the findings that had been detected in the right hemithorax by CT one month after intervention. Surgical resection was spared in this case. The patient was then followed up for three months without any complaints.

DISCUSSION

Inflammatory myofibroblastic tumor, a rare disease with an unknown etiology, is a subgroup of the broad category of inflammatory pseudotumors. It is composed of a varied mixture of collagen, inflammatory cells, and, more than likely, cytologically bland spindle cells showing myofibroblastic differentiation.^[1] Patients of all ages (range, 13 months to 77 years) can develop IMTs, but they predominantly occur in younger patients (<40 years^[1]) and occur with equal incidence in men and women. The most frequently reported site of IMTs is lung, but they may occur, although less frequently, in the liver, spleen, stomach, orbit, and urinary bladder.^[2] The incidence of this disease is unknown; however, in one study, IMT accounted for 0.7% of lung masses in a series of 1.075 patients.^[3] About 40% to 70% of patients are symptomatic at presentation with cough, fever, chest pain, dyspnea, or hemoptysis. Laboratory tests yield normal results, but sometimes elevated erythrocyte sedimentation rates (ESR) and WBC counts can be reported.

Inflammatory myofibroblastic tumors usually present as peripheral mass lesions. In a review of 61 patients with chest radiographs, 52 (87%) had solitary peripheral lesions. In six of them, secondary endoluminal airway

involvement by a parenchymal lesion was present. Four patients had central lesions, two of which manifested as mediastinal masses, one as endobronchial, and one as endotracheal.^[4]

Radiologically, it is difficult to distinguish IMT from a malignant tumor. As a result, a definitive diagnosis is made based on the histopathological findings from either a resected tumor or a needle biopsy. Because of the varied cellular composition of these masses, large biopsies are needed for diagnosis. Inflammatory pseudotumors can demonstrate aggressive behavior. Surgical excision is generally considered to be the best treatment choice, but they may recur if not completely excised. Pseudotumors extending beyond a single organ at the initial presentation have a high chance of recurrence, despite adequate resection, for this reason, they need to be followed up closely.^[5] On the other hand, treatment of IMT cases with corticosteroids or spontaneous regression of IMT in the lungs and the mediastinum has been reported.^[6]

Two distinct types of IMT were identified in a series of 23 patients.^[7] The first type is the noninvasive inflammatory pseudotumor, which is more likely to occur in an asymptomatic patient and is characterized by a small mass. The second type is the invasive inflammatory pseudotumor of the lung, which occurs in younger patients who usually have systemic symptoms of fever, fatigue, or weight loss and needs wide surgical resection. The overall prognosis of the invasive inflammatory pseudotumor is excellent with a 91.3% of five-year survival, and recurrence rates after resection are low at 4% and occur at sites of incomplete resection.^[8] In our case, considering the endoscopic removal of the lesion as well as the absence of histological documentation of complete resection with no microscopic visual tumor (R0 resection), close follow-up of the patient by EBUS and high-resolution CT is needed.

Declaration of conflicting interests

The authors declared no conflicts of interest with respect to the authorship and/or publication of this article.

Funding

The authors received no financial support for the research and/or authorship of this article.

REFERENCES

1. Yousem SA, Tazelaar HD, Manabe T, et al. Inflammatory myofibroblastic tumor. In: Travis WD, Brambilla E, Muller-Hermelink HK, Harris CC, editors. World health organisation classification of tumours. Pathology and genetics of tumours of the lung, pleura, thymus and heart. Lyon: IARC Press; 2004. p. 105-6.

2. Narla LD, Newman B, Spottswood SS, Narla S, Kolli R. Inflammatory pseudotumor. *Radiographics* 2003;23:719-29.
3. Janik JS, Janik JP, Lovell MA, Hendrickson RJ, Bensard DD, Greffe BS. Recurrent inflammatory pseudotumors in children. *J Pediatr Surg* 2003;38:1491-5.
4. Agrons GA, Rosado-de-Christenson ML, Kirejczyk WM, Conran RM, Stocker JT. Pulmonary inflammatory pseudotumor: radiologic features. *Radiology* 1998;206:511-8.
5. Bando T, Fujimura M, Noda Y, Hirose J, Ohta G, Matsuda T. Pulmonary plasma cell granuloma improves with corticosteroid therapy. *Chest* 1994;105:1574-5.
6. Golbert ZV, Pletnev SD. On pulmonary "pseudotumours". *Neoplasma* 1967;14:189-98.
7. Trastek VF, Miller DL, Pairolero PC, Cerfolio RJ, Allen MS, Nascimento AG, et al. Inflammatory pseudotumors of the lung. *Ann Thorac Surg* 1999;67:933-6.
8. Hussain SF, Salahuddin N, Khan A, Memon SS, Fatimi SH, Ahmed R. The insidious onset of dyspnea and right lung collapse in a 35-year-old man. *Chest* 2005;127:1844-7.