

A simple method for eliminating strain on aortocoronary saphenous vein bypass grafts: The suspension of the right atrial appendage and plication of the right atrium

Aortokoroner safen ven baypas greft üzerindeki gerilimi ortadan kaldırmak için kullanılan basit bir yöntem: Sağ atrial apendix süspansiyonu ve sağ atriyum plikasyonu

Denyan Mansuroğlu,¹ İsmail Cihan Özbek,¹ Kenan Sever,¹ Nuri Kurtoğlu²

Departments of ¹Cardiovascular Surgery, ²Cardiology, Private Gaziosmanpaşa Hospital, İstanbul, Turkey

Strain on saphenous vein grafts may compromise the blood flow in the bypass graft. This may result in early postoperative ischemic complications as well as a decrease in early and late graft patency rates. In this article, we present two simple techniques to eliminate the excessive strain on the saphenous grafts when the patient is weaned off the cardiopulmonary bypass.

Key words: Graft strain; ischemia; saphenous vein graft.

Despite their lower patency rates compared with the left internal mammary artery, saphenous vein grafts are one of the most commonly used conduits in coronary artery bypass grafting (CABG) surgery. Technically, saphenous bypass grafts are usually anastomosed proximally to the aorta or, on rare occasions, onto another bypass graft. Fine adjustment of saphenous vein graft length is vital for a satisfactory surgical result. If the length is longer or shorter than needed, then the saphenous vein graft may be kinked or strained, both of which may compromise the blood flow and the graft patency.

Several techniques have been previously reported which can overcome the excessive length of the graft, which ultimately leads to kinking.^[1,2] Studies have shown that abnormal tension on saphenous grafts is not uncommon, especially on those for the right coronary system,^[3,4] and this may be associated with an increased risk of graft obstruction. Herein we describe two simple techniques that can be used in cases where excessive

Safen ven baypas greftleri üzerindeki gerilim, greftin kan akımını tehlikeye sokabilir. Bu da, erken ve geç dönem greft açıklık oranlarında düşüş ile ameliyat sonrası iskemik komplikasyonlara neden olabilir. Bu yazıda, kardiyopulmoner baypastan çıktıktan sonra hastada oluşabilen safen ven grefti üzerindeki aşırı gerilimi ortadan kaldırmak için kullandığımız basit iki teknik sunuldu.

Anahtar sözcükler: Greft gerilimi; iskemi; safen ven grefti.

strain is visualized on saphenous vein grafts to the right coronary system.

TECHNIQUES

Tension on the saphenous grafts to the right coronary artery usually develops over the acute margined region where the right atrium and the right ventricle come together. This finding becomes more prominent as the cardiopulmonary bypass is weaned, and the cardiac volume is increased. After checking the length and configuration of the vein graft, if the surgeon visualizes a strain, two techniques can be used to eliminate it.

The lower part of the right atrium which is in contact with the saphenous graft can be plicated for 2.5-3 cm with 5-0 pledgeted prolene sutures. This will result in an extra 2 cm of length in the bypass graft (Figures 1, 2, and 3).



Available online at
www.tgkdc.dergisi.org
doi: 10.5606/tgkdc.dergisi.2012.134
QR (Quick Response) Code

Received: November 21, 2011 *Accepted:* January 9, 2012

Correspondence: Denyan Mansuroğlu, M.D. Özel Gaziosmanpaşa Hastanesi, Kalp ve Damar Cerrahisi Kliniği, 34245 Gaziosmanpaşa, İstanbul, Turkey.

Tel: +90 212 - 615 38 38 e-mail: drdenyan@yahoo.com




Figure 1. The strain on the saphenous vein graft overlying the acute margin area.

The second technique, which may be applied in combination with the first one or alone, is to ligate the right atrial appendage and then sew it upwards onto the adventitia of the aorta with a 5-0 prolene suture (Figure 4).

COMMENT

Adjustment to ensure the accurate length of saphenous vein grafts anastomosed proximally to the aorta is a critical step in CABG surgery. A graft longer than necessary is prone to kinking, which may ultimately compromise the blood flow to the ischemic area. On the other hand, if the graft is too short, then the tension over the graft will also endanger its patency. Patients with volume overload and heart failure are especially prone to this risk, which usually becomes apparent as the cardiopulmonary bypass is terminated

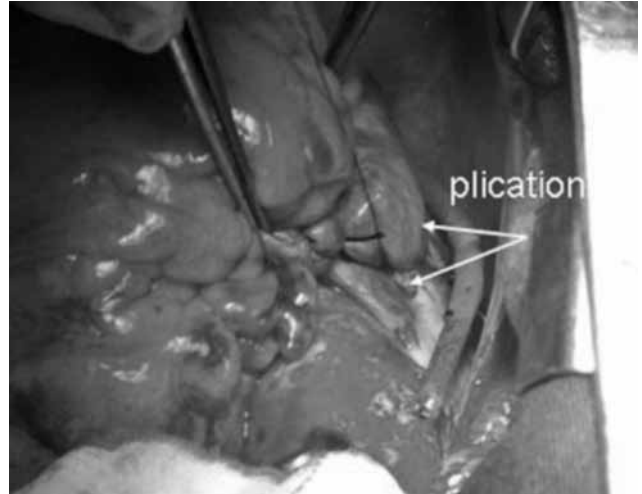


Figure 2. Simple plication of the right atrial free wall.

and the volume of the right heart is increased. Another predisposing factor for this situation is to perform the proximal saphenous anastomosis before the ideal filling pressure is achieved, for example while the cross-clamp is still in place. A simple way to minimize this risk is to pre-measure the required length of the graft with a silk suture and then mark the point of anastomosis on the aorta just before the cardiopulmonary bypass is established.

Despite all of these measures, the length of saphenous grafts may fall short. In this situation, if there is another graft to the left coronary system, then the proximal anastomosis can be transferred to this graft. However, if there is only one saphenous vein graft on either system of the heart, then the only remaining option is to add a short segment of saphenous graft to the original graft. This option unfortunately inherits the risk of a mismatch




Figure 3. The anterosuperior surgical positioning of the right atrial appendage onto the aortic root following ligation of the appendage.

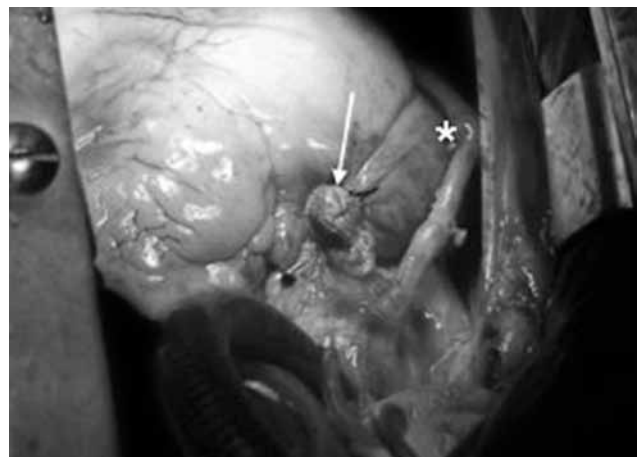


Figure 4. The location of the saphenous vein graft in the normal configuration (asterix), following positioning and ligation of the right atrial appendage (arrow).

between the graft diameters and may require one more anastomosis.

The techniques we have described here are simple, practical, and efficient approaches to consider when the saphenous graft is too short in length and strained.

Declaration of conflicting interests

The authors declared no conflicts of interest with respect to the authorship and/or publication of this article.

Funding

The authors received no financial support for the research and/or authorship of this article.

REFERENCES

1. Durrani A, Sim EK, Grignani RT. Accurate length adjustment of aortocoronary saphenous vein bypass grafts. *Ann Thorac Surg* 1998;66:966-7.
2. Erdinc M, Ocal A, Atalay OS, Ozturk C, Sezer H. Adjustment of faulty graft length in aortocoronary bypass. *Ann Thorac Surg* 1999;67:1536-7.
3. Spray TL, Roberts WC. Tension on coronary bypass conduits. A neglected cause of real or potential obstruction of saphenous vein grafts. *J Thorac Cardiovasc Surg* 1976;72:282-7.
4. Bonchek LI, Olinger GN. Technical considerations in saphenous vein bypass grafts to the right coronary artery. *Ann Thorac Surg* 1978;25:254-6.