

## Preliminary results of direct closure of an atrioventricular septal defect: revisiting the original technique

*Atriyoventriküler septal defektin doğrudan kapatılmasının ilk sonuçları: Orjinal tekniğe dönüş*

Ece Salihoğlu,<sup>1</sup> Süleyman Özkan,<sup>1</sup> Salih Özçobanoğlu,<sup>2</sup> Alpay Çeliker<sup>3</sup>

<sup>1</sup>Department of Cardiovascular Surgery, Acıbadem University School of Medicine, İstanbul, Turkey;

<sup>2</sup>Department of Cardiovascular Surgery, Acıbadem International Hospital, İstanbul, Turkey;

<sup>3</sup>Department of Pediatrics, Acıbadem University School of Medicine, İstanbul, Turkey

**Background:** This study aims to assess the preliminary results of direct closure of atrioventricular septal defect (AVSD).

**Methods:** Thirteen patients (complete type n=7, partial type n=6) who underwent AVSDs correction with direct closure technique in our department between September 2009 and June 2011 were included. Two patients with concomitant pulmonary stenosis were managed in a single session. For direct suture closure of ventricular septal defect (VSD), multiple interrupted Teflon pledgets sutures were placed on the right side of the interventricular septal crest and then they were passed through the bridging leaflets of the common valve. For direct closure of primum atrial septal defect (ASD) in patients with complete type VSD closure sutures were used by passing through the remnant of interatrial septum and tied off.

**Results:** The median age of the patients was 13 months. The median age (7.5 months) and weight (4.3 kg) of the patients with complete type was lower. The mean VSD size was 30.4±10 mm/m<sup>2</sup>. The mean cardiopulmonary bypass and ischemic cross clamp times were 51.3±11.2 min and 34.7±10.9 min, respectively. There was no in-hospital mortality. All patients were discharged with sinus rhythm and less than (2+) atrioventricular valve regurgitation. All the patients were followed. The mean follow-up was 12.1±4.1 months. Repeated echocardiograms did not revealed any progressive atrioventricular valve dysfunction or left ventricular outflow tract gradient.

**Conclusion:** Direct closure technique for repair of atrioventricular septal defect is rapid and simple surgery for the management of this complex pathology. This easily reproducible technique could also encourage and facilitate earlier repair of this pathology, preventing potential technical challenges.

**Key words:** Atrioventricular septal defect; congenital heart defect; surgical technique.

**Amaç:** Bu çalışmada atriyoventriküler septal defektin (AVSD) doğrudan kapatılmasının ilk sonuçları değerlendirildi.

**Çalışma planı:** Eylül 2009 - Haziran 2011 tarihleri arasında kliniğimizde AVSD'ler nedeni ile doğrudan kapama tekniği ile ameliyat edilen 13 hasta (komplet tip n=7, parsiyel tip n=6) çalışmaya dahil edildi. İki hastada ek patoloji olarak var olan pulmoner stenoz tek seansta düzeltildi. Ventriküler septal defekt (VSD) komponentinin kapatılması interventriküler septumun sağ tarafına tek tek yerleştirilen Teflon destekli dikişlerin ana kapakçığın "bridging" yaprakçığından geçirilmesi ile gerçekleştirildi. Komplet tip hastalarda primum atriyal septal defektin (ASD) kapatılması, bu VSD dikişlerinin kapaktan geçirildikten sonra atriyumlar arası septal ayrımının kenarından geçirilip ayrı ayrı düğümlenmesi ile sağlandı.

**Bulgular:** Hastaların medyan yaşı 13 ay idi. Komplet tipli hastaların medyan yaşı (7.5 ay) ve ağırlıkları (4.3 kg) daha düşüktü. Ortalama VSD büyüklüğü 30.42± 10 mm/m<sup>2</sup> idi. Hastaların ortalama kardiyopulmoner baypas ve iskemik kros klemp zamanları sırasıyla 51.3±11.2 dk ve 34.7±10.9 dk olarak hesaplandı. Hastane içi mortalite olmadı. Hastaların tamamı sinüs ritminde ve atriyoventriküler kapak yetersizlikleri en fazla (2+) olarak taburcu edildi. Hastaların tamamı takip edildi. Takip süresi ortalama 12.1±4.1 ay idi. Tekrarlanan ekokardiyografi incelemelerinde hiçbir hastada ilerleyen atriyoventriküler kapak disfonksiyonu veya sol ventrikül çıkış yolu darlığı tespit edilmedi.

**Sonuç:** Atriyoventriküler septal defektin doğrudan kapatma tekniği ile kapatılması tamiri bu kompleks patolojinin tedavisinde hızlı ve basit bir cerrahidir. Kolaylıkla uygulanabilen bu cerrahi aynı zamanda teknik zorluklardan kaynaklanan hataların önüne geçerek, bu patolojinin daha da erken tamir edilmesini özendirilebilir ve bunu kolaylaştırabilir.

**Anahtar sözcükler:** Atriyoventriküler septal defekt; doğuştan kalp hastalığı; cerrahi teknik.



Available online at  
www.tgkdc.dergisi.org  
doi: 10.5606/tgkdc.dergisi.2012.141  
QR (Quick Response) Code

Received: March 29, 2012 Accepted: May 2, 2012

Correspondence: Ece Salihoğlu, M.D. Acıbadem Üniversitesi Tıp Fakültesi, Kalp ve Damar Cerrahisi Anabilim Dalı, 34848 Maltepe, İstanbul, Turkey.

Tel: +90 212 - 468 43 53 e-mail: esalihoglu@asg.com.tr

Atrioventricular septal defect (AVSD) is a complex pathology which can manifest in a large spectrum of anatomy depending on the varied development of the endocardial cushion. This results in AVSD ranging from partial to complete. Many surgical approaches have been developed according to anatomic type. Since the benefit of early correction for long-term prognosis has been demonstrated, surgery in younger populations has been evaluated for simplified techniques.<sup>[1]</sup>

Direct closure is the initial technique described in 1955 for the repair of AVSD, but since then, many modifications have been made in the search of excellence. The classic single-patch technique demands division and reimplantation of leaflets; therefore, it was replaced with the double-patch method to avoid leaflet division. This was challenging, especially in young infants with a limited valve area. The new technique also has encountered difficulty in calculating the height of the ventricular septal defect (VSD) patch, and problems related to the patch dimension of the left atrioventricular valve function are uncertain. Recently, the trend has been moving toward simplification of surgical techniques through the elimination of patches, but controversy still exists concerning the optimal surgical option.<sup>[1-3]</sup>

Therefore, we decided to revisit the various methods and apply the direct closure technique for the repair of AVSD. The purpose of this study was to evaluate the preliminary results of our experience with this technique with regard to surgical outcome and early follow-up results.

## PATIENTS AND METHODS

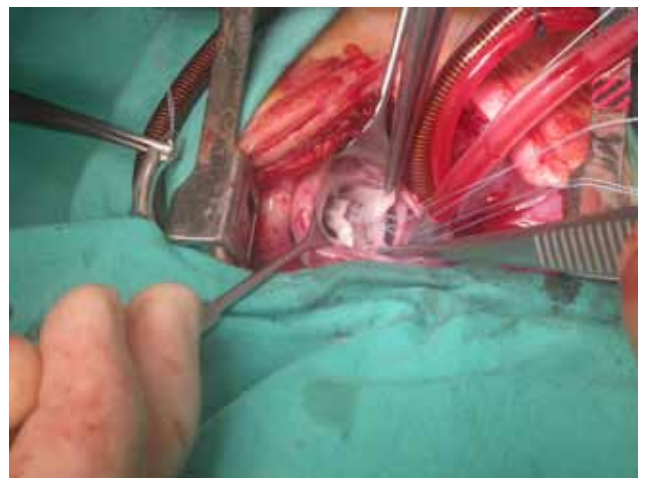Between September 2009 and June 2011, 20 patients underwent correction for AVSD. Our surgical evaluation of this minimalist technique was gradual, and the first six patients were operated on using patch materials. Two patients with complete AVSD (CAVSD) were repaired with the Australian technique, and five patients with partial (incomplete) AVSD (PAVSD) were repaired with the bovine pericardial patch closure of the primum atrial septal defect (ASD). Since June 2010 when we began this program, 13 consecutive AVSD patients were repaired using this method. During this period, only one patient with combined systemic venous return anomaly was excluded from this study. Of these 13 patients, seven had CAVSD, and six had PAVSD. Data was obtained from the referring pediatric cardiologists, and Doppler echocardiography was used to ascertain the severity of AV valve regurgitation and VSD measurements. Atrioventricular valve regurgitation (AVVR) was graded as none, trivial, mild (1+), moderate (2+), and severe (3+).

The VSD size was measured from the crest to the septum to the common AV valve during end diastole. We also used Rastelli's classification for the patients with complete AVSD.

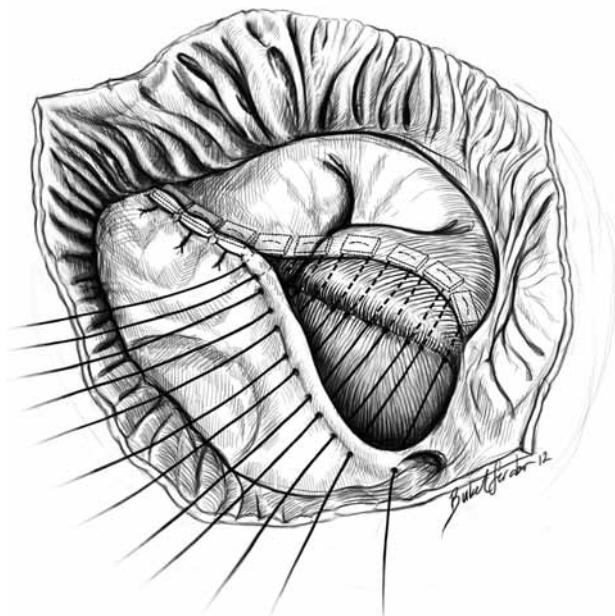
## Surgical technique

All operations were performed using a moderate hypothermic cardiopulmonary bypass (CPB) and antegrade cold crystalloid cardioplegia. For direct suture closure of VSD, multiple interrupted sutures of 4-0 Ti-cron with Teflon pledgets were placed on the right side of the interventricular septal crest and were then passed through the bridging leaflets of the common valve (Figure 1). Although the degree of cleft closure was dependent on the anatomy of the valve, it was closed to have total coaptation of leaflets in all patients. This was done in the usual fashion with interrupted 6-0 Prolene sutures (Ethicon, Somerville New Jersey). Direct closure of the primum ASD in CAVSD patients was performed using Ti-Cron VSD closure sutures which were passed through the remnant of the interatrial septum (Figure 2) and then tied off. Therefore, the atrial septum and AV valve leaflets were pulled down on the VSD crest and connected in the same plane.

Two layers of running 5-0 Prolene sutures were used for closure of the ASD for repairs in the patients with PAVSD. The bites were passed through the septal part of the newly created tricuspid valve and then from the crest of the atrial defect. The coronary sinus drainage was left on the right atrium in its natural position. This suture line was started at the inferior part of the defect where the inferior part of the crest of the ostium primum joins the posterior leaflet. The sutures were superficial on the inferior AV valve leaflet and ran obliquely until the level



**Figure 1.** Operative view of teflon pledgeted ventricular septal defect sutures placed on the septal crest and passing from the bridging leaflet.



**Figure 2.** Atrial septal defect closure by ventricular septal defect sutures passed the rough the superior rim of the ostium primum.

of the ventricular septum was reached. Special attention was given to prevent AV blockage in this area.

In two patients with associated pulmonary stenosis, infundibular band resection and transannular pericardial patch enlargement were performed concomitantly. The rest of the operation was completed in the usual manner.

All patients were followed up clinically, and repeat echocardiography was done before discharge, at the first month and after six months postoperatively, at the end of the first year, and then every year afterwards.

Statistical analysis was performed with the StatView software (SAS Institute, Inc., Cary, North Carolina, USA). Data was expressed as the median and ranges or

as the mean ± standard deviation. Student’s t test was performed when necessary.

**RESULTS**

The median age at surgery was 13 months, and smaller ages and weight were found in the CAVSD group. Trisomy 21 was a part of the pathology of most of the CAVSD patients. Five of those patients were classified as Rastelli type A, one patient was type B, and one was type C. The size of the left atrium was measured in all patients pre- and postoperatively and was significantly decreased after repair. As expected, the mean pulmonary arterial pressure was higher in patients with CAVSD, and it dropped significantly to 26.8±6.0 mmHg immediately after the operation. Hemodynamically, important valve dysfunction was more common in patients with PAVSD (50%). The preoperative characteristics and VSD properties are detailed in Table 1.

Despite technical differences due to the presence of VSD, the mean cardiopulmonary and cross-clamp operative times were similar in the PAVSD and CAVSD patients (p>0.05). In two patients with additional pulmonary stenosis, infundibular resection and transannular patch enlargement were performed concomitantly. Although they had additional surgical procedures, their operational times were close to the times of the other patients. The intraoperative data is summarized in Table 2.

There was no in-hospital death, but one late mortality occurred in a patient with Trisomy 21 two months later due to food aspiration. The mean ventilatory time was longer in the CAVSD group and for two patients with preoperative congestive heart failure and recurrent pulmonary infection who needed mechanical ventilation support for three and five days, respectively (Table 3).

**Table 1. Preoperative patient characteristics**

	PAVSD (n=6)			CAVSD (n=7)			All patients (n=13)		
	n	Range	Mean±SD	n	Range	Mean±SD	n	Range	Mean±SD
Median age (month)	18	8-168	–	7.5	3-72	–	13	3-168	–
Median weight (kg)	14.1	9.2-33.3	–	4.3	3.5-18	–	9	3.5-33.3	–
Trisomy 21 (n)	1	–	–	5	–	–	6	–	–
AVVR >2+ (n)	3	–	–	2	–	–	5	–	–
Mean VSD size (mm)	–	–	–	–	–	9.3±2.4	–	–	–
Mean indexed VSD (mm/m <sup>2</sup> )	–	–	–	–	–	30.4±1	–	–	–
Mean systolic PAP (mmHg)	–	–	32±11.5	–	–	67.5±6.1	–	–	51.4±20.4
LVOTO (n)	0	–	–	0	–	–	0	–	–
Associated pathologies:									
pulmonary stenosis (n)	1	–	–	1	–	–	2	–	–

PAVSD: Partial atrioventricular septal defect; CAVSD: Complete atrioventricular septal defect; SD: Standard deviation; AVVR: Atrioventricular valve regurgitation; VSD: Ventricular septal defect; PAP: Pulmonary artery pressure; LVOTO: Left ventricular outflow tract obstruction.

**Table 2. Operative data**

	PAVSD (n=6)		CAVSD (n=7)		All patients (n=13)	
	n	Mean±SD	n	Mean±SD	n	Mean±SD
Cardiopulmonary bypass time (min)		54.8±11.8		48.3±10.6		51.3±11.2
Aortic cross clamp time (min)		38.3±12.1		31.6±9.6		34.7±10.9
Associated procedures	1		1		2	

PAVSD: Partial atrioventricular septal defect; CAVSD: Complete atrioventricular septal defect; SD: Standard deviation.

All patients were in sinus rhythm, and none needed antiarrhythmic medication postoperatively. Postoperative echocardiography was done before discharge for all patients, and none had more than mild AV valve regurgitation ( $\leq +2$ ).

The mean follow-up time for all patients was 12.1±4.1 months. Repeat echocardiographies did not reveal any progressive AV valve dysfunction or new appearance, nor did they show progression of the left ventricular outflow tract (LVOT) gradient. As a consequence, none of the patients were reoperated on during this period.

## DISCUSSION

Wilcox first reported the simplified technique which eliminated the VSD patch in 1997. Since then, this technique has been widely preferred by many clinics, and excellent short- and mid-term results have been reported.<sup>[1-3]</sup> The pediatric cardiac surgery department was opened in our hospital at 2009, and the simplified one-patch technique has been our preference from the beginning.

Because some authors have reported good experiences with direct closure of AVSDs, we decided to evaluate our technique and move to a more simplified method by gradually eliminating the atrial patch component.<sup>[4,5]</sup> In a way, we traveled "back to the future" by revisiting and showing respect to an originally descriptive technique. Our clinic is one of the referral centers for neighboring countries with patients in need of congenital cardiac surgery. Therefore, we accept many late-diagnosed cases, which makes our patient population older than usual. Consequently, these older patients have tissues that are more damaged, but they also have fibrotic and stronger cardiac tissues, making them ideal candidates for the no-patch technique. This

was the main factor which encouraged us in our switch to the simplified technique. At the beginning of our experience, we used direct closure for PAVSD and then applied direct closure featuring the no-patch technique to patients with CAVSD and to younger and lower-weight patients.

Besides simplifying the surgery, it was demonstrated that eliminating the VSD patch has the advantage of better coaptation of the left AV valve by lowering the implantation level of the valve to the crest of the interventricular septum.<sup>[2,3,6]</sup> We were able to practice this method with success even in our older patient group who had a large VSD and thickened valves, and none of our patients had more than mild residual AV valve regurgitation after repair. In addition, this method is easier to perform on low-weight patients due to their flexible tissues, as we experienced in four patients weighting less than five kilograms. Prêtre et al.<sup>[7]</sup> demonstrated that direct closure of primum type ASD is possible even with greater defect size. He also hypothesized that this method also prevented postoperative arrhythmia by decreasing the size of the dilated atrium. We showed that direct closure of the ostium primum defect is possible, even in a 14-year-old patient with a left atrial diameter of 34 mm and that direct closure significantly reduces atrial size in all patients. However, we were not able to demonstrate that this is the reason for the persistence of sinus rhythm postoperatively. Postoperative atrial arrhythmia has a multifactorial etiology, including the amount and place of suture lines, damage to the sinus node artery, and myocardial protection. Since all of our patients had sinus rhythm postoperatively and on follow-up,

**Table 3. Postoperative results**

	PAVSD (n=6)	CAVSD (n=7)	All patients (n=13)
	Mean±SD	Mean±SD	Mean±SD
Ventilatory support time (hour)	7.3±2.2	15.8±9.2*	11.2±7.5*
ICU stay time (day)	1.2±0.4	4±0.7*	2.5±1.6*

PAVSD: Partial atrioventricular septal defect; CAVSD: Complete atrioventricular septal defect; SD: Standard deviation;

\* Except for two patients with preoperative congestive heart failure and recurrent pulmonary infection.

we at least showed that this method doesn't aggravate postoperative rhythm disturbances.

It could also be hypothesized that direct closure of atrial and ventricular defects may cause excessive tension on suture lines, which could cause a subsequent increased risk of tearing. Two layers of suture lines are used for repair of PAVSD to prevent recurrence, whereas in CAVSD patients, there is only one suture line. In this technique, separated Teflon pledgetted sutures on the ventricular septum first pass from the leaflet tissue and then from the atrial septum by sandwiching the valve. They are then individually tied. Therefore, each pledgetted stitch equally absorbs the tension. We did not observe any dehiscence in the early postoperative and short-term follow-up period, which correlates with other authors' experiences.<sup>[4,5]</sup> Another finding which eliminates this excessive tension hypothesis is the absence of postoperative transient and permanent atrioventricular block related to myocardial edema as a result of tissue damage.

We did not find any statistically significant difference between the operative times in PAVSD and CAVSD patients. We suggest that this is due to the simplicity of the VSD closure since it eliminates patch sizing and implantation; hence, this extra time can be used for valve repair, a challenging step, especially for the future prognosis of the patient. This time advantage also provides a good opportunity for repair of combined pathologies, as we noticed in two patients with associated pulmonary stenosis. They underwent repair with concomitant infundibular band resection and transannular pericardial patch enlargement and had similar operative times as the other patients with isolated AVSD.

Another advantage of this technique is the short cardiopulmonary and cross-clamp time due to the simplicity of this method, an important factor for extubation and intensive care unit (ICU) stay time, especially in patients with pulmonary hypertension, congestive heart failure, and a history of recurrent pulmonary infection.<sup>[3,6,8,9]</sup> Our experience showed that we had shorter operative times and, subsequently, shorter ventilatory support and ICU stay periods than in previously published articles.<sup>[6,9]</sup> This indicates the technical success of this surgical technique since residual or acquired lesions in patients who are already pulmonary hypertensive would complicate their postoperative course.

Theoretically, there is an increased risk for LVOT obstruction in patients operated on with this simplified

technique because of pulling down the atrioventricular valve and excessively narrowing the already elongated LVOT. This concern has been discussed before by several authors as a potential problem if VSD patch is eliminated. Nevertheless, the long-term outcomes reported by other clinics have demonstrated that the incidence of postoperative LVOT obstruction is not higher than for other methods.<sup>[2,3,10]</sup> Kalfa et al.<sup>[11]</sup> demonstrated that low age at initial surgery is a significant risk factor for developing secondary subaortic stenosis. Due to the older age of our patients, we believe that this risk was lower in our particular patient group. Our follow-up period was short for evaluating future LVOT stenosis, but it has also been shown that in 30% of patients, stenosis appears in the postoperative first year.<sup>[10]</sup> We did not observe any newly developed obstruction or increase in gradient through the LVOT postoperatively.

Nevertheless, we believe that this direct closure technique featuring no patch is not applicable for the repair of all types of combined complex pathologies with AVSD, as we observed in a patient with partial AVSD and an unroofed coronary sinus with left persistent vena cava superior drainage. This patient needed to be repaired with a pericardial patch for the reorganization of the atrial septation and correction of systemic venous drainage. Therefore, this patient was not included in this study.

Our study had an important limitation in that it consisted of a small group of patients with a short follow-up period, but it must be considered that these are the preliminary results of a study in progress.

In conclusion, our experience indicates that direct closure featuring a no-patch technique for repair of AVSD is a simple and fast surgical procedure for a complex pathology, even in cases of younger, lower-weight patients. This easily reproducible technique could also prevent potential technical errors and facilitate surgical repair, thus encouraging earlier repair in infancy. The preliminary results were satisfactory and promising, but longer follow-up in a larger series is needed to confirm the safety and long-term benefits of this technique.

#### **Declaration of conflicting interests**

The authors declared no conflicts of interest with respect to the authorship and/or publication of this article.

#### **Funding**

The authors received no financial support for the research and/or authorship of this article.

## REFERENCES

1. Wilcox BR, Jones DR, Frantz EG, Brink LW, Henry GW, Mill MR, et al. Anatomically sound, simplified approach to repair of "complete" atrioventricular septal defect. *Ann Thorac Surg* 1997;64:487-93.
2. Nunn GR. Atrioventricular canal: modified single patch technique. *Semin Thorac Cardiovasc Surg Pediatr Card Surg Annu* 2007;1:28-31.
3. Backer CL, Stewart RD, Bailliard F, Kelle AM, Webb CL, Mavroudis C. Complete atrioventricular canal: comparison of modified single-patch technique with two-patch technique. *Ann Thorac Surg* 2007;84:2038-46.
4. Myers PO, Cikirikcioglu M, Aggoun Y, Murith N, Kalangos A. No-patch technique for complete atrioventricular canal repair. *Ann Thorac Surg* 2010;90:317-9.
5. Aramendi JI, Rodriguez MA, Luis T, Voces R. No patch technique for complete atrioventricular canal repair. *Interact Cardiovasc Thorac Surg* 2006;5:349-52.
6. Jeong IS, Lee CH, Lee C, Lim HG, Kim IS, Youn HC, et al. Surgical outcomes of the modified single-patch technique in complete atrioventricular septal defect. *Interact Cardiovasc Thorac Surg* 2009;8:435-7.
7. Prêtre R, Dave H, Kadner A, Bettex D, Turina MI. Direct closure of the septum primum in atrioventricular canal defects. *J Thorac Cardiovasc Surg* 2004;127:1678-81.
8. Krasemann T, Debus V, Rellensmann G, Rukosujew A, Scheld HH, Vogt J, et al. Regurgitation of the atrioventricular valves after corrective surgery for complete atrioventricular septal defects - comparison of different surgical techniques. *Thorac Cardiovasc Surg* 2007;55:229-32.
9. Atz AM, Hawkins JA, Lu M, Cohen MS, Colan SD, Jaggars J, et al. Surgical management of complete atrioventricular septal defect: associations with surgical technique, age, and trisomy 21. *J Thorac Cardiovasc Surg* 2011;141:1371-9.
10. Salihoğlu E, Özkan S. Complete atrioventricular septal defect: long term results and reoperations. *Türk Gogus Kalp Dama* 2011;19(Suppl. 1):33-8.
11. Kalfa D, Ghez O, Kreitmann B, Metras D. Secondary subaortic stenosis in heart defects without any initial subaortic obstruction: a multifactorial postoperative event. *Eur J Cardiothorac Surg* 2007;32:582-7.