

## A comparison of multidetector computed tomography direct venography with color Doppler ultrasound in the diagnosis of lower limb and inferior vena cava deep venous thrombosis

*Alt ekstremitte ve inferior vena cava derin venöz trombozunun tanısında multidedektör bilgisayarlı tomografi direkt venografi ile renkli Doppler ultrasonun kıyaslanması*

Hakan Barutca,<sup>1</sup> Fatih Kantarcı,<sup>2</sup> Sinan Şahin,<sup>1</sup> İsmail Mihmanlı<sup>2</sup>

<sup>1</sup>Department of Radiology, Dr. Siyami Ersek Thoracic and Cardiovascular Surgery Training and Research Hospital, İstanbul, Turkey;

<sup>2</sup>Department of Radiology, University of İstanbul, Cerrahpaşa Medical Faculty, İstanbul, Turkey

**Background:** This study aims to compare the diagnostic value of the multidetector computed tomography (MDCT) direct venography and color Doppler ultrasound (CDUS) in detection of lower limb deep venous thrombosis (DVT).

**Methods:** Color Doppler ultrasound and MDCT direct venography examinations were performed in 30 patients (21 males, 9 females; mean age 48 years; range 21 to 80 years) with clinical suspicion of DVT. The MDCT direct venography was performed within 24 hours, after the CDUS examination.

**Results:** Color Doppler ultrasound was diagnostic in all of the lower limb veins (240 venous segments), while non-diagnostic in 68 out of 150 venous segments at the pelvic region. Color Doppler ultrasound identified DVT in 13 segments, and MDCT direct venography identified DVT in 21 venous segments at the pelvic region. All of the lower limb DVT's were depicted both by CDUS and direct MDCT venography, except for one calf muscular vein thrombosis which was detected by CDUS. Multidetector computed tomography direct venography showed false positive thrombosis in five venous segments (4 femoral vein, 1 popliteal vein) and a pseudotrombosis appearance due to the flow phenomenon in one venous segment (common iliac vein). Partially recanalized low flow in chronic DVT patients could also be demonstrated on MDCT direct venography.

**Conclusion:** Multidetector computed tomography direct venography is more reliable than color Doppler US in diagnosis of DVT of the iliac veins and inferior vena cava. However, false positive thrombosis on MDCT direct venography can be seen distal to an occluded venous segment similar to the conventional venography.

**Key words:** Color Doppler ultrasound; deep venous thrombosis; multidetector computed tomography; thrombosis; venography.

**Amaç:** Bu çalışmada direkt multidedektör bilgisayarlı tomografi (MDBT) venografi ile renkli Doppler ultrasonografinin (RDUS) alt ekstremitte derin ven trombozunun (DVT) saptanmasındaki tanılal değerinin kıyaslanması amaçlandı.

**Çalışma planı:** Klinik DVT şüphesi bulunan 30 olguda (21 erkek, 9 kadın; ort. yaş 48 yıl; dağılım 21-80 yıl) RDUS ve MDBT direkt venografi incelemeleri yapıldı. Multidedektör bilgisayarlı tomografi direkt venografi, RDUS'nin ardından 24 saat içerisinde gerçekleştirildi.

**Bulgular:** Renkli Doppler ultrasonografi, tüm alt ekstremitte venlerinde tanı koydurabilirken (240 ven segmenti), pelvik bölgedeki 150 ven segmentinin 68'inde tanı koydurucu bulgu sağlayamadı. Pelvik bölgede RDUS 13 segmentte DVT yakalayabilirken, MDBT direkt venografi ile 21 ven segmentinde DVT tanısı kondu. Renkli Doppler ultrasonografi ile saptanabilen bir olgudaki baldır kas venindeki izole DVT haricinde, alt ekstremitte venlerinde her iki yöntem ile DVT gelişmiş venler saptanabildi. Multidedektör bilgisayarlı tomografi direkt venografi ile beş ven segmentinde (4 femoral ven, 1 popliteal ven) yalancı pozitif tromboz bulgusu ve bir ven segmentinde de (ana femoral ven) akım fenomenine bağlı yalancı trombüs görünümü elde edildi. Kronik DVT hastalarında kısmi rekanalize olmuş yavaş dolum da MDBT direkt venografi ile tespit edilebildi.

**Sonuç:** Multidedektör bilgisayarlı tomografi direkt venografi, iliyak ven ve inferior vena kavayı etkileyen DVT'lerde RDUS'ye göre daha güvenilirdir. Ancak, MDBT direkt venografide de, konvansiyonal venografiye benzer şekilde, tıkalı segment sonrasındaki venlerde yalancı pozitif sonuçlar görülebilir.

**Anahtar sözcükler:** Renkli Doppler ultrasonografi; derin ven trombozu; multidedektör bilgisayarlı tomografi; tromboz; venografi.



Available online at  
www.tgkdc.dergisi.org  
doi: 10.5606/tgkdc.dergisi.2012.154  
QR (Quick Response) Code

Received: April 11, 2012 Accepted: May 31, 2012

Correspondence: Hakan Barutca, M.D. Dr. Siyami Ersek Göğüs Kalp ve Damar Cerrahisi Eğitim ve Araştırma Hastanesi, Radyoloji Kliniği, 34668 Üsküdar, İstanbul, Turkey.

Tel: +90 216 - 542 44 44 e-mail: hbarutca@gmail.com

Deep venous thrombosis (DVT) constitutes a major health problem that results in significant morbidity and mortality owing to several associated complications, including acute or chronic pulmonary embolism with associated pulmonary hypertension and post-thrombotic syndrome. It is considered the third most common acute cardiovascular disease after ischemic heart disease and stroke and affects millions of people worldwide.<sup>[1,2]</sup> Most pulmonary emboli originate in the lower extremities and pelvis. Prophylaxis and treatment of DVT has been a major concern in clinical medicine; therefore, a prompt, accurate diagnosis is essential for appropriate treatment.<sup>[3]</sup>

Both DVT and pulmonary embolisms are often difficult to detect clinically. Various imaging modalities have been utilized for the diagnosis of DVT, including conventional venography, color Doppler ultrasonography (CDUS), magnetic resonance imaging (MRI), and computed tomography (CT).<sup>[4-7]</sup> Of these methods conventional venography has been accepted as the gold standard in the diagnosis of DVT. However, CDUS has become the initial diagnostic tool due to its high sensitivity for the detection of DVT, and some authors now believe that CDUS should be considered the gold standard. The major disadvantage of CDUS is the difficulty in examining the iliac veins and the inferior vena cava (IVC).<sup>[8,9]</sup> With more advanced technology and three-dimensional (3D) post-processing software, the venous system can also be accurately assessed by multidetector CT (MDCT). Studies incorporating combined lower extremity venous and pulmonary arterial system examinations by MDCT have been promising and have produced high accuracy rates.<sup>[10-13]</sup>

Multidetector CT venography can be performed by direct or indirect routes. Venipuncture of the dorsal veins of the foot and injection of contrast material is known as direct MDCT venography, whereas in indirect MDCT venography, the venous system is examined during the venous return of contrast material after arterial contrast enhancement. In this prospective study, we assessed the diagnostic capability of direct MDCT venography in the detection of lower extremity DVT.

## PATIENTS AND METHODS

### Patients

Thirty patients who were referred with suspected acute DVT of the lower extremities and who were examined by CDUS followed by direct MDCT venography within 24 hours were included in the study.

*Patient data:* Patients for whom direct MDCT venography could not be performed due to an inability

to cannulate foot veins, contrast agent allergy, renal insufficiency, or pregnancy or for whom both investigations could not be carried out within 24 hours were not included in the study. A total of 30 patients (21 males, 9 females; mean age 48 years; range 21 to 80 years) met the aforementioned criteria and were ultimately included in the study. Written informed consent was obtained from the participants. All of the patients presented with a sudden onset of leg edema with pain and/or clinical signs and symptoms of pulmonary embolism. Deep venous thrombosis was diagnosed by imaging in 22 patients. Of these 22, nine (40.9%) were acute, five (22.7%) were subacute, five (22.7%) had chronic thrombosis, and three (13.6%) had chronic thrombosis with an acute attack. Thirteen patients (43.3%) had DVT in their past medical history, and nine (30%) had a history of malignancy. Of these nine, three were on a chemotherapy regimen during their hospital administration. Five patients (17%) had a history of major surgical operation. Two patients (7%) had a history of stroke and immobilization after a long distance travel, and one patient (0.3%) was followed-up with the diagnosis of Behçet's disease.

### Imaging and data acquisition

Color Doppler US investigations were carried out using a high frequency CDUS unit (Sonoline Antares, Siemens Medical Solutions, Issaquah, Washington, USA). In the pelvic region, a 2-5 MHz electronic convex and 4-9 MHz electronic linear probes were used, but a 4-9 MHz electronic linear probe was preferred in the upper and lower legs. Results of the examination were considered positive if a thrombus was identified in the vessel lumen and negative if compression tests was negative and color filled the vein lumen. In the presence of a thickened or irregular wall, a narrowed or irregular lumen, or numerous adjacent venous collateral vessels, chronic DVT was diagnosed. The adequacy of the CDUS examination was judged for individual segments separately. The Doppler flow imaging examination was considered to be diagnostic if the individual segments were well visualized; otherwise it was considered to be nondiagnostic for that segment.

All direct MDCT venography examinations were performed with an MDCT unit (Siemens Sensation Cardiac16, Erlangen, Germany). A 20- or 22-gauge intravenous cannula was placed into the dorsal superficial veins of each foot. Forty milliliters of non-ionic iodinated contrast material were diluted with 160 ml saline. After the topogram, the diluted contrast material was automatically injected into both extremities via an automatic injector into the dorsal veins at a rate of 2.5 mL/sec per extremity (20 ml contrast and

80 ml saline, total 100 ml of diluted material for each extremity). After a 25-second delay, the patient was scanned from the ankle to the diaphragm so that the effective mAs value of the care dose was between 40 and 100 by using 16x1.5 collimation, 0.5 s rotation time, and 18 mm feed rotation space. According to the height of the patient, images up to the diaphragm were obtained in a single breath hold (24-30 s). In order to visualize the nonopacified veins in slow venous flow due to the variable hemodynamic states and venous pathologies and to prevent the appearance of false positive thrombosis, an additional craniocaudal scan was performed on all patients after a four-second delay following the first scan.

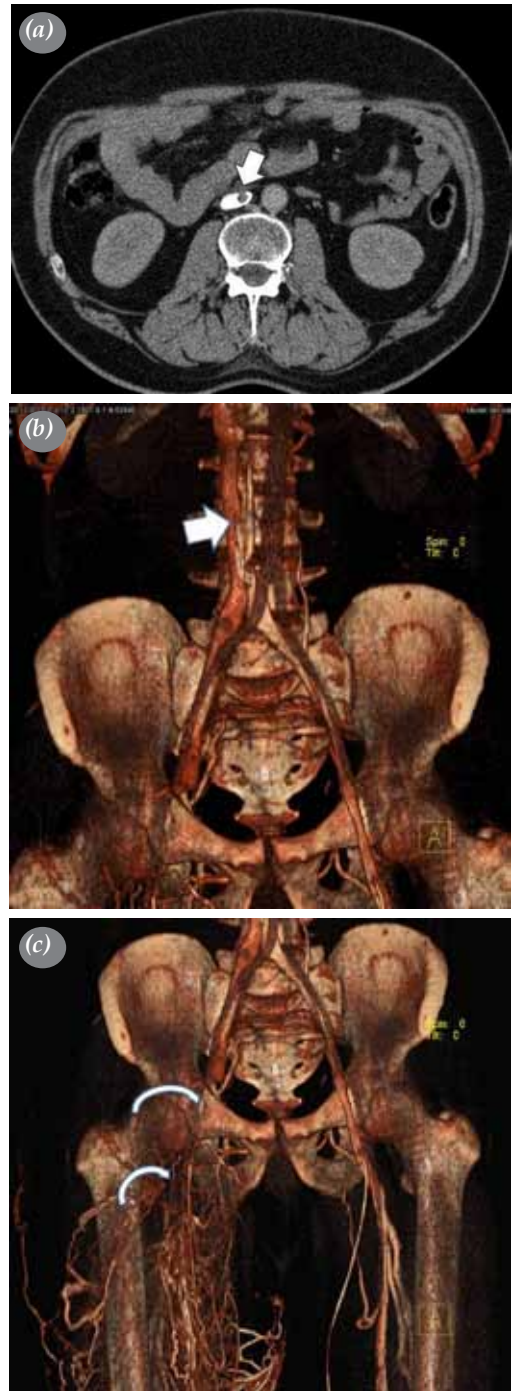
### Image interpretation

The raw MDCT image data was reconstructed with 1 mm cross-section intervals. For interpretation, axial cross-sectional, multiplanar reformatted (MPR), and 3D volume rendering reconstruction images were used. A consensus of two radiologists was obtained while interpreting the direct MDCT venography images, and the radiologists who interpreted the images were blinded both to the clinical and CDUS findings. A normal direct MDCT venography examination was defined as total luminal filling of the vessel lumen with diluted contrast material. Total or partial intravascular filling defects were considered as DVT on direct MDCT venography. Beam hardening artifacts due to adjacent arterial vessel wall calcifications, luminal filling defects due to artifacts of orthopedic implants, flow artifacts due to laminar flow within the veins, and filling defects due to contrast pooling were regarded as false thrombosis.

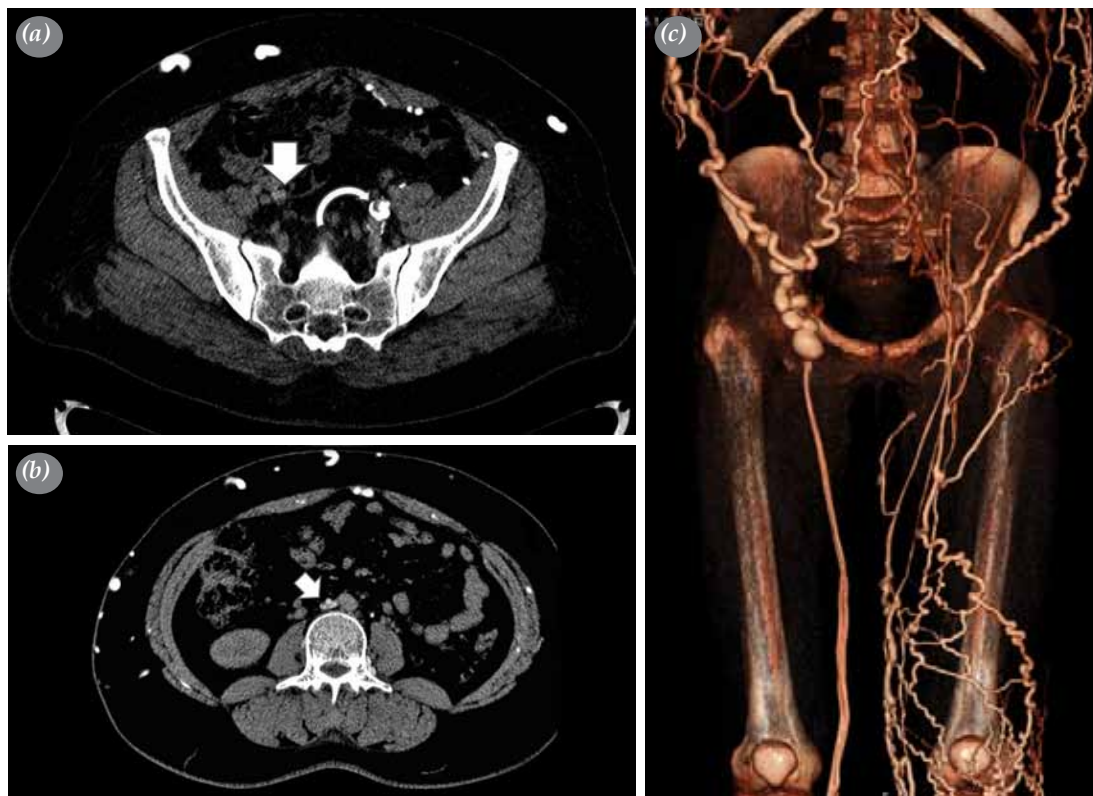
## RESULTS

### Technical success

*Pelvic veins:* Color Doppler US was diagnostic at 68 out of 150 venous segments at the pelvic region. No examination by CDUS could be conducted on the IVC in 16 patients (16 segments), the common iliac veins in 20 patients (40 segments), and the external iliac veins in 13 patients (26 segments) due to bowel gas and obesity; therefore, CDUS was considered nondiagnostic in these patients. Overall, CDUS demonstrated thrombosis in the pelvic region at 13 segments, whereas direct MDCT venography revealed thrombosis in the pelvic region at 21 segments. Of the patients for whom CDUS was nondiagnostic in the pelvic region, direct MDCT venography revealed additional thrombosis at seven segments. In addition, direct MDCT venography showed findings suggestive of partial thrombosis of the iliac vein in one patient, which was attributed to the flow



**Figure 1.** Axial cross-sectional and three dimensional volume rendering direct multidetector computed tomography images. (a) The partial thrombosis (white arrow) attached to the anterior wall of the inferior vena cava is seen on the cross sectional image. (b) Corresponding volume rendering image (anterior projection) reveals the contour irregularity at the mid portion of the inferior vena cava (white arrow). (c) This patient also had acute thrombosis of the right superficial-common femoral, and distal external iliac veins (white curved arrows).



**Figure 2.** Axial cross-sectional and three dimensional volume rendering direct multidetector computed tomography images. **(a)** Axial cross sectional images depict chronic thrombotic changes of the right common iliac vein (white arrow) and partial thrombosis of the left common iliac vein (white curved arrow). **(b)** The inferior vena cava lumen is narrowed and the wall is irregular (white arrow), which is compatible with chronic deep venous thrombosis. The inferior vena cava examination by color Doppler ultrasound was nondiagnostic (not shown). **(c)** Volume rendering image depicts occlusion of the left superficial femoral vein, right iliac veins, partial thrombosis of the left common femoral and iliac veins, and narrowed, irregular inferior vena cava. Note the extensive abdominal wall collateral pathways both on the cross-sectional and volume rendering images.

phenomenon. Color Doppler US was diagnostic in this patient and was not suggestive of thrombosis.

*Lower extremity veins:* All of the lower extremity veins (common and superficial femoral, popliteal, and crural veins) were successfully examined by CDUS (240 segments), which showed thrombosis at 74 segments but was not suggestive of thrombosis at 166 segments. Direct MDCT venography revealed findings suggestive of thrombosis at 78 segments but was not suggestive of thrombosis at 162 segments (Figure 1).

#### Individual venous segments

*Inferior vena cava:* Thrombosis was found in three segments. In two patients, CDUS was nondiagnostic due to technical reasons (bowel gas, obesity), and MDCT venography showed venous thrombosis (Figure 2). For the remaining 14 patients for whom CDUS was regarded as nondiagnostic, direct MDCT venography showed normal luminal filling with contrast. In one patient, both

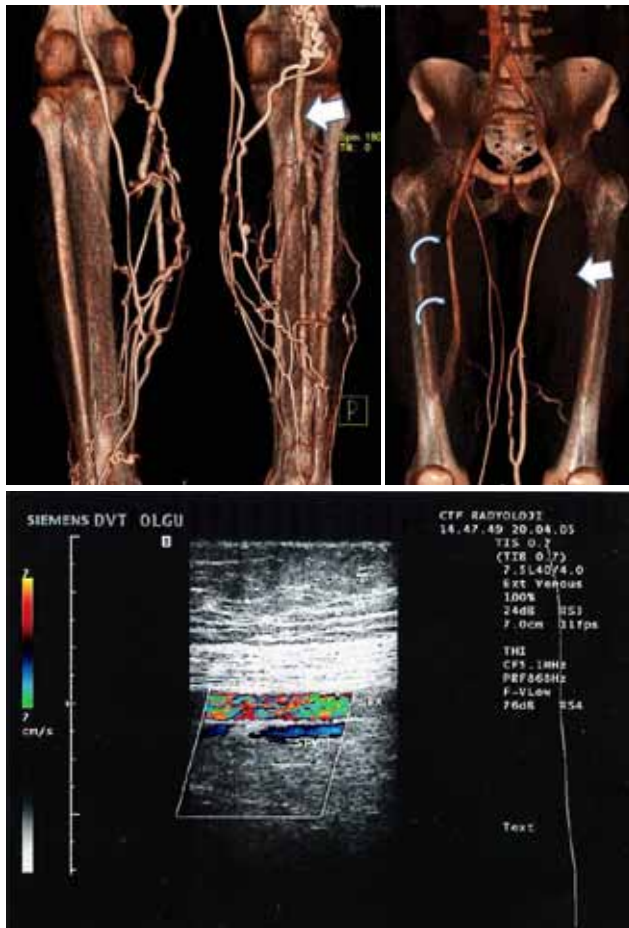
CDUS and direct MDCT venography were successful in identifying the IVC thrombus. In the remaining patients, both CDUS and direct MDCT venography revealed nothing abnormal.

*Common iliac veins:* Common iliac vein thrombosis was identified in seven segments. Of these, two were bilateral, and three were unilateral. Color Doppler US was regarded as incomplete in 20 patients (40 segments) due to limiting technical factors. For 20 patients, the examination was nondiagnostic on CDUS. Direct MDCT venography showed a normal vein lumen in 17 patients (34 segments) and venous thrombosis (Figure 3) in three patients (4 thrombosed segments and 2 normal segments). In 10 patients, the CDUS examination was regarded as adequate for this segment evaluation. Venous thrombosis was identified both by CDUS and direct MDCT venography in two patients (3 segments). The iliac vein segments were normal on both CDUS and direct MDCT venography in the remaining



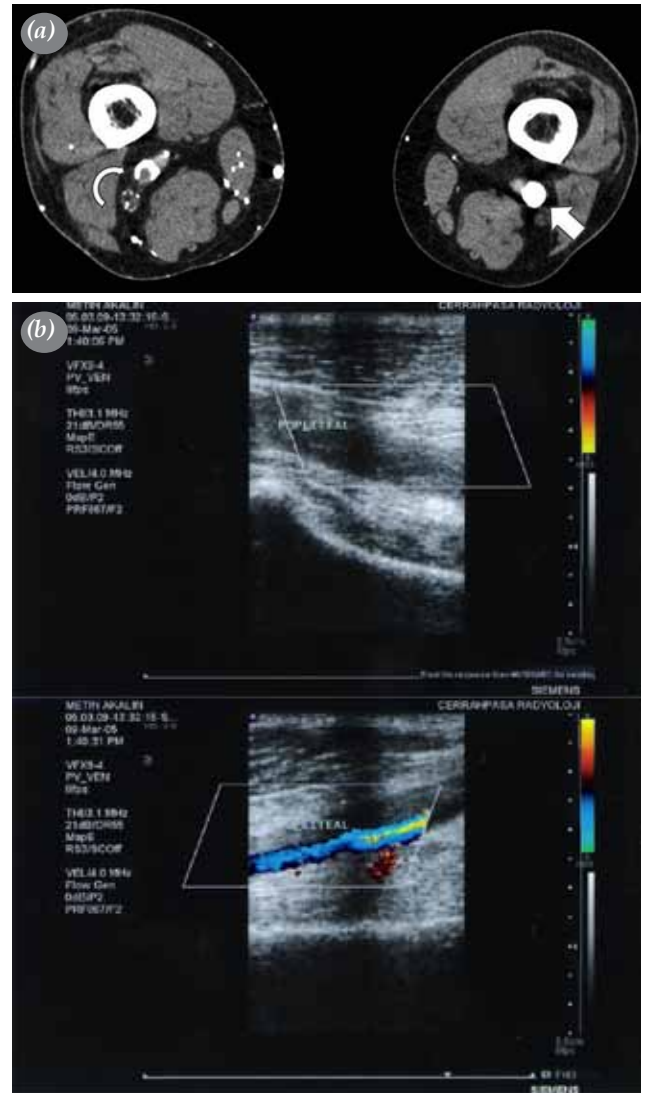
patients except for a patient with the appearance of pseudothrombosis on direct MDCT venography (1 segment). The CDUS examination clearly showed the lumen in this patient, and the appearance on direct MDCT venography was thought to be due to the flow phenomenon.

*External iliac veins:* Thrombosis was identified in eight patients (10 segments), with two being bilateral and six being unilateral. Color Doppler US was incomplete in 13 patients (26 segments) and adequate in 17 patients



**Figure 3.** Volume rendering direct multidetector computed tomography and color Doppler ultrasound examinations. (a) Volume rendering image at the level of the popliteal fossa (posterior projection) reveals total thrombosis of the left popliteal vein. The right popliteal vein (white arrow) successfully fills with contrast material. (b) Volume rendering image at the level of the thigh (anterior projection) depicts the patent right superficial femoral vein (white curved arrows) and complete occlusion of the left superficial femoral vein (pseudothrombosis) (white arrow). (c) Color Doppler ultrasound demonstrates left popliteal venous thrombosis (not shown) and a patent left superficial femoral vein. The vein diameter of the left superficial femoral vein was decreased due to low flow.

(34 segments). Direct MDCT venography depicted all the thrombosed venous segments, whereas CDUS revealed thrombosis in just seven patients (9 segments). Direct MDCT venography demonstrated thrombosis of the external iliac vein in one patient for whom the CDUS examination was incomplete.



**Figure 4.** Cross-sectional direct multidetector computed tomography and color Doppler ultrasound examinations. (a) Direct multidetector computed tomography reveals a normal superficial femoral vein diameter on the left (white arrow) and a decreased superficial vein diameter due to partial thrombus on the right (white curved arrow). The vein wall is irregular, and partial recanalization with contrast enhancement is seen on the right. Note also the contrast pooling artifact on the left side. (b) Corresponding color Doppler ultrasound shows a superficial femoral vein with decreased diameter and irregular intraluminal thromboses compatible with the chronic stage. Partial recanalization is also well documented on color Doppler ultrasound (blue colors within the lumen).

**Femoral veins:** Common femoral (CFV) and superficial femoral (SFV) veins were evaluated in this region, and it was possible to evaluate all the venous segments by CDUS. There were 33 thrombosed venous segments depicted by CDUS, and MDCT venography also showed the same segments. Additionally, in four patients (4 unilateral segments), direct MDCT venography showed nonopacification of the SFV lumen, which is suggestive of venous thrombosis (Figure 4). On CDUS examination, these venous segments were patent. All of these patients had popliteal venous thrombosis. The results of the direct MDCT venography were regarded as false positive in these patients because of the nonopacification due to distal venous occlusion.

**Popliteal veins:** Popliteal venous thrombosis was identified in 18 patients (22 segments). The thromboses were bilateral in four patients and unilateral in 14. Color Doppler US and direct MDCT venography were able to identify all the thrombosed segments. Direct MDCT venography showed additional false positive thrombosis in one patient. The calf veins were thrombosed in this patient, and the popliteal veins did not opacify with contrast material, suggesting thrombosis of the popliteal vein on direct MDCT venography. Color Doppler US, however, revealed the patent lumen of the popliteal veins in these patients.

**Calf veins:** At this level, four bilateral and 10 unilateral thromboses (18 segments) were depicted by CDUS. All the calf vein thromboses were also demonstrated by direct MDCT venography. Additionally, in one patient, an isolated muscular vein (gastrocnemius) thrombosis was diagnosed on CDUS, but the deep calf veins were normal on CDUS examination in this patient. Direct MDCT venography opacified the calf veins, but this muscular vein could not be detected.

### **Acute, subacute, and chronic thromboses**

Based on the duration of the symptoms and intraluminal appearance of the thrombi, a distinction between acute, subacute, and chronic thrombi could be made by CDUS. Of the 30 patients (390 segments), CDUS revealed thromboses in 87 segments, with 29 of them being acute, 16 being subacute, and 42 being chronic. In 12 venous segments with chronic thrombotic changes, an acute attack was identified on CDUS. On direct MDCT venography examinations, all the thromboses were seen as partial or total luminal filling defects. An increase in vein diameter was seen in segments with acute and subacute DVT on direct MDCT venography. In patients with chronic DVT, the venous segments had a decreased diameter or were collapsed with various contrast filling in the recanalized areas. In patients with chronic DVT, CDUS revealed low amplitude, partially recanalized

flow in 11 venous segments, and no flow in 31 venous segments. Multidetector CT venography also revealed flow in these recanalized venous segments.

### **False positive results on direct MDCT venography**

In order to visualize the nonopacified veins in slow venous flow due to the variable hemodynamic states and venous pathologies and prevent the appearance of false positive thrombosis, an additional craniocaudal scan was performed in all patients. In this way, it was possible to visualize the nonopacified vein segments in most of the patients.

In spite of the second scan, pseudothromboses were observed in six patients (6 segments), and unilateral total SFV filling defects suggestive of thromboses were observed in four patients. All of these patients had ipsilateral total popliteal thromboses, and the diluted contrast material did not fill the SFV lumen, thus giving the appearance of pseudothromboses. Similarly, in one patient, popliteal filling with the contrast material was not adequate due to acute DVT in the crural vein. The contrast material preferentially filled the collateral pathways in these patients. In another patient with a normal left iliac vein as seen on CDUS examination, there was the appearance of pseudothrombosis on direct MDCT venography due to the flow phenomenon.

## **DISCUSSION**

Conventional venography is accepted as the gold standard in the diagnosis of DVT, but it is often limited by its technical difficulty. Some authors now consider CDUS to be the gold standard. The search for new techniques has brought new developments in the diagnosis of DVT. Impedance plethysmography, scintigraphic investigations with iodine (I) 125-labeled fibrinogen, continuous wave Doppler US, both B-mode and CDUS, along with indirect and direct CT venographic examinations are alternative techniques now being used<sup>[5-7]</sup> Of these methods, only CDUS is able to show anatomic and hemodynamic information, and it is now accepted as the initial diagnostic tool of choice. Although it has a high sensitivity and specificity, certain limitations inherent to the technique exist. For example, viewing deep lying vessels of the extremities due to obesity or leg edema is somewhat difficult, but this problem can be overcome simply by selecting a low frequency transducer. Bowel gas in the pelvic region of an obese patient is another technical problem that is often seen, and the examinations are usually nondiagnostic in such a patient. With improvements in CT technology, different techniques have been generated in vascular imaging by the high scanning speed and by obtaining multiplanar

cross sections of the raw data. These techniques provide excellent anatomic information provided that the vessel lumen is adequately filled by the contrast medium. One such application area is the examination of the venous system of the lower extremities. In addition, ascending venography is insufficient for determining the proximal border of the thrombus in patients with thrombosis.<sup>[14-16]</sup> There are also similar limitations in direct MDCT venography. In our study, it was not possible to detect the proximal border of the thrombi in five venous segments (4 superficial femoral veins and popliteal 1 vein). In this situation, the contrast agent is drained by patent superficial veins and later by the CFV at the femoral region. If the saphenofemoral junction is also occluded, the contrast material is transmitted by the collateral veins at the gluteal and inguinal regions to the pelvic veins and then by the lumbar veins to the IVC. Direct MDCT venography showed a similar inadequacy to that of ascending venography in the evaluation of the venous segment distal to the collateral drainage point, which is actually patent. Taking into account this information, CDUS is more successful for determining the borders of pathologic segments at the lower extremities. Its main advantage is that the patient is not exposed to ionized radiation, although we decreased the total dose by applying a care dose. Furthermore, in indirect MDCT venography, 100 to 150 ml of intravenous iodinated contrast agent (or approximately 200 ml of iodinated contrast material with ascending venography) is used to opacify the lower extremity veins, iliac veins, and IVC. We tried to avoid the possible nephrotoxic effect of the iodinated contrast agent in our research by using fairly low doses (only 40 ml of contrast material diluted in 160 ml isotonic saline). However, CDUS has an advantage over MDCT venography in that it uses no iodinated contrast agent.

As shown in our study, although CDUS has lots of advantages, it has some limitations at the pelvic region. Bowel gas, which makes it difficult to get an image or often completely obliterates the image, is one of these limitations.<sup>[7,8]</sup> Direct MDCT venography, when performed with an appropriate technique, is better for the depiction of DVT at the pelvic region, but in the lower extremities, it may show false thrombosis in the presence of a more distally located venous occlusion. In our study, an additional pelvic venous thrombosis was detected at seven venous segments for which the CDUS was nondiagnostic.

Although on direct MDCT venography it is difficult to evaluate the proximal part of the thrombosed segment in the lower extremities, at the pelvic region, the vessel lumen successfully filled with the contrast material

with the aid of natural collateral venous connections. For instance, the CFV and iliac veins are opacified by the low-dose contrast material that is given to the dorsal veins of the foot in patients with SFV thrombosis. If there is additional CFV thrombosis, the proximal veins are filled again with the contrast agent with the aid of pelvic collaterals. Hence, although there is a need for safe venous cannulation on the dorsum of the foot due to exposure to ionized radiation and the intake of iodinated contrast material injections, even in low doses, the high cost of this procedure and the need for the exclusion of pregnant women are disadvantages of direct MDCT venography. This is true even though it has more successful results in the iliac vein and IVC examinations than CDUS.

In conclusion, a minimally invasive or noninvasive method is initially appropriate for the diagnosis of DVT. In view of this, CDUS is a reliable, easy, and cheap noninvasive method for the lower extremity veins that does not necessitate ionized radiation exposure or iodinated contrast agents. However, direct MDCT venography is more reliable in evaluating the extension of the thrombus to the iliac veins and IVC.

#### **Declaration of conflicting interests**

The authors declared no conflicts of interest with respect to the authorship and/or publication of this article.

#### **Funding**

The authors received no financial support for the research and/or authorship of this article.

#### **REFERENCES**

1. Hirsh J, Hoak J. Management of deep vein thrombosis and pulmonary embolism. A statement for healthcare professionals. Council on Thrombosis (in consultation with the Council on Cardiovascular Radiology), American Heart Association. *Circulation* 1996;93:2212-45.
2. Anderson FA Jr, Wheeler HB, Goldberg RJ, Hosmer DW, Patwardhan NA, Jovanovic B, et al. A population-based perspective of the hospital incidence and case-fatality rates of deep vein thrombosis and pulmonary embolism. The Worcester DVT Study. *Arch Intern Med* 1991;151:933-8.
3. Lensing AW, Prandoni P, Büller HR, Casara D, Cogo A, ten Cate JW. Lower extremity venography with iohexol: results and complications. *Radiology* 1990;177:503-5.
4. Loud PA, Katz DS, Klippenstein DL, Shah RD, Grossman ZD. Combined CT venography and pulmonary angiography in suspected thromboembolic disease: diagnostic accuracy for deep venous evaluation. *AJR Am J Roentgenol* 2000;174:61-5.
5. Maki DD, Kumar N, Nguyen B, Langer JE, Miller WT Jr, Gefter WB. Distribution of thrombi in acute lower extremity deep venous thrombosis: implications for sonography and CT and MR venography. *AJR Am J Roentgenol* 2000;175:1299-301.

6. O'leary DH, Kane RA. Venous ultrasonography of the lower extremities. In: Taylor KJW, Burns PN, Wells PNT, editors. *Clinical applications of Doppler ultrasound*. New York: Raven Press; 1988. p. 338-53.
7. Rose SC, Zwiebel WJ, Nelson BD, Priest DL, Knighton RA, Brown JW, et al. Symptomatic lower extremity deep venous thrombosis: accuracy, limitations, and role of color duplex flow imaging in diagnosis. *Radiology* 1990;175:639-44.
8. Montefusco-von Kleist CM, Bakal C, Sprayregen S, Rhodes BA, Veith FJ. Comparison of duplex ultrasonography and ascending contrast venography in the diagnosis of venous thrombosis. *Angiology* 1993;44:169-75.
9. Kim T, Murakami T, Hori M, Kumano S, Sakon M, Nakamura H. Efficacy of multi-slice helical CT venography for the diagnosis of deep venous thrombosis: comparison with venous sonography. *Radiat Med* 2004;22:77-81.
10. Katz DS, Loud PA, Bruce D, Gittleman AM, Mueller R, Klippenstein DL, et al. Combined CT venography and pulmonary angiography: a comprehensive review. *Radiographics* 2002;22 Spec No:S3-19.
11. Reid JH. Multislice CT pulmonary angiography and CT venography. *Br J Radiol* 2004;77 Spec No 1:S39-45.
12. Baldt MM, Zontsich T, Stümpflen A, Fleischmann D, Schneider B, Minar E, et al. Deep venous thrombosis of the lower extremity: efficacy of spiral CT venography compared with conventional venography in diagnosis. *Radiology* 1996;200:423-8.
13. Bettmann MA, Paulin S. Leg phlebography: the incidence, nature and modification of undesirable side effects. *Radiology* 1977;122:101-4.
14. Rampton JB, Armstrong JD Jr. Bilateral venography of the lower extremities. *Radiology* 1977;123:802-4.
15. Redman HC. Deep venous thrombosis: is contrast venography still the diagnostic "gold standard"? *Radiology* 1988;168:277-8.