

Conventional osteosarcoma of the rib: a case report

Kostanın konvansiyonel osteosarkomu: Olgu sunumu

Abidin Şehitoğulları,¹ Gülşay Bulut,² Ufuk Çobanoğlu,³ İrfan Bayram²

¹Department of Thoracic Surgery, Medical Faculty of Dicle University, Diyarbakır, Turkey;

²Department of Pathology, Medical Faculty of Yüzüncü Yıl University, Van, Turkey;

³Department of Thoracic Surgery, Medical Faculty of Yüzüncü Yıl University, Van, Turkey

Primary tumors of the rib are relatively uncommon in adults and rare in children. In this article, we present a case who was operated due to conventional osteosarcoma of the rib in the light of the literature review. A 17-year-old female patient had been operated due to a rib tumor 54 months ago. There was no local recurrence or metastatic disease. Chest wall tumors, particularly those arising from bones, require histologic assessment to be considered benign; the differential diagnosis of malignant neoplasms should not be based on clinical and radiographic features, only.

Key words: Conventional osteosarcoma; resection; rib.

Conventional osteosarcoma is usually the disease of the young^[1] that most frequently occurs in the second decade of life. Some 60% of those affected are under the age of 25. It affects males more frequently than females by a ratio of 3:2 and shows a profound propensity for involvement of the long bones of the appendicular skeleton, in particular the distal femur, proximal tibia, and proximal humerus. Conventional osteosarcoma tends to be a disease of the metaphysis (91%) or diaphysis (9%).^[2] Chest wall involvement has been reported to occur in only 3% of conventional osteosarcomas,^[3] and in 34% of these rare cases, it was located in the ribs.^[4]

CASE REPORT

A 17-year-old female patient presented with pain on the right side of her chest that had begun six months previously. The chest radiograph was unremarkable. An irregular, limited calcified mass with lobulated contours measuring 63x49 mm that had destroyed the ninth rib corpus was revealed on thoracic computed

Kostanın primer tümörleri erişkinlerde nispeten nadirdir, çocuklarda ise nadirdir. Bu yazıda kostanın konvansiyonel osteosarkomu nedeniyle ameliyat edilen bir olgu literatür gözden geçirilerek sunuldu. On yedi yaşındaki bayan olgu, 54 ay önce kosta tümörü nedeniyle ameliyat edilmişti. Lokal nüks veya metastaz saptanmadı. Özellikle, kemik kaynaklı göğüs duvarı tümörlerinde sadece klinik ve radyolojik özellikleri temel alınmamalı, malign tümörlerin farklı tanıları ve benign durumu da düşünülerek histolojik değerlendirme yapılmalıdır.

Anahtar sözcükler: Konvansiyonel osteosarkom; rezeksiyon; kosta.

tomography (CT) that was performed when her pain became more intense. Afterwards, the patient underwent thoracic surgery. The ninth rib was completely excised, and the lower and upper ribs were partially excised. Chemotherapy was then initiated. The patient demonstrated no evidence of local recurrence or metastatic disease in 54 months of follow-up.

The resected specimen consisted of dome-like, exophytic tumor of 15x6x4 cm at its greatest dimension (Figure 1). The cut surfaces revealed a gray-white, expansile tumor that filled the entire medullary cavity. The resection margins were free of tumor.

It was observed that most of the tumor tissue, which involved chondroblastic and osteoblastic focal adhesions, histopathologically consisted of cells that were fibroblastic in structure (Figures 2-4). Pleomorphism was not present in the fibroblastic areas, but there was a high mitotic activity. Immunohistochemistry revealed that these tumor cells were diffusely reactive for CD 99 and vimentin while the focal chondroid areas were



Available online at
www.tgkdc.dergisi.org
doi: 10.5606/tgkdc.dergisi.2012.185
QR (Quick Response) Code

Received: October 21, 2009 Accepted: April 20, 2010

Correspondence: Abidin Şehitoğulları, M.D. Dicle Üniversitesi Tıp Fakültesi, Göğüs Cerrahisi Anabilim Dalı, 21280 Diyarbakır, Turkey.

Tel: +90 505 - 759 10 95 e-mail: abidin_sehitoglu@yahoo.com



Figure 1. A photomicrograph showing a gray-white exophytic mass; the tumor is not present at both margins of resection.

poorly reactive for S-100. Tumor tissue was not present in the lower or upper ribs, surrounding soft tissue, or lungs.

DISCUSSION

Conventional osteosarcoma represents approximately 30% of all malignant sarcomas diagnosed in the United States,^[5] with the peak incidence occurring in the second decade of life.^[4,6] It is seen earlier in girls (age, 10-14 years) than in boys (age, 14-18 years), although there is a two-fold male preponderance.^[7] Chest wall involvement has been reported in only 3% of conventional sarcomas.^[2] Osteosarcoma arising from the chest wall is rare, and primary conventional osteosarcoma presenting in the rib poses a significant diagnostic challenge.^[3]

Symptoms generally develop from over a period of weeks to a few months. Early symptoms may wax

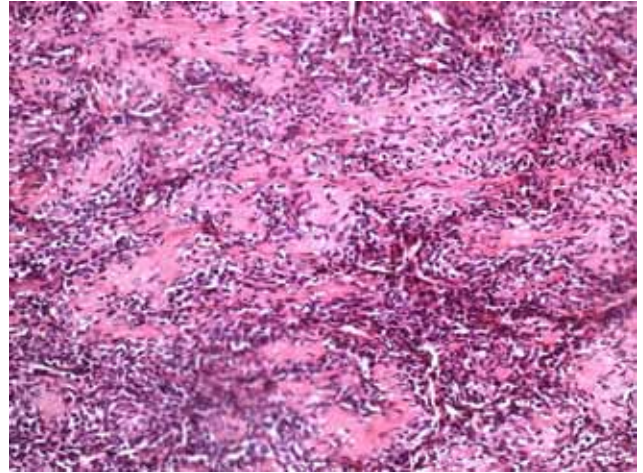


Figure 2. Conventional osteosarcoma showing the osteoblastic area (H-E x 20).

and wane and are, therefore, difficult to interpret. Eventually, these symptoms become unremitting. Although relatively non-specific, pain, either with or without a palpable mass, is the cardinal symptom of conventional osteosarcoma.^[2] There had been pain for six months and swelling for two and a half months in our case. During that time, the doctors gave her anti-inflammatory and analgesic medicines.

Untreated, conventional osteosarcoma is universally fatal, and aggressive local growth and rapid hematogenous systemic dissemination mark its course. Although metastases may affect many sites, pulmonary metastases are the most frequent site of clinically significant systemic disease.^[7] In our case, the tumor was not present in surrounding soft tissue and there is no pulmonary metastases.

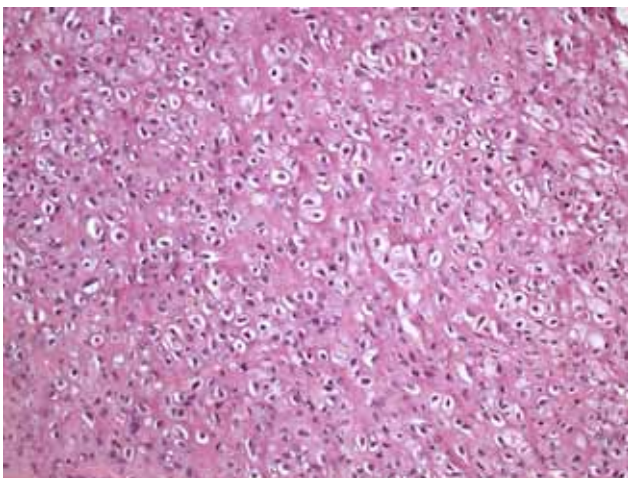


Figure 3. Conventional osteosarcoma showing the chondroblastic area (H-E x 20).

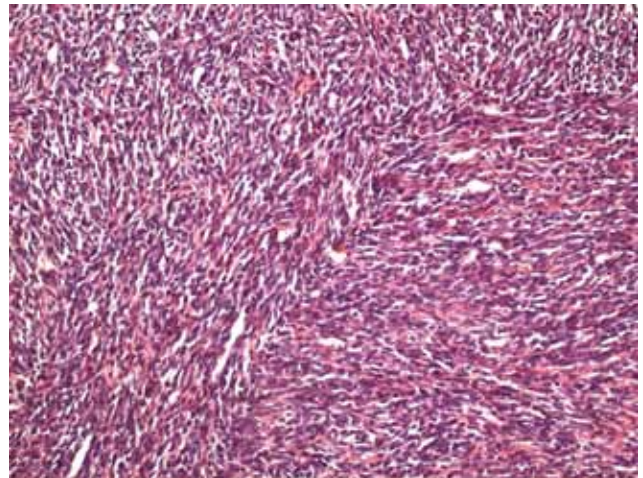


Figure 4. Conventional osteosarcoma showing the fibroblastic area (H-E x 20).

The lesion usually is detected by plain radiography as a soft tissue mass. The limitations of chest radiography include suboptimal visualization of any calcification within the mass, any rib destruction, and any periosteal reaction. The lesion may be misinterpreted as an extrasosseous chest wall tumor, teratoma, calcified mesothelioma, lung cancer, or lytic rib metastasis.^[8,9] Computed tomography and magnetic resonance imaging (MRI) may be helpful in delineating the extent of the tumor preoperatively.^[10-12] The latter studies are of paramount importance now that most patients have a potential for limb salvage.^[13,14]

Osteosarcoma is often a large (over 5 cm), metaphyseally-centered, fleshy or hard tumor that may contain cartilage. It frequently transgresses the cortex and is associated with a soft tissue mass. As a sarcoma, conventional osteosarcoma is frequently referred to as a “spindle-cell” tumor, a term that oversimplifies its cytological appearance. It tends to be a highly pleomorphic tumor in which the tumor cells may be epithelioid, plasmacytoid, fusiform, ovoid, small round cells, clear cells, mono- or multinucleated giant cells, or spindle cells, and most cases are complex mixtures of two or more of these cell types.^[1,3] In our case, the cut surfaces revealed a gray-white, expansile tumor that filled the entire medullary cavity. The tumor was not present at both margins of the resection.

A diagnosis of osteosarcoma is predicated on the accurate identification of the osteoid, which is, histologically, a dense, pink, amorphous intercellular material which may appear somewhat refractile. The osteoid must be distinguished from other eosinophilic extracellular materials such as fibrin and amyloid.^[1,2]

Conventional osteosarcoma contains three major subtypes: osteoblastic (50%), chondroblastic (25%), and fibroblastic (25%) ones. Osteosarcoma usually has diffuse moderate-to-strong, immunoreactive for CD99. It may also be immunoreactive for cytokeratin and is frequently immunoreactive to smooth muscle actin.^[11] In our case, the tumor cells included osteoblastic, chondroblastic, and fibroblastic areas. Immunohistochemically, CD99 and vimentin were diffusely positive throughout the tissue.

In conclusion, chest wall tumors, particularly those arising from bones, require histologic assessment to be considered benign since the differential diagnosis of malignant neoplasms cannot be based solely on clinical and radiographic features. Primary osteosarcoma of the rib should be considered in the differential diagnosis

in a young person with rib swelling. Early diagnosis and treatment improve the outcome, and combined-modality therapy consisting of surgery and aggressive chemotherapy may result in long-term conventional osteosarcoma survival.

Declaration of conflicting interests

The authors declared no conflicts of interest with respect to the authorship and/or publication of this article.

Funding

The authors received no financial support for the research and/or authorship of this article.

REFERENCES

1. Eckardt JJ, Pritchard DJ, Soule EH. Clear cell sarcoma. A clinicopathologic study of 27 cases. *Cancer* 1983;52:1482-8.
2. Raymond AK, Murphy GF, Rosenthal DI. Case report 425: Chondroblastic osteosarcoma: clear-cell variant of femur. *Skeletal Radiol* 1987;16:336-41.
3. Burt M, Fulton M, Wessner-Dunlap S, Karpeh M, Huvos AG, Bains MS, et al. Primary bony and cartilaginous sarcomas of chest wall: results of therapy. *Ann Thorac Surg* 1992;54:226-32.
4. Meyers PA, Gorlick R. Osteosarcoma. *Pediatr Clin North Am* 1997;44:973-89.
5. Boring CC, Squires TS, Tong T. Cancer statistics, 1992. *CA Cancer J Clin* 1992;42:19-38.
6. Rytting M, Pearson P, Raymond AK, Ayala A, Murray J, Yasko AW, et al. Osteosarcoma in preadolescent patients. *Clin Orthop Relat Res* 2000;373:39-50.
7. Whelan JS. Osteosarcoma. *Eur J Cancer* 1997;33:1611-8.
8. Kawa S, Kobayashi S, Hanzawa S, Wada G, Kimura H, Okamoto K. Computed tomography of parosteal osteosarcoma of the rib. *J Comput Tomogr* 1985;9:269-73.
9. Abdulrahman RE, White CS, Templeton PA, Romney B, Moore EH, Aisner SC. Primary osteosarcoma of the ribs: CT findings. *Skeletal Radiol* 1995;24:127-9.
10. Gillespy T 3rd, Manfrini M, Ruggieri P, Spanier SS, Pettersson H, Springfield DS. Staging of intraosseous extent of osteosarcoma: correlation of preoperative CT and MR imaging with pathologic macroslices. *Radiology* 1988;167:765-7.
11. McLeod RA, Berquist TH. Bone tumor imaging: contribution of CT and MRI. *Contemp Issues Surg Pathol* 1988;11:1-34.
12. Redmond OM, Stack JP, Dervan PA, Hurson BJ, Carney DN, Ennis JT. Osteosarcoma: use of MR imaging and MR spectroscopy in clinical decision making. *Radiology* 1989;172:811-5.
13. Onikul E, Fletcher BD, Parham DM, Chen G. Accuracy of MR imaging for estimating intraosseous extent of osteosarcoma. *AJR Am J Roentgenol* 1996;167:1211-5.
14. Botchu R, Ravikumar KJ, Sudhakar G. Osteosarcoma of rib in a seven-year-old child: a case report. *Eur J Orthop Surg Traumatol* 2006;16:156-7.