

Diagnosis and management of carotid body tumor: a report of seven cases

Karotis cisim tümörlerinin tanı ve tedavisi: Yedi olgu sunumu

**Gökhan İlhan,¹ Şahin Bozok,¹ Berkan Özpak,² Tevfik Güneş,² Orhan Gökalp,²
Serdar Bayrak,² Murat Aksun,³ Ali Gürbüz²**

¹Department of Cardiovascular Surgery, Medical Faculty of Recep Tayyip Erdoğan University, Rize, Turkey

²Department of Cardiovascular Surgery, Medical Faculty of Katip Çelebi University,
İzmir Atatürk Training and Research Hospital, İzmir, Turkey;

³Department of Anesthesiology and Reanimation, Medical Faculty of Katip Çelebi University,
İzmir Atatürk Training and Research Hospital, İzmir, Turkey

Paragangliomas are rare asymptomatic painless tumors, originating from paraganglionic bodies of autonomous nerve system of the embryological neural crest and increasing gradually. Despite their gradual developing nature, it is critical to reach early diagnosis and tailor surgical plan for carotid body tumors due to their potential of being malignant and local aggressive development, as well as invasion or pressure on the adjacent vascular and neural tissues. In this article, we present seven cases who were admitted with the complaints of pain and swelling in the neck and were diagnosed with carotid body tumor based on the further investigations and were surgically treated in the light of literature review and different surgical modalities were discussed.

Key words: Carotid body tumor; diagnosis; surgery; treatment.

Paragangliomalar embriyolojik nöral crestden gelişen otonom sinir sisteminin paraganglionik gövdelerinden ortaya çıkan ve yavaş büyüyen, nadir görülen, çoğunlukla asemptomatik ağrısız tümörlerdir. Yavaş büyüyen tümörler olmasına rağmen malignite ve lokal agresif büyüme potansiyelleri, komşu vasküler ve nöral dokulara invazyon veya baskı yapmaları nedeniyle karotis cisim tümörlerinin erken tanı ve cerrahi tedavilerinin planlanması önemlidir. Bu yazıda boyun bölgesinde ağrı ve şişlik yakınması ile başvuran, klinik muayene ve ileri incelemeler sonucu karotis cisim tümörü tanısı konulan ve cerrahi tedavi uygulanan yedi olgu, literatür bilgileri eşliğinde sunuldu ve uygulanan farklı cerrahi yöntemler tartışıldı.

Anahtar sözcükler: Karotis cisim tümörü; tanı; cerrahi; tedavi.

The carotid body, first described by Van Haller in 1743, is located in the carotid adventitia on the posterior aspect of the carotid bifurcation and is embryologically derived from the neuroectodermal tissue of the amine precursor uptake and the decarboxylation system.^[1] Carotid body tumors (CBTs) are rare and have an incidence of about 0.012%.^[2] Ten percent of these are familial, and out of this small percentage, 30% are bilateral in nature. Ultimately, bilateral familial CBTs are observed in only in 5% of the total number of cases of this type of tumor.^[2] Although CBTs have been observed in children, they are predominantly found in middle-aged adults, and the average age of

onset is 45 years.^[3] The etiology of CBTs is unknown, but there is an increased incidence in populations living at high altitudes and in patients with chronic obstructive pulmonary disease (COPD), which has led to the hypothesis that chronic stimulation of the carotid body by hypoxia may predispose certain people to the development of these tumors.^[4]

Although CBTs develop slowly, surgical resection remains the only curative treatment option.^[2] Scudder was the first surgeon to successfully remove this tumor while preserving the carotid system in 1903.^[5] In 1940, Gordon-Taylor showed a safe subadventitial plane of



Available online at
www.tgkdc.dergisi.org
doi: 10.5606/tgkdc.dergisi.2013.6541
QR (Quick Response) Code

Received: January 17, 2012 Accepted: July 27, 2012

Correspondence: Şahin Bozok, M.D. Recep Tayyip Erdoğan Üniversitesi Tıp Fakültesi, Kalp ve Damar Cerrahi Anabilim Dalı, 53100 Rize, Turkey.

Tel: +90 464 - 217 03 65 e-mail: sahinboz@yahoo.com

tumor dissection.^[6] However, when dealing with large CBTs, ligation of the carotid artery was necessary for resection at that time, and mortality approached 50% in those who survived.^[6] Later, several techniques were developed to save carotid artery circulation which decreased the postoperative morbidity rates. The Shamblin classification is used to assess the difficulty of surgical resection. Type 1 tumors are relatively small and easy to resect, type 2 CBTs are larger and partially surround the vessels, and type 3 tumors completely surround the carotid bifurcation.^[7]

In this article we report our five years of surgical experience in seven patients with previously untreated CBTs of different sizes and degrees of arterial involvement and then we evaluated the outcomes.

CASE REPORT

Case 1- A 58-year-old female patient was admitted to our clinic with the complaints of swelling and pain on the left side of the neck for the past two years. Her medical and familial history was nonspecific. Physical examination revealed an elastic 3-4 cm mass which was pulsatile in the left sternocleidomastoid (SCM) muscle and mobile in the horizontal plane and immobile in the vertical plane. Based on the preoperative findings, the patient was diagnosed with carotid body tumor. The vascular tumor which was located between internal carotid and external carotid was excised under general anesthesia, preserving the vascular structures and cranial nerves. No vascular or neurological complications were observed in the intraoperative and postoperative period. The patient has been followed up for 52 months without any complication.

Case 2- A 54-year-old male patient was admitted to our clinic with the complaints of increasing swelling on the left side of the neck and dysphonia lasting for two years. Physical examination revealed a pulsatile and painless mass in the left SCM muscle. Systemic examination, biochemistry tests and blood parameters were normal. Preoperative tests revealed a homogenous and solid 35-48 mm tumor with smooth margins and significant vasculature located at the carotid bifurcation, which was consistent with a carotid body tumor. The tumor was not severely adhesive for the artery and adjacent tissues (Shamblin II) and was excised using dissection technique in the subadventitial plane, preserving the carotid integrity. No complication was observed in the intraoperative and postoperative period. The patient has been followed for 36 months without any complication.

Case 3- A 48-year-old female patient was referred to our clinic from another health care center with the

complaint of swelling in the right side of the neck. The patient reported that she had increasing swelling for 18 months. Physical examination revealed an immobile and painless 4-5 cm mass which was pulsatile in the right side of the neck located behind the mandibular angle, lying up to the earlobe with smooth margins. Based on the findings, the patient was diagnosed with carotid body tumor and underwent surgery. The common carotid artery, internal carotid artery (ICA) and external carotid artery were completely surrounded by the tumor. Tumor and arterial segments surrounded were completely excised. A carotid shunt was used due to the stump pressure of <50 mmHg during the excision. Carotid artery occlusion took 12 minutes. A 6 mm polytetrafluoroethylene (PTFE) graft was used for the ICA shunting. No complication was observed in the intraoperative and postoperative period. The patient has been followed for 36 months without any complication.

Case 4- A 56-year-old female patient who had been previously admitted to another health care center was referred to our clinic with the complaint of increasing swelling in the right side of the neck for 18 months. Physical examination revealed an elastic and painless 3.5x4 cm mass which was pulsatile in the right anterior SCM muscle and mobile in the horizontal plane and immobile in the vertical plane. Based on the findings of digital subtraction angiography (DSA) which was performed in the referrer center previously and color Doppler ultrasonography (USG) and contrast enhanced spiral tomography, the patient was diagnosed with carotid body tumor. The tumor which was located between internal carotid and external carotid was excised using dissection technique in the subadventitial plane. No vascular or neurological complication were observed in the intraoperative and postoperative period. The patient has been followed for 18 months without any complication.

Case 5- A 46-year-old male patient was admitted to our clinic with the complaint of increasing swelling in the right side of the neck for about 1.5 years. Physical examination revealed a pulsatile, solid, ovale, elastic and painless 4 cm mass in the right SCM muscle. Systemic examination, biochemistry tests and blood parameters were normal. Based on the physical examination findings and tests, the patient was diagnosed with carotid body tumor. During the operation performed under general anesthesia, vascular structures were completely surrounded by the tumor. Carotid artery occlusion took 10 minutes for the patient who did not require a shunt. Tumor and arterial segments surrounded were completely excised. A 6 mm PTFE graft was used for

the ICA shunting. The patient has been followed for six months without any complication.

Case 6– A 36-year-old female patient was admitted to our clinic with the complaints of increasing swelling in the left side of the neck, headache and tinnitus lasting for about six months. Physical examination revealed an elastic painful 3x4 cm mass, which was pulsatile in the left anterior SCM. Based on the findings of further assays, the patient was diagnosed with carotid body tumor. During surgery performed under general anesthesia, the common carotid, internal carotid and external carotid arteries were surrounded by the tumor. Tumor and vascular structures surrounded were excised and saphenous vein graft was used for the ICA shunting. No shunt was used for the patient whose carotid artery clamping time was seven minutes. No vascular or neurological complications were observed in the intraoperative and postoperative period. The patient has been followed up for 24 months without any complication.

Case 7– A 65-year-old female patient was admitted to our clinic with the complaints of increasing swelling in the left side of the neck and dysphagia lasting for about one year. Physical examination revealed a pulsatile and painful mass in the left SCM muscle. Systemic examination, biochemistry tests and blood parameters were normal. Her medical and familial history was nonspecific, except hypertension. Based on the findings of physical examination and further assays, the patient was diagnosed with carotid body tumor. During surgery performed under general

anesthesia, the common carotid, internal carotid and external carotid arteries were completely surrounded by the vascularized tumor. External carotid artery and its branches were clamped and the tumor and arterial segments surrounded were completely excised to prevent further bleeding. A carotid shunt was used due to the stump pressure of <50 mmHg during the excision. Arterial shunting was maintained by end to end anastomosing of the elongated ICA. Carotid artery occlusion took nine minutes. No vascular or neurological complications were observed in the intraoperative and postoperative period. The patient has been followed for 32 months without any complication.

None of the patients indicated any metastatic finding based on the preoperative tests. The preoperative Doppler ultrasonography (USG) and computed tomography (CT) performed on all seven of the patients, five also underwent magnetic resonance (MR) angiography, one underwent computed tomography (CT) angiography, and another patient underwent DSA (Figures 1a, b, 2a, b), (Table 1). We used the MR angiography for the evaluation of arterial anatomy, vascular flow and intraoperative vascular control in three patients, and in two more who had been referred from an external center. Computed tomography angiography was also performed on one of these referred patients, and DSA was performed on the other.

Under general anesthesia, a laterally-inclined incision along the anterior border of the sternomastoid

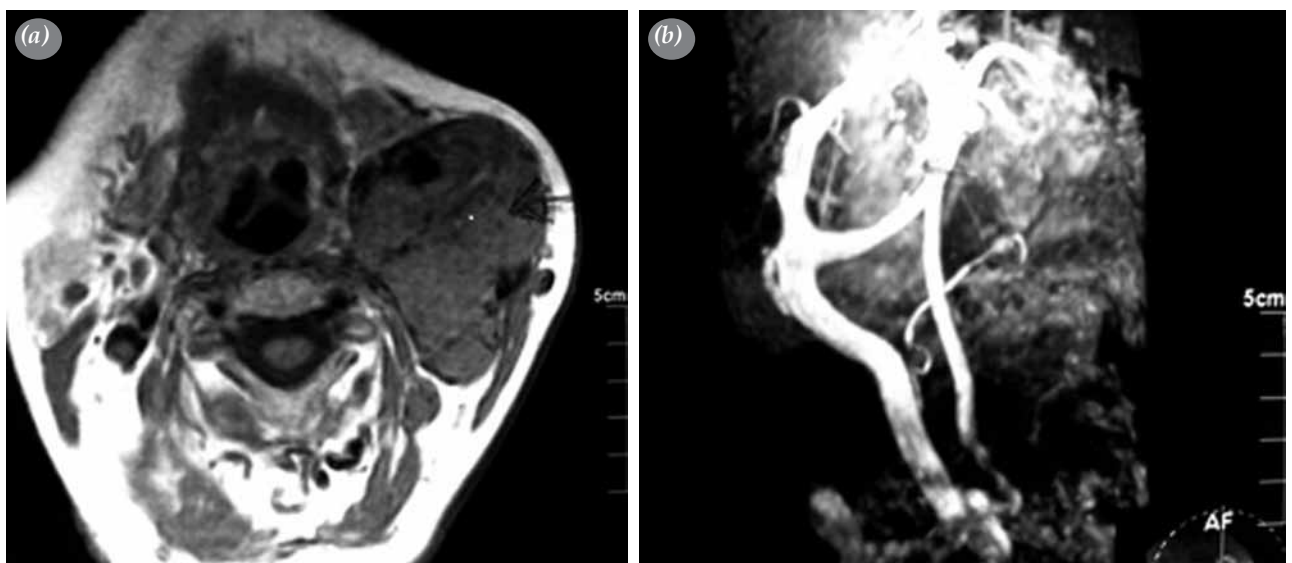


Figure 1. (a) Computed tomography scan showing the left carotid body tumor. (b) Preoperative magnetic resonance imaging of the same patient.

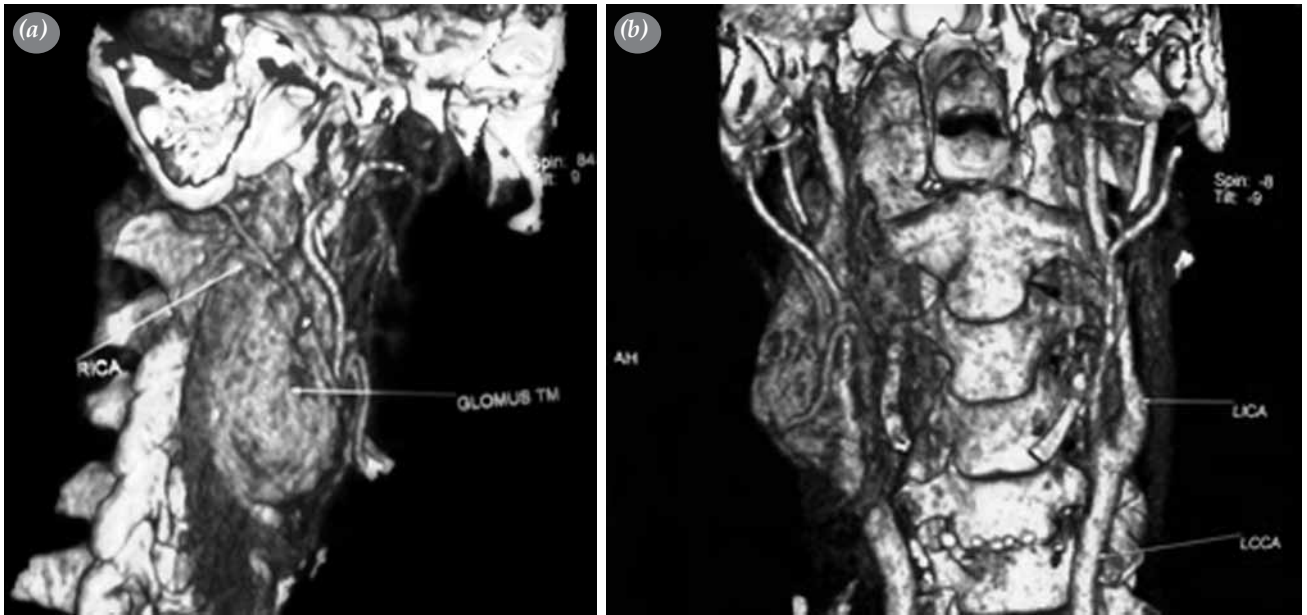


Figure 2. (a, b) Preoperative computed tomography angiography of a right carotid body tumor.

muscle was performed; however, an oblique anterior neck incision was preferred in one patient because of the extreme growth of the tumor and its pressure on the surrounding tissues. In order to lessen the nerve damage, bipolar cautery was used. In all patients, the vagus and hypoglossal cranial nerves were carefully identified in order not to damage them during the tumor excision.

At surgery, three patients were found to have type 2 tumors while four had large type 3. Complete resection of the tumor was achieved in all cases. In three patients, no arterial reconstruction was required, and the tumor was dissected under the carotid adventitial plane.

In four patients, it was determined that the internal and external carotid arteries (ECAs) were completely surrounded by the vascularized tumor (Figure 3). In order to prevent excessive bleeding in these patients, the ECA and its branches were clamped and ligated. Furthermore, the arterial segments surrounded by the tumor were excised along with the tumor. In two of these four patients, the stump pressure was over 50 mmHg, and the integrity of the ICA was maintained with a PTFE graft of 6 mm in length. In addition, the ICA was replaced with a saphenous vein interposition graft in one of these cases, and end-to-end anastomosis was performed on the other (Table 1).

Through histopathological examinations, the excised bodies were reported as paraganglioma, but

malignancy was not detected in any patient. Atypical histopathological findings (giant cells common in tumors, hyperchromatic nuclei, and a pleomorphism) were identified in one patient, but they were also determined not to be malignant (Figure 4).

Any neurological complications were observed during the postoperative follow-up period. No patient was lost to follow-up, and none showed any signs of local recurrence or metastases at the last follow-up visit. The patency rate of the arterial reconstructions was 100%.

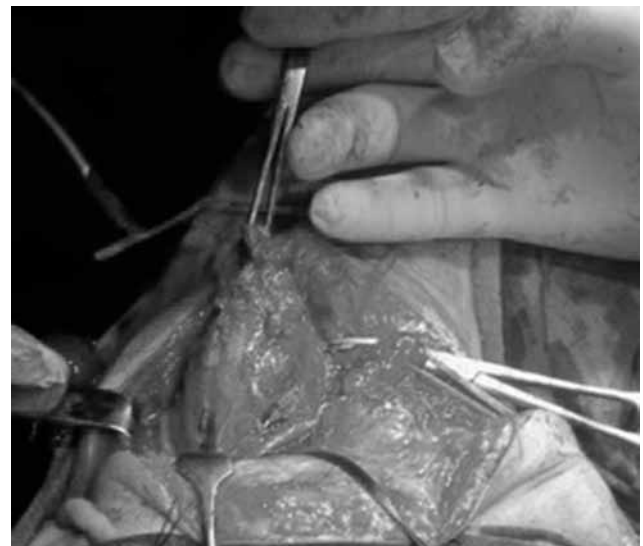


Figure 3. Operative picture revealing the carotid body tumor engulfing the carotid vessels.

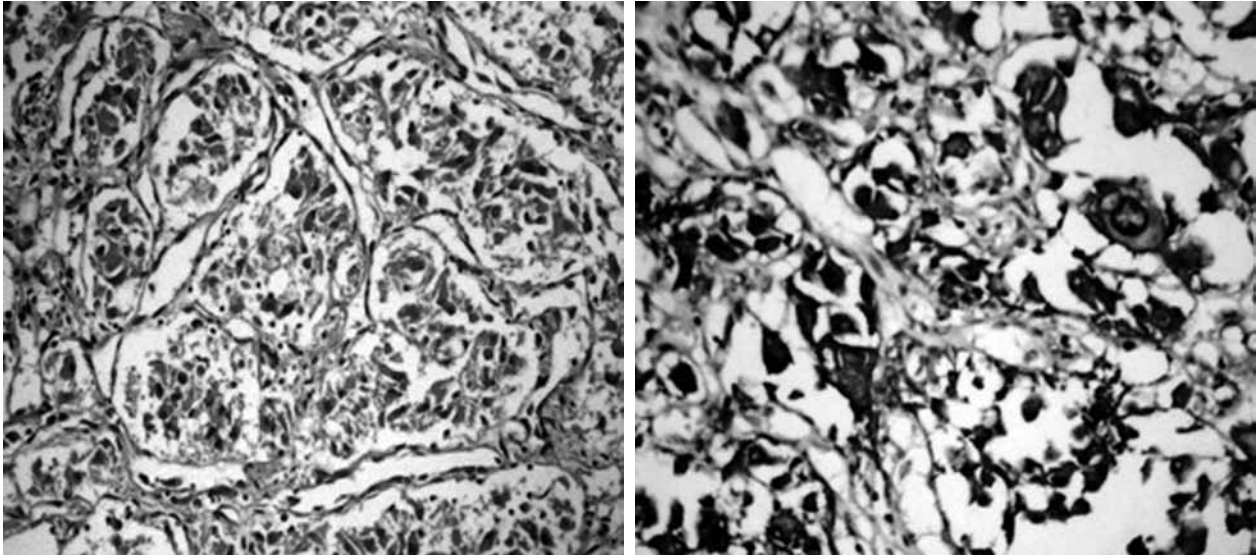


Figure 4. Cytoplasmic chromogranin positivity (H-E x 220).

DISCUSSION

Carotid body tumors are uncommon entities, and their surgical management is technically challenging. As gradually increasing numbers of medical centers have surgeons capable of managing these tumors, there has been a decrease in the large number of cases referred to specialized centers. The aim of this study was to assess the outcome of the surgical management of carotid body tumors in our own department.

Carotid body tumors are found in both sides of the neck and both genders at the same rate of frequency,^[8] and they belong to a group of tumors called paragangliomas that can be found at many locations in the body. Multicentricity of paragangliomas can occur in up to 25% of patients with CBTs, but this was not observed in our series.^[9]

The most common presentation in patients with CBTs is a slowly enlarging painless mass in the neck.^[10] Locally invasive growth of these tumors subsequently leads to cranial nerve deficits along with compression symptoms like Horner’s syndrome, syncope, hoarseness and dysphagia.^[9,10] Cranial nerve deficits, particularly in the cranial nerves VII, IX, X, XI, or XII, can be seen in tumors that reach 5 cm in size. In our series, all tumors presented as a neck mass (pulsatile masses in 6 patients). Although none of the tumors reached 5 cm in size, two patients presented with hoarseness and dysphagia.

For the diagnosis of CBTs, color Doppler USG is the first non-invasive procedure which allows for the determination of discrimination between the solid and cystic nature of the carotid body, its aneurysm, and its relationship with the carotid artery bifurcation.^[11] The gold standard for diagnosis is carotid angiography,

Table 1. Patient characteristics, method of diagnosis, and surgical treatment of the seven patients

No	Age/gender	First symptom	Method of diagnosis			Size of tumor (mm)	Tumor stage	Type of operation
			Doppler USG	CT	Angiography			
1	58/F	Pulsative neck mass	+	+	MRA	28x36	Shamblin II	Subadventitial excision
2	46/M	Pulsative neck mass	+	+	MRA	34x44	Shamblin II	Subadventisyal excision
3	48/F	Pulsative neck mass	+	+	CTA	38x46	Shamblin III	Excision + PTFE graft
4	56/F	Pulsative neck mass	+	+	DSA	35x46	Shamblin II	Subadventisyal excision
5	36/F	Pulsative neck mass, headache, tinnitus	+	+	MRA	35x40	Shamblin III	Excision + PTFE graft
6	54/M	Neck mass, hoarseness	+	+	MRA	34x48	Shamblin III	Excision + Saphena interposition graft
7	65/F	Pulsative neck mass, dysphagia	+	+	MRA	42x50	Shamblin III	Excision + end-to-end anastomosis

USG: Ultrasonography; CT: Computed tomography; MRA: Magnetic resonance angiography; CTA: Computed tomography angiography; DSA: Digital subtraction angiography; PTFE: Polytetrafluoroethylene.

which serves both diagnostic and treatment purposes.^[12] Magnetic resonance angiography, CT angiography, and DSA all can demonstrate the extent of the tumor and its relationship to adjacent structures.^[8] In addition to the preoperative Doppler USG and CT performed on all of our patients, we used MR angiography for five patients, CT angiography for one, and DSA for another. In the differential diagnosis of CBTs, bronchial cysts, salivary gland tumors, carotid artery aneurysms, lateral aberrant glandulae thyroideae, malignant lymphoma neurofibroma, tuberculosis lymphadenitis, and metastatic carcinomas should be considered. Carotid body tumors may also accompany cancers of the larynx, breast, cervix, and colon.^[8,13] Computed tomography scanning is recommended to delineate the extent of the mass and to rule out multicentric foci.

Surgical resection remains the mainstay of treatment given the aggressive growth and malignant potential of CBTs.^[3,14] Shamblin type 1 and 2 tumors can often be dissected in a periadventitial plane without traumatizing the carotid vessels and without any need for arterial repair. If the proper plane between the tumor and the carotid arteries cannot be developed, resection of the involved portion may be required. The ICA should then be reinserted to the common carotid artery (CCA) or replaced with a saphenous vein interposition graft. Ligation of the ICA is associated with a high risk for stroke and a high mortality rate and should be avoided if possible.^[15] On the other hand, reconstruction of the ECA following tumor resection is not necessary, and it may be ligated.^[16] Complete resection of the tumor was achieved in all cases in the present study. In three patients, the tumor was dissected completely in a subadventitial plane while in the four others, it was determined that the ICA and ECA were completely surrounded by the vascularized tumor. Therefore, the ECA and its branches were ligated, and maintenance of the ICA was provided via the use of the PTFE graft in two patients. Additionally, a saphenous vein interposition graft was utilized in one case, and end-to-end anastomosis was applied in another.

Operations for CBTs are not risk-free.^[2] As the tumor grows, the surgery becomes more difficult, and the postoperative complication rate increases. The high rate of cranial nerve deficit on the first postoperative day may approach 49%.^[2,14] However, the majority of cranial nerve deficits are reversible, and the incidence of permanent cranial nerve palsy is reported to be low in the literature.^[2,14] Nevertheless, surgeons should be prepared to employ vascular reconstructive techniques, if necessary. All seven of our patients were neurologically asymptomatic at the last follow-up visit. During the course of the resection of the tumor, if external carotid

artery ligation is needed and the stump pressure is below 50 mmHg, the creation of a shunt lessens the cerebral infarct risk.

Integrity of the ICA should be maintained by either a saphena vein or synthetic graft. In cases in which the clamping period is less than 10 minutes, the risk of developing neurological damage is quite low.^[17] Many authorities have emphasized that radical resection prevented local recurrence and favorably affected the long-term results.^[18]

We did not use preoperative embolization in any of the patients because of the risk of stroke associated with accidental ICA embolisms when using the embolization material.^[14] Besides, in the literature, the true benefit of this intervention is still being debated. Moreover, Litle et al.^[19] showed that preoperative embolization does not significantly improve the outcome in patients undergoing resection of CBTs.

The malignant potential of CBTs has been estimated at between 5 and 10%,^[20] but in young patients, the rate is higher.^[13,20] Malignancy is determined by the detection of metastases in local lymphatic nodes or remote organs such as the lungs, bones, liver, pancreas, thyroid, breast, and thorax rather than by the histological criteria or development of malignancy in neoplasms. The incidence of local or distant metastases is less than 10%.

Although CBTs are slowly developing tumors, early diagnosis as well as the planning of surgical treatment are important because of their malignancy, locally aggressive growth potential, invasiveness, and pressure they place on the neighboring vascular and neural tissues. Early surgery will serve to decrease the neurological and vascular complications associated with CBTs. As metastasis may develop years after the first resection, long-term follow is necessary.

Declaration of conflicting interests

The authors declared no conflicts of interest with respect to the authorship and/or publication of this article.

Funding

The authors received no financial support for the research and/or authorship of this article.

REFERENCES

1. Van Haller (1743). Cited by Kohn A. Die paranganglien. Arch Mikr Anat 1903;62:263-8.
2. Sajid MS, Hamilton G, Baker DM; Joint Vascular Research Group. A multicenter review of carotid body tumour management. Eur J Vasc Endovasc Surg 2007;34:127-30.
3. Luna-Ortiz K, Rascon-Ortiz M, Villavicencio-Valencia V, Granados-Garcia M, Herrera-Gomez A. Carotid body tumors:

- review of a 20-year experience. *Oral Oncol* 2005;41:56-61.
4. Chedid A, Jao W. Hereditary tumors of the carotid bodies and chronic obstructive pulmonary disease. *Cancer* 1974;33:1635-41.
 5. Kaman L, Singh R, Aggarwal R, Kumar R, Behera A, Katariya RN. Diagnostic and therapeutic approaches to carotid body tumours: report of three cases and review of the literature. *Aust N Z J Surg* 1999;69:852-5.
 6. Gordon-Taylor G. On carotid tumours. *Br J Surg* 1940;28:163-72.
 7. Shamblin WR, ReMine WH, Sheps SG, Harrison EG Jr. Carotid body tumor (chemodectoma). Clinicopathologic analysis of ninety cases. *Am J Surg* 1971;122:732-9.
 8. Dickinson PH, Griffin SM, Guy AJ, McNeill IF. Carotid body tumour: 30 years experience. *Br J Surg* 1986;73:14-6.
 9. LaMuraglia GM, Fabian RL, Brewster DC, Pile-Spellman J, Darling RC, Cambria RP, et al. The current surgical management of carotid body paragangliomas. *J Vasc Surg* 1992;15:1038-44.
 10. Kotelis D, Rizos T, Geisbüsç P, Attigah N, Ringleb P, Hacke W, et al. Late outcome after surgical management of carotid body tumors from a 20-year single-center experience. *Langenbecks Arch Surg* 2009;394:339-44.
 11. Seabrook GR, Haimovici H, Ascer E, Hollier LH, Strandness DE, Towne JB. Nonatherosclerotic cerebrovascular disease. Haimovici's vascular surgery, United States of America, Blackwell Science, Inc.; 1996.
 12. van der Mey AG, Frijns JH, Cornelisse CJ, Brons EN, van Dulken H, Terpstra HL, et al. Does intervention improve the natural course of glomus tumors? A series of 108 patients seen in a 32-year period. *Ann Otol Rhinol Laryngol* 1992;101:635-42.
 13. Wang SJ, Wang MB, Barauskas TM, Calcaterra TC. Surgical management of carotid body tumors. *Otolaryngol Head Neck Surg* 2000;123:202-6.
 14. Plukker JT, Brongers EP, Vermey A, Krikke A, van den Dungen JJ. Outcome of surgical treatment for carotid body paraganglioma. *Br J Surg* 2001;88:1382-6.
 15. Dardik A, Eisele DW, Williams GM, Perler BA. A contemporary assessment of carotid body tumor surgery. *Vasc Endovascular Surg* 2002;36:277-83.
 16. Krupski WC. Carotid body tumors. In: Rutherford RB, editor. *Vascular surgery*. 6th ed. Philadelphia: W.B. Saunders; 2006. p. 2066-73.
 17. Patetsios P, Gable DR, Garrett WV, Lamont JP, Kuhn JA, Shutze WP, et al. Management of carotid body paragangliomas and review of a 30-year experience. *Ann Vasc Surg* 2002;16:331-8.
 18. Muhm M, Polterauer P, Gstöttner W, Temmel A, Richling B, Undt G, et al. Diagnostic and therapeutic approaches to carotid body tumors. Review of 24 patients. *Arch Surg* 1997;132:279-84.
 19. Litle VR, Reilly LM, Ramos TK. Preoperative embolization of carotid body tumors: when is it appropriate? *Ann Vasc Surg* 1996;10:464-8.
 20. McPherson GA, Halliday AW, Mansfield AO. Carotid body tumours and other cervical paragangliomas: diagnosis and management in 25 patients. *Br J Surg* 1989;76:33-6.