

## A rare cause of acute respiratory failure: spontaneous pneumomediastinum due to cocaine use

*Akut solunum yetmezliğinin nadir bir nedeni:  
Kokain kullanımına bağlı spontan pnömomediastinum*

Mehmet Erdem Memetoğlu,<sup>1</sup> Asım Kalkan,<sup>2</sup> Nuri Tutar,<sup>3</sup> Serpil Kurtcan,<sup>4</sup> Abdülkadir Gündüz<sup>2</sup>

<sup>1</sup>Department of Cardiovascular Surgery, Gümüşhane State Hospital, Gümüşhane, Turkey

<sup>2</sup>Department of Emergency Medicine, Karadeniz Technical University, Faculty of Medicine, Trabzon, Turkey

<sup>3</sup>Department of Chest Diseases, Gümüşhane State Hospital, Gümüşhane, Turkey

<sup>4</sup>Department of Radiology, Gümüşhane State Hospital, Gümüşhane, Turkey

Spontaneous pneumomediastinum is defined as free air in mediastinum without any underlying pulmonary pathology. Although spontaneous pneumomediastinum is a rarely seen clinical entity, it is one of the most common reasons of sudden pleuritic chest pain in healthy young individuals. Cocaine inhalation is also associated with the development of spontaneous pneumomediastinum. Our case having spontaneous pneumomediastinum was referred to our emergency service with the complaint of acute respiratory failure due to cocaine abuse, and the etiology, clinical presentation and the treatment of the disease were evaluated in our study.

**Key words:** Acute respiratory failure; cocaine; spontaneous pneumomediastinum.

Drug abuse is a serious public health problem and may cause many thoracic complications. The drugs associated with these complications are cocaine, opioids, and methamphetamines, and these may be used in a variety of ways. The thoracic complications are related to the pulmonary, pleural, mediastinal and cardiovascular systems, and the mediastinal involvement may include pneumopericardium and pneumomediastinum, which can occur due to the inhalation of cocaine, increased intraalveolar pressure, or alveolar interstitial injury. After alveolar injury, free air may pass through the mediastinum.

Spontan pnömomediastinum, altta yatan pulmoner patoloji olmaksızın mediastende serbest hava olması olarak tanımlanır. Spontan mediastinum, nadir görülen bir klinik tablo olsa da sağlıklı genç bireylerde, ani plöretik göğüs ağrısının en sık nedenlerinden biridir. Kokain inhalasyonu, spontan pnömomediastinum gelişmesi ile de ilişkilidir. Bu yazıda, kokain kullanımına bağlı akut solunum yetmezliği ile acil servisimize sevk edilen spontan pnömomediastenli 20 yaşında erkek hasta sunuldu ve hastalığın etyolojisi, klinik prezentasyonu ve tedavisi değerlendirildi.

**Anahtar sözcükler:** Akut solunum yetmezliği; kokain; spontan pnömomediastinum.

The increased bronchovascular pressure gradient allows for bubbles of alveolar gas to dissect the perivascular sheaths and connective tissue planes and move to the mediastinum. This air then usually expands into the neck along the contiguous layers of the deep cervical fascia, preventing tamponade and resulting in surgical emphysema.

### CASE REPORT

A 20-year-old male patient presented to our emergency room with complaints of retrosternal chest pain, shortness of breath, and swelling of the neck. He had



Available online at  
www.tgkdc.dergisi.org  
doi: 10.5606/tgkdc.dergisi.2013.4385  
QR (Quick Response) Code

Received: April 1, 2010 Accepted: July 12, 2010

Correspondence: Mehmet Erdem Memetoğlu, M.D. Gümüşhane Devlet Hastanesi, Kalp ve Damar Cerrahisi Kliniği, 29000 Gümüşhane, Turkey.

Tel: +90 456 - 213 15 56 e-mail: dr.m.erdem07@hotmail.com

a two-year history of smoking crack cocaine, and he had used cocaine four hours before his complaints began. He had previously been hospitalized for his cocaine addiction and had received medical therapy to help him overcome his habit. He did not have any history of trauma, pulmonary disease, severe coughing, vomiting, or athletic activity. On physical examination, the patient was anxious and conscious. He had a pulse rate of 123 beats/minute, a temperature of 37 °C, and a respiratory rate of 60 breaths/minute. His blood pressure was 135/90 mmHg. The arterial blood gas analysis resulted that pH: 7.326; partial pressure of oxygen (pO<sub>2</sub>): 85 mmHg, partial pressure of carbon dioxide (pCO<sub>2</sub>): 43.6 mmHg; oxygen saturation (SO<sub>2</sub>): 99.2 mmHg and bicarbonate (HCO<sub>3</sub>): 21.5 mEq/L. The complete blood cell (CBC) count and chemistry profile were normal, and the electrocardiogram showed a sinus rhythm of 100 beats.

His arterial oxygen saturation with peripheral pulse oximeter was 90% with room air. Crepitus was noted over the neck and supraclavicular regions.

Chest percussion revealed hyperresonance over the sternum with diminished breath sounds over the right lung bases. Hamman's sign (a crunching sound during systole heard maximally over the right lower sternal border) was present. Pneumomediastinum with subcutaneous emphysema involving the bilateral neck region and shoulders was detected in the posteroanterior chest X-ray (Figure 1), and free air in the mediastinum was found via thoracic computed tomography (CT) (Figure 2).

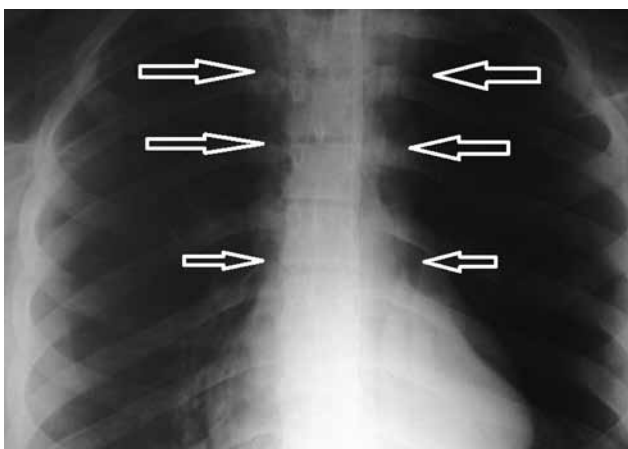
Because of the rapid progression of respiratory distress and severe hypoxemia, endotracheal

intubation and mechanical ventilation were performed.

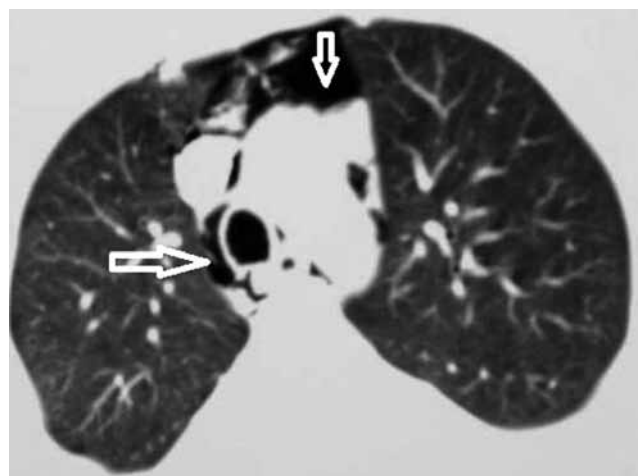The patient was successfully weaned from the ventilator on his second day in the hospital, and his symptoms improved with conservative management, which was comprised of bed rest, analgesics, and intravenous fluid therapy. Since the patient's clinical condition had stabilized, he was discharged from hospital on the fifth day.

## DISCUSSION

Use of crack cocaine has reached near epidemic proportions in recent years. After smoking crack, many users experience chest pain or dyspnea, prompting them to seek medical attention. The development of pneumomediastinum following cocaine smoking has been previously described.<sup>[1]</sup> An increase in intraalveolar pressure causes rupture of the alveoli, with air escaping into the interstitial tissues. The air may dissect centrally along the bronchovascular sheaths into the mediastinum and expand into to the fascial planes of the neck. Decompression of the pneumomediastinum through the mediastinal parietal pleura results in pneumothorax,<sup>[2]</sup> which can also be caused by the peripheral dissection of air with a rupture of pleural blebs. This mechanism is common to other causes of spontaneous pneumomediastinum, including straining at defecation, blunt trauma, asthma, emesis, parturition, and athletic competition as well as heroin, marijuana, and nitrous oxide abuse.<sup>[3]</sup> Possible physiological mechanisms include the direct and immunologically-mediated effects of cocaine-associated adulterants on the lungs. Smoke and its toxic combustion byproducts have been shown to



**Figure 1.** Posteroanterior chest X-ray showing the linear detachment along the mediastinal border and vertical air densities outlining the trachea (arrows). Subcutaneous emphysema was detected in the bilateral neck and suprascapular regions.



**Figure 2.** Thoracic computed tomography scan showing the free gas within the mediastinum anterior to the aortic arch and the peritracheal and periesophageal areas (arrows).

reduce mucociliary clearance and cause bronchiolar damage in laboratory animals.<sup>[4]</sup> This could cause atelectasis due to the accumulation of secretions in the bronchioles that were narrowed by the mucosal swelling. Respiratory excursion, which could also contribute to atelectasis, could be limited by pain. Damage to the alveolar capillary membrane by smoke and other noxious gases may be followed by the transudation of fluid, resulting in diffuse or localized areas of pulmonary edema.<sup>[5]</sup> Others have reported cases of air space disease associated with cocaine abuse. For example, Restrepo et al.<sup>[6]</sup> found that bilateral air-space opacification could be temporally associated with cocaine smoking. In their study, diffuse alveolar hemorrhage was found at the open lung biopsy. The authors postulated that the alveolar hemorrhage might have been due to vasoconstriction, resulting in anoxic cell damage, or it could have been due to the direct toxic effect of cocaine on the alveolar lining cells, with subsequent involvement of the basement membrane. Of particular concern in that report were the cardiovascular complications, including arrhythmia, myocardial infarction or ischemia, myocarditis, and sudden death. However, we did not observe any cardiac complications in our patient.

Other complications that have been described include subarachnoid hemorrhage, obstetric complications, sexual dysfunction, and a variety of psychiatric disorders.<sup>[7]</sup>

Rapid diagnosis of pneumomediastinum is important because it is a potentially lethal condition. Serious complications such as tension and bilateral pneumothorax as well as tension pneumomediastinum, which causes cardiac compression and reduces cardiac output, have also been reported.<sup>[8]</sup> If the condition is serious, cyanosis, collapse, dyspnea, and insufficient cardiac filling related to air compression on the big vessels are present, and treatment should be started immediately, with mediastinal needle aspiration, a mediastinotomy, a tracheostomy or an emergency thoracotomy being the most appropriate options. However, rapid surgical treatment is needed for tracheobronchial and esophageal perforations.

Cocaine-induced pneumomediastinum is generally a benign condition, and no reports of serious complications in patients with spontaneous pneumomediastinum in the absence of underlying disease exist in the recent literature. The importance of our case is the resulting serious complications and respiratory failure due to cocaine smoking. As far as we know, this is the first such incident to be reported in national literature. This serves to point out the potential severe respiratory complications

of cocaine abuse with spontaneous pneumomediastinum. We believe that a short observation period combined with outpatient follow-up is appropriate in the majority of patients. Since invasive procedures have a low yield, they should only be undertaken based on a high degree of clinical suspicion for esophageal rupture or bronchial tree laceration. Contrast esophageal studies and flexible endoscopic studies have few risks but are not recommended to be used as a routine diagnosis method; however, they should be considered as possible methods for further analysis in suspicious cases. In our case, esophagography and endoscopic examination were not conducted because esophageal rupture was not clinically considered.

Moreover, the high frequency of esophageal rupture associated with illicit inhalational drug use also requires that physicians be aware of a patient's clinical and natural history. Treatment should consist of outpatient rest, reassurance, specific discharge instructions, follow-up, and analgesics.<sup>[8]</sup>

In conclusion, spontaneous mediastinum due to crack abuse usually does not require hospitalization. Yet, we observed severe acute respiratory failure and had to treat our patient in the emergency room. We believe that it is important to obtain a thorough history and perform a detailed but rapid physical examination for patients who have used cocaine.

#### **Declaration of conflicting interests**

The authors declared no conflicts of interest with respect to the authorship and/or publication of this article.

#### **Funding**

The authors received no financial support for the research and/or authorship of this article.

#### **REFERENCES**

1. Alnas M, Altayeh A, Zaman M. Clinical course and outcome of cocaine-induced pneumomediastinum. *Am J Med Sci* 2010;339:65-7.
2. Uva JL. Spontaneous pneumothoraces, pneumomediastinum, and pneumoperitoneum: consequences of smoking crack cocaine. *Pediatr Emerg Care* 1997;13:24-6.
3. Işık AF, Kurnaz M, Çobanoğlu U. Pneumomediastinum after blunt trauma to the eye. *Turk Gogus Kalp Dama* 2005;13:177-8.
4. Liao JP, Chi CH, Li HC, Tang XY. Effects of N-acetylcysteine on Clara cells in rats with cigarette smoke exposure. *Chin Med J (Engl)* 2010;123:412-7.
5. Beall CV, Baker CR Jr, Griswold JA, Little AD, Little GH, Behal FJ. The effect of smoke inhalation on bradykinin metabolism by the perfused and ventilated rat lung. *J Burn Care Rehabil* 1995;16:487-95.

6. Restrepo CS, Carrillo JA, Martínez S, Ojeda P, Rivera AL, Hatta A. Pulmonary complications from cocaine and cocaine-based substances: imaging manifestations. *Radiographics* 2007;27:941-56.
7. Lingamfelter DC, Knight LD. Sudden death from massive gastrointestinal hemorrhage associated with crack cocaine use: case report and review of the literature. *Am J Forensic Med Pathol* 2010;31:98-9.
8. Jougon JB, Ballester M, Delcambre F, Mac Bride T, Dromer CE, Velly JF. Assessment of spontaneous pneumomediastinum: experience with 12 patients. *Ann Thorac Surg* 2003;75:1711-4.