

Surgical treatment of chronic mesenteric ischemia with splenic artery-to-superior mesenteric artery bypass: a case report

Splenik arterden superior mezenterik artere baypas ile kronik mezenterik iskeminin cerrahi tedavisi: Olgu sunumu

Yunus Nazlı,¹ Necmettin Çolak,¹ Hüseyin Şahin,² Kayıhan Akın,³ İsmail Olgun Akkaya,¹ Mikdat Bozer,² Ömer Çakır¹

¹Department of Cardiovascular Surgery, Medicine Faculty of Fatih University, Ankara, Turkey

²Department of General Surgery, Medicine Faculty of Fatih University, Ankara, Turkey

³Department of Radiology, Medicine Faculty of Fatih University, Ankara, Turkey

Chronic mesenteric ischemia is a rare, but important cause of abdominal pain with high mortality and morbidity rates. Postprandial abdominal pain, sitophobia and weight loss are the important clinical signs and symptoms. The main goal of the treatment is to relieve patient's symptoms by restoration of intestinal perfusion and to prevent intestinal necrosis. Doppler ultrasound, computed tomography angiography, magnetic resonance angiography and conventional angiography are used in the diagnosis of chronic mesenteric ischemia. Surgical or endovascular interventions as well as medical therapy may be used in the treatment of chronic mesenteric ischemia. In this article, we present a 60-year-old female case of chronic mesenteric ischemia with inferior and superior mesenteric artery occlusion, who was successfully treated with splenic artery-to-superior mesenteric artery bypass surgery.

Key words: Bypass; chronic mesenteric ischemia; splenic artery; superior mesenteric artery.

Chronic mesenteric ischemia (CMI) is a rare but important cause of abdominal pain^[1] that accounts for 5% of all intestinal ischemic events.^[2] It generally results from the hemodynamically significant proximal atherosclerotic lesions of three main splanchnic arteries (severe narrowing or obstruction).^[3] The typical signs and symptoms of CMI include postprandial abdominal pain, weight loss, and sitophobia,^[1,4] and medical therapy and surgical or endovascular interventions may be used in the treatment of these patients. In

Kronik mezenterik iskemi, yüksek mortalite ve morbidite oranları ile karın ağrısının nadir, fakat önemli bir nedendir. Yemek sonrası karın ağrısı, sitofobi ve kilo kaybı önemli klinik bulgu ve belirtilerdir. Tedavinin esas amacı, intestinal perfüzyonu yeniden sağlayarak hastanın belirtilerini ortadan kaldırmak ve bağırsak nekrozlarını önlemektir. Kronik mezenterik iskeminin tanısında Doppler ultrasonografi, bilgisayarlı tomografi anjiyografi, manyetik rezonans anjiyografi ve konvansiyonel anjiyografi kullanılır. Kronik mezenterik iskeminin tedavisinde medikal tedavinin yanı sıra cerrahi tedavi veya endovasküler girişimler de kullanılabilir. Bu yazıda inferior ve superior mezenterik arteri tıkalı kronik mezenterik iskemisi olan ve splenic arterden superior mezenterik artere baypas ameliyatı ile başarılı şekilde tedavi edilen 60 yaşında bir kadın olgu sunuldu.

Anahtar sözcükler: Baypas; kronik mezenterik iskemi; splenic arter; superior mezenterik arter.

this case report, we describe a case of CMI treated successfully with splenic artery-to-superior mesenteric artery bypass surgery.

CASE REPORT

A 60-year-old female was admitted to the hospital with symptoms of postprandial abdominal pain and weight loss. She had complained of this pain for four years, but her symptoms had significantly increased the four months prior to admission. She had also



Available online at
www.tgkdc.dergisi.org
doi: 10.5606/tgkdc.dergisi.2013.5292
QR (Quick Response) Code

Received: February 3, 2011 Accepted: June 21, 2011

Correspondence: Yunus Nazlı, M.D. Fatih Üniversitesi Tıp Fakültesi Kalp ve Damar Cerrahisi Anabilim Dalı, 06510 Emek, Ankara, Turkey.

Tel: +90 312 - 203 51 86 e-mail: yunusnazli@gmail.com

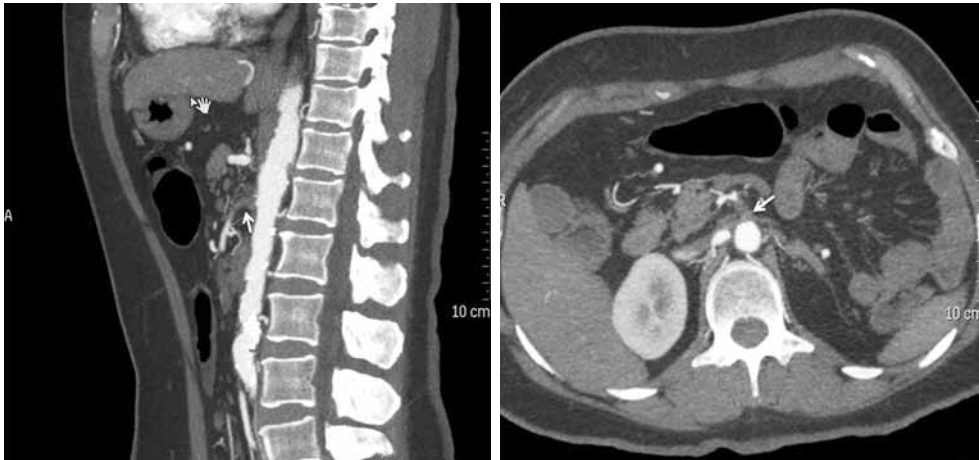

Figure 1. Computed tomography angiography demonstrates the occlusion of the origin of the superior mesenteric artery. The arrows indicate the occlusion.

lost about 15 kg in weight over the previous four years. The patient had a history of hyperlipidemia, diabetes mellitus (DM), and hypertension and had also undergone a left nephrectomy. Her vital signs at presentation were blood pressure 130/70 mmHg, heart rate 78 beats/min, and temperature 37.2 °C. An abdominal examination revealed generalized tenderness and minimal muscular defense, but rebound tenderness was not present. No abnormality was noted in the hematologic profile, renal and liver function, serum electrolytes, or coagulation profile. Multislice computed tomography angiography revealed occlusion at the origin and proximal portion of the superior mesenteric artery (SMA) and inferior mesenteric artery (IMA) (Figures 1). Digital subtraction angiography also detected the proximal occlusion of the SMA and IMA. Additionally, there was direct collateral drainage

from the gastroduodenal artery to the SMA, and the artery was being perfused because of this. The SMA could not be selectively catheterized, and endovascular intervention could not be performed. Angiography showed that the celiac artery and its branches were patent with normal calibration. Enoxaparin sodium (1 mg/kg twice daily, subcutaneous) treatment was administered to the patient, but because her symptoms continued with same severity in spite of this treatment, surgical treatment was recommended.

The patient was taken to the operating room, and the supraceliac aorta was accessed through the lesser omental sac. We decided to use the splenic artery for the SMA bypass since splenic perfusion was supported from the short gastric arteries. The celiac and splenic artery were explored, and the splenic artery was mobilized from the origin to the splenic hilum over the upper edge of the pancreas. The pancreatic branches of the splenic artery were then ligated and divided. Next, the SMA was explored from the posterior of the pancreas, and it was dissected through the distal portion in order to place a vascular clamp. There was no pulsation in the SMA. Heparin (75 IU/kg) was injected intravenously, and the splenic artery was ligated and transected near the splenic hilum. A longitudinal arteriotomy was then performed on the SMA, and there was backflow from the distal portion of the artery. In our case, the proximal part of the SMA was occluded. Therefore, a vascular clamp was placed only on the distal portion, and the splenic artery was anastomosed end-to-side to the SMA (Figure 2). The spleno-mesenteric bypass was checked intraoperatively by palpation of arterial pulsation, and the SMA pulse was present. The splenic perfusion was normal, so there was no need for a splenectomy.

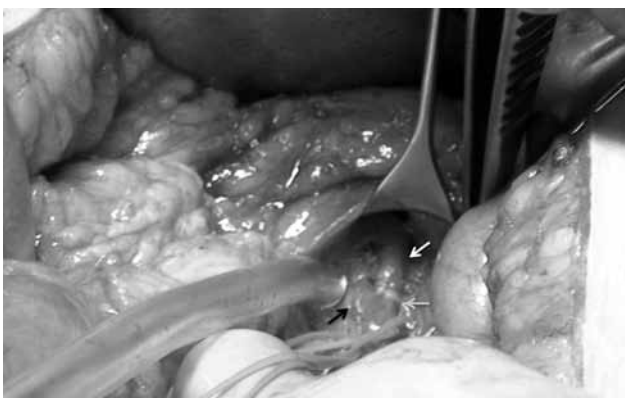

Figure 2. The operative photograph shows the splenic artery-to-superior mesenteric artery anastomosis. The white arrow indicates the splenic artery, the black arrow indicates the superior mesenteric artery, and the gray arrows indicate the anastomosis.

Anticoagulation therapy was continued during the early postoperative periods, and the patient’s recovery was uneventful. The postprandial abdominal pain of the patient regressed. A control computed tomography (CT) angiography performed on the postoperative fourth day showed that the spleno-SMA bypass was patent (Figures 3), and the patient was discharged without any symptoms on the same day. At the six-month follow-up examination, the patient had no complaints and had gained weight.

DISCUSSION

Chronic mesenteric ischemia can be defined as chronic postprandial abdominal pain due to a decrease in intestinal blood flow. Although CMI is rarely seen, it should be treated as soon as possible after diagnosis since the mortality and morbidity rates associated with it are high.^[5-7] If CMI is left untreated, it can result in severe malnutrition and may progress to acute intestinal ischemia resulting in bowel necrosis and death. Mesenteric circulation consists of three principal arterial circulations in the celiac artery, SMA, and IMA, with the three splanchnic arteries being connected via multiple collateral pathways. Chronic mesenteric ischemia usually results from a long-standing atherosclerotic lesion in two or more main splanchnic arteries.^[3] In these cases, the rich vascular collaterals develop in the chronic period, and patients may have no symptoms.^[2] Symptoms generally appear when two or more splanchnic arteries are affected. Classic symptoms include postprandial abdominal pain, sitophobia, and

weight loss; however, other nonspecific symptoms such as diarrhea, nausea, and vomiting may occur.^[3] In our case, the SMA and IMA were occluded.

The gold standard diagnostic procedure for CMI remains conventional angiography (CA) in clinical practice. Alternatively, CT angiography, magnetic resonance (MR) angiography, or Doppler USG can be used as noninvasive diagnostic procedures.^[2] In our patient, the diagnosis was made by CT angiography before performing CA. Conventional angiography was performed in the same session to apply endovascular intervention.

The aim of the treatment is to eliminate symptoms such as postprandial abdominal pain and weight loss and prevent the development of acute intestinal ischemia with the restoration of intestinal perfusion. Therapeutic options for patients with CMI include medical therapy along with surgical and endovascular interventions. Endovascular interventions are treatment modalities that can be easily performed with low morbidity and short hospitalization periods.^[5-8] Nevertheless, the long-term results of surgical bypass procedures are better than for endovascular interventions.^[5,7-10] We decided to perform an endovascular intervention in our case because it is a less invasive modality. However, in our case, a guide wire was not able to pass through the occlusion of the SMA, so bypass surgery was necessary.

Surgical revascularization for the treatment of CMI uses different operative techniques, for example an

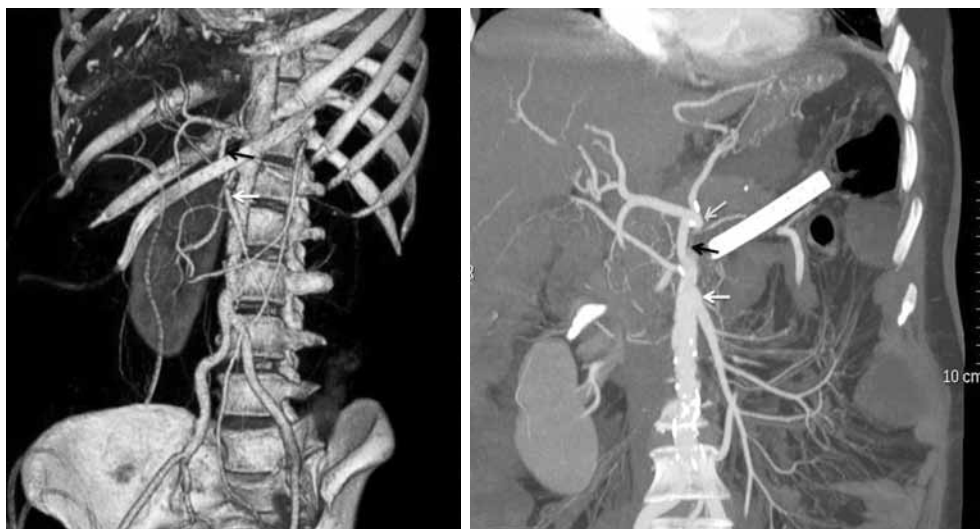


Figure 3. The postoperative computed tomography angiography shows the patent splenic artery-to-superior mesenteric artery bypass. The white arrow indicates the superior mesenteric artery, the black arrow indicates the splenic artery, and the gray arrow indicates the celiac artery. White arrow: Superior mesenteric artery; Black arrow: Splenic artery; Gray arrow: Celiac artery.

endarterectomy, vessel reimplantation, or mesenteric bypass.^[1,11] In general, antegrade mesenteric bypass grafting may be performed from either the supraceliac aorta or distal thoracic aorta and retrograde grafting from either the infrarenal aorta or common iliac artery. A prosthetic graft or saphenous veins are commonly used to bypass the SMA. Superficial femoral vein or basilic vein grafts can be also used for the mesenteric bypass in rare cases.^[1,10,11] In addition, a superior mesenteric artery bypass with the splenic artery is another antegrade revascularization technique for the surgical treatment of CMI.^[6] The celiac artery should be patent to perform a splenic artery-to-SMA bypass. The results of antegrade bypass methods have been superior to those for retrograde bypass methods.^[5,6,8,12] Moreover, the splenic artery is an arterial conduit.

The risk of anastomotic stenosis is higher with an autogenic vein or prosthetic graft rather than with a splenic artery due to the requirement of double (proximal and distal) anastomosis in mesenteric bypass surgery. Moreover, the risk of anastomotic stenosis is less with the use of the splenic artery due to the necessity of only a single anastomosis. On the other hand, when these grafts are used for the SMA bypass, some complications may occur due to the cross-clamping of the aorta, such as declamping hypotension, which triggers cardiac ischemia, and aortic tissue damage. However, the use of the splenic artery can lead to splenic perfusion defects, which can result in the need for a splenectomy.^[5,6] We preferred to use the splenic artery for the advantages of the single anastomosis and arterial conduit. Additionally, we performed a splenic artery-to-SMA bypass because splenic perfusion was supported from the short gastric arteries.

In conclusion, surgical bypass procedures and endovascular interventions provide adequate intestinal perfusion in the treatment of patients with CMI; however, the long-term results of surgical bypass procedures are better. In our case, we performed antegrade mesenteric bypass surgery via the splenic artery. The advantages of this surgical method are that there is no need for a prosthetic, autogenic vein graft and that cross-clamping of the aorta is unnecessary since the antegrade bypass method uses an arterial conduit.

Declaration of conflicting interests

The authors declared no conflicts of interest with respect to the authorship and/or publication of this article.

Funding

The authors received no financial support for the research and/or authorship of this article.

REFERENCES

1. Sreenarasimhaiah J. Chronic mesenteric ischemia. *Curr Treat Options Gastroenterol* 2007;10:3-9.
2. Zacho HD, Abrahamsen J. Chronic intestinal ischaemia: diagnosis. *Clin Physiol Funct Imaging* 2008;28:71-5.
3. Soga Y, Yokoi H, Iwabuchi M, Nobuyoshi M. Endovascular treatment of chronic mesenteric ischemia. *Circ J* 2008;72:1198-200.
4. Geroulakos G, Tober JC, Anderson L, Smead WL. Antegrade visceral revascularisation via a thoracoabdominal approach for chronic mesenteric ischaemia. *Eur J Vasc Endovasc Surg* 1999;17:56-9.
5. Özer MT, Uzar Aİ, Özal E, Menteş Ö, Bingöl H, Harlak A ve ark. Superior mesenteric artery obstruction and treatment with mesenteroiliac bypass. *Anatol J Clin Investig* 2009;3:148-50.
6. Mukherjee D, Hendershot KM. Splenic artery-to-superior mesenteric artery bypass for chronic mesenteric ischemia--a case report. *Vasc Endovascular Surg* 2004;38:465-8.
7. Emrecaan B, Önem G, Baltalarlı A. İntestinal anjina: Karın ağrısının ender bir nedeni. *Turk Gogus Kalp Dama* 2008;16:269-73.
8. Inoue Y, Sugano N, Iwai T. Long-term results of aorta-superior mesenteric artery bypass using a new route. *Surg Today* 2004;34:658-61.
9. Loffroy R, Guiu B, Cercueil JP, Krausé D. Chronic mesenteric ischemia: efficacy and outcome of endovascular therapy. *Abdom Imaging* 2010;35:306-14. doi: 10.1007/s00261-009-9515-x.
10. Davies RS, Wall ML, Silverman SH, Simms MH, Vohra RK, Bradbury AW, et al. Surgical versus endovascular reconstruction for chronic mesenteric ischemia: a contemporary UK series. *Vasc Endovascular Surg* 2009;43:157-64. doi: 10.1177/1538574408328665.
11. Jimenez JG, Huber TS, Ozaki CK, Flynn TC, Berceli SA, Lee WA, et al. Durability of antegrade synthetic aortomesenteric bypass for chronic mesenteric ischemia. *J Vasc Surg* 2002;35:1078-84.
12. Woon CY, Tay KH, Tan SG. Delayed diagnosis of chronic mesenteric ischaemia. *Singapore Med J* 2007;48:e9-e12.