

## Interventional therapy in high risk mitral regurgitation: new MitraClip applications in Turkey

*Yüksek riskli mitral yetersizliğinde perkütan girişimsel tedavisi:  
Türkiye'deki yeni MitraClip uygulamaları*

**Sinan Dağdelen, Ahmet Akyol, Seden Erten Çelik**

Department of Cardiology, Acibadem University, Faculty of Medicine, İstanbul, Turkey

Percutaneous mitral valve repair systems are minimally invasive, percutaneous, catheter-based devices designed to treat severe mitral regurgitation (MR). Implantation using the MitraClip device (Abbott Vascular, Santa Clara, CA, USA) increases the options for selected patients with functional/degenerative MR, reduces the symptoms of heart failure, and improves quality of life (QoL).<sup>[1]</sup> In the landmark Endovascular Valve Edge-to-Edge Repair Study (EVEREST II),<sup>[2]</sup> the MitraClip met its primary safety and efficacy endpoints, demonstrating its potential to provide meaningful clinical and QoL benefits versus conventional surgery. The MitraClip offers a superior safety profile along with non-inferiority and is efficacious in patients who are ineligible for surgery and those who are at high risk. There are many reasons that make a patient a good candidate for percutaneous mitral valve repair, including high surgical risk, older patient age, previous cardiac surgery, severe lung disease, and chronic renal failure. Of course, this depends, on whether there is conformability of the mitral valve structure. However, we still have not identified the optimal selection criteria needed in order to exclude selection bias in prospective studies. Nevertheless, I believe that the use of long-term prospective studies and more advanced technology will enable us to develop this criteria soon.

In our clinic, we have been using the MitraClip procedure since April 2012, making it the second

health center to employ this procedure in Turkey. Thus far, we have successfully utilized the MitraClip in six patients (five males and one female; mean age 66±10 years. Four of these had undergone previous open heart surgery, five had coronary artery disease (CAD), two had diabetes mellitus (DM), two had hypertension, and two had high creatinine levels in their history. The patients' New York Heart Association (NYHA) class was 3.2±1.0, the left ventricular ejection fraction (LVED) was 30±11%, and the pulmonary arterial pressure measured 53±5 mmHg. In addition, all of these patients had functional grade 4 MR.

The mitral anatomic structure and criteria for the MitraClip procedure were first evaluated by transesophageal echocardiography (TEE), and all of the patients consulted with a cardiac surgeon. They were then accepted as candidates for the MitraClip procedure based on high surgical risk. The EVEREST I criteria<sup>[3]</sup> (i.e., a mitral valve orifice area of <2.0 cm<sup>2</sup>, extensive prolapse of flail leaflets (prolapse width of >25 mm, and flail gap of >20 mm) was only considered as a reference parameter for exclusion.

Percutaneous MitraClip implantation was performed under general anesthesia with TEE and fluoroscopic guidance.<sup>[3]</sup> After transeptal puncture, a 24-French (24-F) catheter-based delivery system was inserted via the femoral vein in the left atrium and then the MitraClip was advanced through the catheter and crossed between the mitral valve, where it was

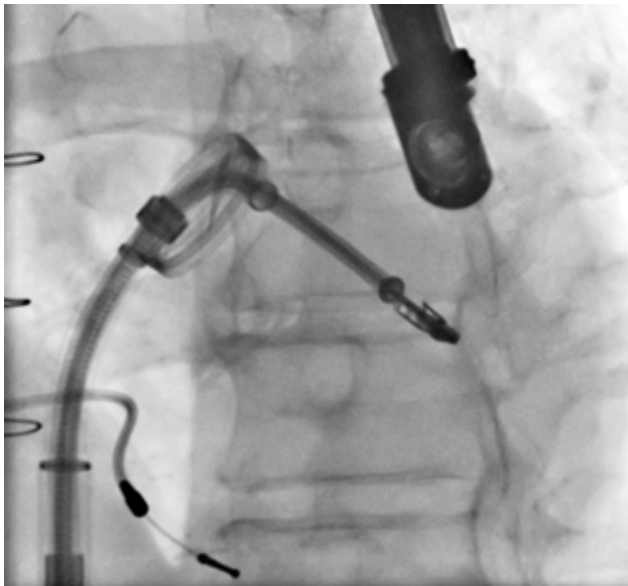


Available online at  
www.tgkdc.dergisi.org  
doi: 10.5606/tgkdc.dergisi.2013.8434  
QR (Quick Response) Code

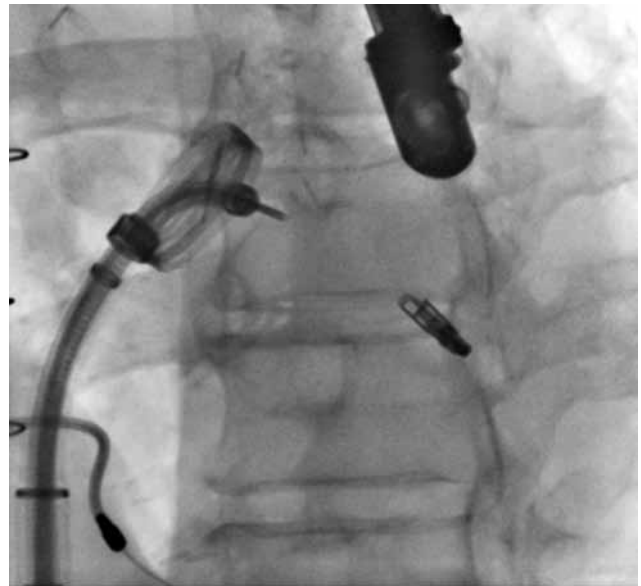
Received: February 28, 2013 Accepted: March 04, 2013

Correspondence: Sinan Dağdelen, M.D. Acibadem Üniversitesi Kardiyoloji Anabilim Dalı, 34848 Maltepe, İstanbul, Turkey.

Tel: +90 505 - 252 58 26 e-mail: sinandagdelen@hotmail.com



**Figure 1.** Positioning of the MitraClip at the edge points of the A2-P2 segments.



**Figure 2.** Fluoroscopic image of the MitraClip after successful detachment.

then aligned with the maximum jet originating from the regurgitant lesion (Figures 1 and 2). Grasping the edges of the mitral leaflets resulted in a double mitral orifice and a significant reduction in the MR. Onsite procedural success was defined as favorable implantation of the MitraClip with a reduction in the MR to  $\leq 2+$ .<sup>[4]</sup> We implanted one clip for each of the patients. Our procedural time ranged from one and a half to four hours, and all cases were completed without any cardiac and vascular complications. The patients were kept in the hospital for three to five days and then were discharged uneventfully.

#### **Declaration of conflicting interests**

The authors declared no conflicts of interest with respect to the authorship and/or publication of this article.

#### **Funding**

The authors received no financial support for the research and/or authorship of this article.

#### **REFERENCES**

1. Feldman T, Kar S, Rinaldi M, Fail P, Hermiller J, Smalling R, et al. Percutaneous mitral repair with the MitraClip system: safety and midterm durability in the initial EVEREST (Endovascular Valve Edge-to-Edge REpair Study) cohort. *J Am Coll Cardiol* 2009;54:686-94. doi: 10.1016/j.jacc.2009.03.077.
2. Whitlow PL, Feldman T, Pedersen WR, Lim DS, Kipperman R, Smalling R, et al. Acute and 12-month results with catheter-based mitral valve leaflet repair: the EVEREST II (Endovascular Valve Edge-to-Edge Repair) High Risk Study. *J Am Coll Cardiol* 2012;59:130-9. doi: 10.1016/j.jacc.2011.08.067.
3. Feldman T, Wasserman HS, Herrmann HC, Gray W, Block PC, Whitlow P, et al. Percutaneous mitral valve repair using the edge-to-edge technique: six-month results of the EVEREST Phase I Clinical Trial. *J Am Coll Cardiol* 2005;46:2134-40.
4. Sürder D, Pedrazzini G, Gaemperli O, Biaggi P, Felix C, Rufibach K, et al. Predictors for efficacy of percutaneous mitral valve repair using the MitraClip system: the results of the MitraSwiss registry. *Heart* 2013. [Epub ahead of print]