

## Total artificial heart for bridge to cardiac transplantation: first patient at home in Turkey

*Kalp nakline köprüleme amacıyla total yapay kalp: Türkiye’de evinde yaşayan ilk hasta*

**Deniz Süha Küçükaksu, Erman Pektok, Nurcan Arat, Ömer Yıldız, Zümrüt Tuba Demirozu,  
Ferah Ece, Çavlan Çiftçi, Osman Bayındır, Nuran Yazıcıoğlu**

Heart Transplantation and Mechanical Support Systems Division, Florence Nightingale Hospital, İstanbul, Turkey

Total artificial heart (TAH) is a mechanical circulatory support system used for keeping the patients with end-stage heart failure alive until cardiac transplantation. In this article, we aimed to present our experience with the first patient who was discharged from the hospital after TAH implantation and scheduled for cardiac transplantation in Turkey. A 45-year-old male patient who received medical therapy for dilated cardiomyopathy was implanted a TAH until an appropriate donor was found for cardiac transplantation due to severe biventricular heart failure and large body size of the patient. He was discharged from the hospital at 60 days postoperatively with the Freedom Driver and has been still waiting for an appropriate donor for cardiac transplantation for two years at home. SynCardia TAH is an effective and safe therapeutic system, providing a high cardiac output (~10 L/min), particularly in patients with a large body surface area and chest cavity. Freedom Driver also enables patients to live at home safely.

**Key words:** Bridge to cardiac transplantation; heart failure; mechanical circulatory support; total artificial heart.

The implantation of a total artificial heart (TAH) has been a valuable therapeutic option for those who suffer from severe end-stage heart failure (ESHF) as it provides an appropriate bridge to transplantation (BTT).<sup>[1-6]</sup> The SynCardia temporary TAH (SynCardia Systems Inc, Tucson, AZ, USA) is a pneumatic pulsatile blood pump that is implanted into the pericardial

Total yapay kalp (TAH), son evre kalp yetmezliğindeki hastaların kalp nakline kadar hayatta kalmalarını sağlayan bir mekanik dolaşım destek sistemidir. Bu yazıda, Türkiye’de ilk kez TAH implante edildikten sonra evine giden ve kalp nakli bekleyen olgudan edindiğimiz deneyimimizi sunmayı amaçladık. On yıldır dilate kardiyomyopati nedeni ile tedavi edilen 45 yaşındaki erkek hastaya, ciddi biventriküler yetmezlik ve büyük vücut ölçüleri nedeniyle kalp nakli için uygun donör bulunana kadar TAH implantasyonu gerçekleştirildi. Ameliyat sonrası 60. günde Freedom Driver ile evine gönderilen hasta, evinde iki yıldır nakil için uygun donör beklemektedir. SynCardia TAH, sağladığı yüksek debiyle (~10 L/dk.), özellikle vücut yüzey alanı ve göğüs boşluğu geniş hastalarda etkin ve güvenilir bir tedavi yöntemidir. Ayrıca, Freedom driver hastaların ev ortamında güvenle yaşamalarına olanak sağlar.

**Anahtar sözcükler:** Kalp nakline köprüleme; kalp yetmezliği; mekanik dolaşım desteği; total yapay kalp.

cavity which replaces both ventricles and all four heart valves.<sup>[3]</sup> The driver console together with the two separate air tubes and four-layer diaphragm can produce an output of up to 9 L/min.<sup>[7]</sup>

We present our experience with an ESHF patient who had a TAH for BTT.<sup>[8]</sup> To our knowledge, this is the first case in Turkey to be discharged from hospital



Available online at  
www.tgkdc.dergisi.org  
doi: 10.5606/tgkdc.dergisi.2013.8155  
QR (Quick Response) Code

Received: January 15, 2013 Accepted: May 10, 2013

Correspondence: Erman Pektok, M.D. Florence Nightingale Hastanesi, Kalp Nakli ve Mekanik Destek Sistemleri Bölümü, 34381 Şişli, İstanbul, Turkey.

Tel: +90 532 - 715 45 40 e-mail: epektok@hotmail.com

who is currently waiting for a heart transplantation (HTx) at home with a TAH.<sup>[8]</sup>

## CASE REPORT

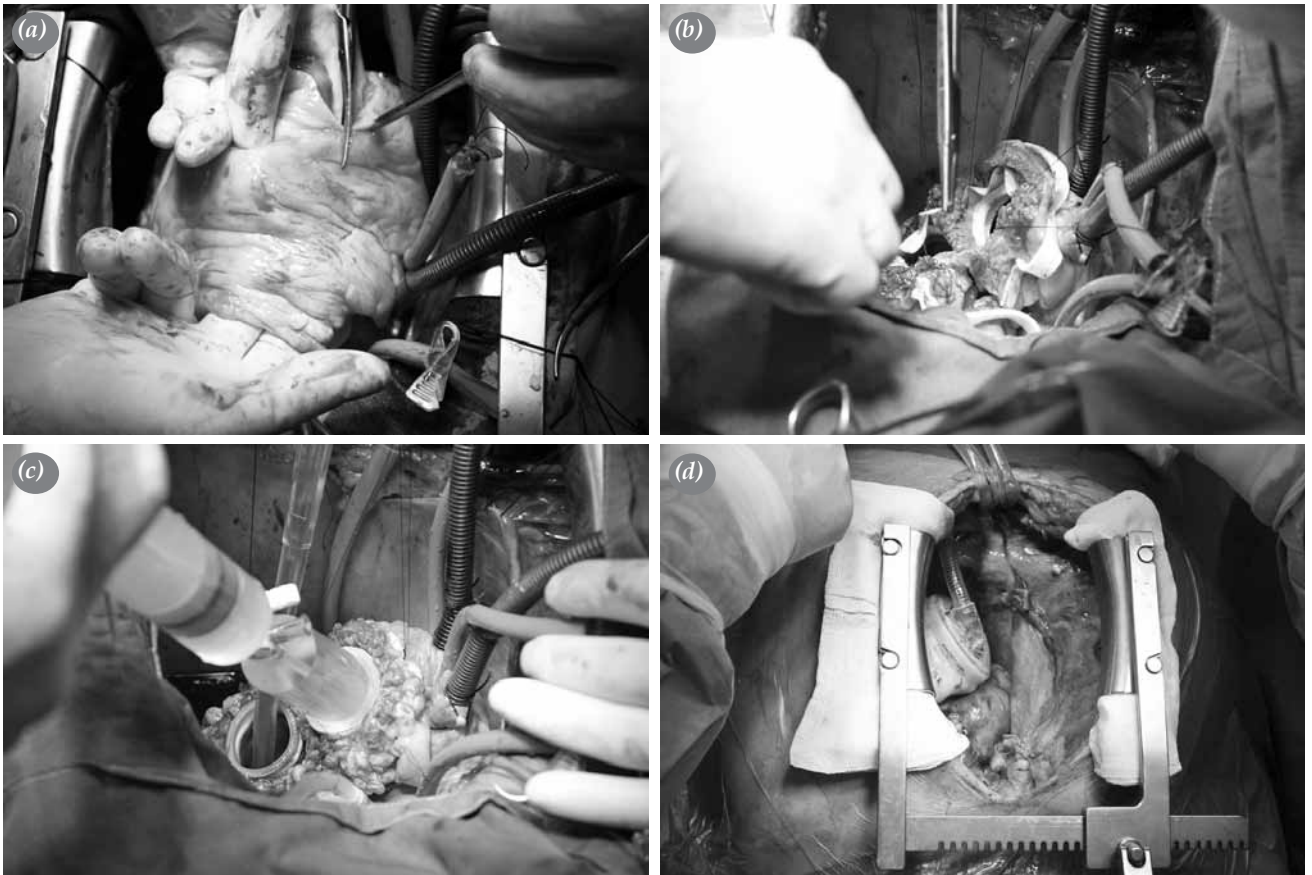
Our patient was a 45-year-old male with a 10-year history of idiopathic dilated cardiomyopathy. A cardiac resynchronization therapy-defibrillator (CRT-D) was implanted in November 2009. Between October 2009 and January 2011, the patient was hospitalized 11 times because of decompensated heart failure (HF), and he received intravenous inotrope and diuretic therapy along with ultrafiltration. Furthermore, in January 2011, he had an episode of acute renal failure which was resolved by medical therapy. When the patient was referred to our center in February 2011, he had limited functional capacity (NYHA Class IV) and dyspnea on mild exertion under optimal medical therapy. Transthoracic echocardiography (TTE) showed a left ventricular (LV) ejection fraction of 20%, a LV end-diastolic diameter of 84 mm, a LV end-systolic diameter of 72 mm, a dilated/spherical right ventricle (RV), severe mitral regurgitation, severe tricuspid regurgitation, and a systolic pulmonary artery pressure (PAP) of 70 mmHg. In addition, the patient also underwent cardiac catheterization which revealed a cardiac index of 1.9 L/min/m<sup>2</sup>, a right atrial pressure (RAP) of 18 mmHg, a systemic arterial pressure (SAP) of 106/75-82 mmHg, a PAP of 64/41-49 mmHg, a pulmonary capillary wedge pressure (PCWP) of 34 mmHg, a pulmonary vascular resistance (PVR) of 3.26 woods, and an LV and RV systolic work index of 13.6 and 8.1 gm/m<sup>2</sup>/beat, respectively. Since the transpulmonary gradient and the PVR were within acceptable limits, a pulmonary reversibility test was not performed. The patient was then evaluated by the institutional HF board and put on the waiting list for a HTx.

One week later on his routine control visit, the patient presented with hypotension (90/60 mmHg, brachial) and again showed signs of decompensation (e.g., dyspnea on exertion, orthopnea, hepatomegaly, and pretibial edema); thus, he was admitted to the intensive care unit (ICU) for more intravenous inotropic and diuretic therapy. Furthermore, the Turkish National Organ Sharing System was also alerted to the need for an emergency donor heart. Despite 10 days of inotropic support with increasing doses, the patient's hemodynamic status and symptoms did not recover as his pro-brain natriuretic peptide (ProBNP) level remained stable at around 8500 pg/mL, and his liver functions were gradually elevated [Interagency Registry

for Mechanically Assisted Circulatory Support (Intermacs) Level 2]. The patient was reevaluated by the HF board and a decision was made to pursue mechanical circulatory support (MCS) as a BTT for the impending cardiogenic shock. Taking into account the patient's large body size and the need for biventricular support, the temporary TAH was implanted on March 21, 2011.

## Surgical technique

Under general anesthesia, a median sternotomy was performed, and the pericardium was opened. Aortic arterial and bicaval venous canulae were inserted after heparin administration. Diastolic cardiac arrest was then achieved by antegrade cardioplegia after aortic cross-clamping, and resection of the ventricles was performed starting from the apex of the heart, which was resected transversely so that both ventricles were opened. Next, the main pulmonary artery was transected immediately above the valve, and the RV was cut at length, starting from the apex towards the pulmonary artery via the RV outflow tract (Figure 1a). Since the RV was fully opened, the RV free wall was dissected completely, leaving a slim rim around the tricuspid annulus. Similarly, the aorta was transected at the level of the sinotubular junction, and the LV was cut at length from the apex towards the aorta, staying away from the mitral annulus. Then the LV free wall and the septum were cut, excising both ventricles en bloc, and leaving both atria and mitral and tricuspid annuli in situ. The next step was to ligate the left atrial appendix to prevent future complications, such as thrombus formation and invagination towards the left inflow valve, and the patent foramen ovale (PFO) was sutured to prevent an interatrial shunt. In addition, both annuli were reinforced with separate Teflon strips and 3/0 prolene sutures (Figure 1b). The left and right quick connectors of the TAH were trimmed properly, everted, and inserted into the corresponding atrium and then sewn onto the left and right atrial cuffs in order to prepare the inflow connection sites (Figure 1b). As both cuffs were sewn, hemostasis control was performed using a special control tool connected to the syringe, provided by the manufacturer (Figure 1c). The ventricles were then brought into the area to measure the length of the preclotted outflow grafts. As these were being properly cut, they were anastomosed to the pulmonary artery and the ascending aorta in an end-to-end fashion. Hemostasis control was performed using fibrin and biological glue for both outflow grafts. Next, the air tubes of the ventricles



**Figure 1.** (a) Longitudinal cut of the right ventricle from the apex towards the outflow tract/pulmonary artery. (b) Reinforcement of the tricuspid and mitral annuli using Teflon strips and suturing of the right quick connector to the tricuspid annulus. Please note that the quick connector is everted and inserted into the atrium to ensure a smooth suturing line. (c) Control of the right cuff using a 50 mL syringe and a special connector. Lack of any leakage from the suture line must be assured at this stage. (d) Total artificial heart in the pericardial space replacing the native heart.

were taken out from the left upper quadrant, well away from the costal arch, and the LV and RV of the TAH were firmly connected to the inflow (atrial cuffs) and outflow (pulmonary and aortic grafts) sites after de-airing. The air tubes were then connected to the Companion-2 Hospital Driver (SynCardia Systems, Inc., Tucson, AZ, USA), and the pump was started by single pulses after the removal of the aortic cross-clamp. Finally, when the pump function and hemostasis were ensured, the patient was weaned off the cardiopulmonary bypass (CPB) and the TAH began operating at 130 bpm.

The sternum was left open, and the skin was closed. The patient was then transferred to the ICU without inotrope therapy. However, on postoperative day two (POD 2), he was taken into the operating room for tamponade. Meticulous hemostasis and cleaning was performed, and all layers were closed (Figure 1d). To facilitate the future HTx operation, a Gore-Tex patch

sheath was sewn to the edges of the pericardium to prevent dense adhesions around the TAH before wiring the sternum.<sup>[9,10]</sup>

For peri- and postoperative anticoagulation, we followed the protocol described by El-Banayosy et al.<sup>[4]</sup> The early postoperative course was uneventful, and the patient was extubated on POD 4 and transferred to the ward on POD 8. However, he had to have a surgical revision that same night because of massive bleeding due to excessive anticoagulation. No specific bleeding site was found, but the pericardial cavity was rinsed with warm saline solution. He was then transferred back to the ICU and reextubated the following day. After one week of close follow-up and rehabilitation, the patient was returned to the ward. During his stay there, besides the rehabilitation, the patient and his family were educated about anticoagulation and device maintenance. Finally, the Companion 2 Driver was replaced with the Freedom

portable Driver (SynCardia Systems, Inc. Tucson, AZ, USA), and the patient was discharged on POD 60. No complications have occurred since that time except for an entry site infection that was treated with intravenous antibiotics. Twenty-six months after the operation, the patient is still on the waiting list for a donor heart. The patient is capable of doing office work and is enjoying his social life without any major limitations, but he is not allowed to swim (Figure 2).

## DISCUSSION

End-stage heart failure is a mortal healthcare problem with an increasing prevalence rate. Orthotopic HTx has been the gold standard therapy for these patients for decades; however, limited organ availability is a major limitation throughout the world. The difference between the supply (donor hearts) and the demand (patients on the waiting list) leads to a worsening of the clinical status or even death while waiting for the procedure, and this occurs despite close follow-up and intensive medical therapy. Therefore, the need for MCS is growing. The International



**Figure 2.** The patient in his daily activity 1.5 year after the implantation.

Society for Heart and Lung Transplantation (ISHLT) recently showed that one-third of patients who had a HTx in 2009 had previously undergone MCS.<sup>[11]</sup> This represents a nearly two-fold increase in the proportion of BTT to HTx's within the last 10 years. Similarly, the use of MCS systems has increased tremendously within the last decade in Turkey. As the short- and long-term support systems began to be classified and covered by the social security system, the pathway towards recovery or transplantation became open, offering hope that had previously been nonexistent.

The decision regarding whether to use a univentricular [i.e. left ventricular assist device (LVAD)] or a biventricular MCS system [i.e. biventricular assist device (BiVAD), TAH] has been a subject of debate for years. Obviously, a univentricular MCS is a less aggressive option and should be preferred whenever possible and feasible. However, RV failure after LVAD implantation has a significantly worse outcome in the early and late postoperative period of this critically ill patient population and should be avoided, especially in those who have limited reserves.<sup>[12,13]</sup> Many centers have been searching for specific parameters to predict RV failure after LVAD implantation and have developed some algorithms accordingly. For example, Kormos et al.<sup>[12]</sup> found that the central venous pressure-to-pulmonary capillary wedge pressure (CVP/PCWP) ratio and the need for preoperative ventilator support along with a blood urea nitrogen (BUN) level  $>39$  mg/dL are independent predictors of RV failure after LVAD implantation by multivariate analysis, but Ochiai et al.<sup>[13]</sup> reported that preoperative MCS, female gender, and non-ischemic etiology are the risk factors for post-LVAD RV failure by multivariable logistic regression analysis. In addition, several parameters for prediction of post-LVAD RV failure have been investigated, but a consensus has yet to be reached.<sup>[12-17]</sup> Krabatsch et al.<sup>[18]</sup> from the Berlin Heart Center published their own algorithm for the decision of LV versus biventricular support and suggested a preference for biventricular support if there is moderate/severe (grade 3-4) tricuspid regurgitation or echocardiographic evidence of RV/RA dilatation and dysfunction despite low PVR ( $<4$  woods) in patients with terminal HF. Although some findings in our patient, such as the CVP/PCWP ratio and the RV stroke work index (RVSWI) were inconsistent with the criteria defined by Kormos et al.,<sup>[12]</sup> the Berlin Heart Center algorithm was a perfect fit for our case<sup>[18]</sup> as our patient had all the signs of impending cardiogenic shock (hypotension and oliguria), volume overload (ascites, peripheral

edema, and pulmonary congestion), and deteriorating end-organ (i.e. liver, kidneys) functions at the time of his second admission to the hospital. Furthermore, Nishimura et al.<sup>[19]</sup> underlined the importance of “luxury flow” for the recovery of end-organ functions in those who have ESHF with multi-system failure and also emphasized the necessity for a minimum cardiac index of 3.0 L/min/m<sup>2</sup> for the recovery of preoperative end-organ dysfunction. Our patient, who had a body surface area (BSA) of 2.45 m<sup>2</sup>, needed a cardiac output of at least 7.5-8 L/min for recovery. This would have been difficult to achieve by contemporary pulsatile or nonpulsatile MCS systems, making TAH the only viable option. Because of the patient’s hemodynamics, clinical status, and body size along with the nonischemic etiology of the ESHF that was affecting both ventricles, our HF board decided that biventricular support would be the optimal solution for this patient until a suitable donor heart is available.

There has also been an ongoing debate regarding the use of BiVAD versus TAH for BTT in cases of severe biventricular ESHF. In a comparative study published by Copeland et al.,<sup>[20]</sup> the survival-to-transplantation rate was significantly higher in the patients with terminal biventricular HF who received TAH compared with those who received BiVAD (75% vs. 38%, respectively;  $p=0.003$ ). Furthermore, Pajaro et al.<sup>[21]</sup> showed in a single-center retrospective analysis that patients with ESHF (Intermacs Level 1-3) who received a TAH also showed an improved survival-to-transplant rate compared with those who received BiVAD (89% vs. 50%, respectively;  $p=0.004$ ). On the other hand, El-Banayosy et al.<sup>[4]</sup> reported significantly higher mortality rates (52%) after TAH implantation than the other groups. However, this difference was related to patient selection and the timing of the TAH implantation.<sup>[4]</sup> Nearly half of their patients consisted of those with postcardiotomy HF, acute myocardial infarction (AMI), or primary graft failure/rejection, and these have worse outcomes after TAH implantation than those with terminal biventricular HF due to chronic ischemic/non-ischemic cardiomyopathy. Additionally, 35% of the patients were on another MCS system at the time of the TAH implantation.<sup>[4]</sup> Copeland et al.<sup>[6]</sup> reported a survival-to-transplantation rate of 68.3% over a 17-year period (1993-2009), whereas LePrince et al.<sup>[2]</sup> reported a rate of 53.5% over a 15-year period (1986-2001). What is more interesting is that the survival rate of the LaPitié-Salpêtrière group increased significantly from 43% between 1986 and 1992 to 55% between 1993 and 1997. It then increased to a high of 74%

between 1998 and 2001),<sup>[2]</sup> but then declined to 55.5% between 2006 and 2010).<sup>[22]</sup> Another French group also recently reported a survival rate of 71.5%.<sup>[5]</sup> Although survival-to-transplant rates have improved significantly over the last few decades,<sup>[2,20,21]</sup> the difference between TAH and BiVAD outcomes have remained firmly in favor of TAH. Furthermore, the results of the French MCS Registry demonstrated that patients who undergo prolonged support (>90 days) tend to have improved survival rates when supported by TAH rather than BiVAD.<sup>[23]</sup> However, these results represent the outcome for pulsatile paracorporeal BiVADs, which are prone to several complications such as driveline and bloodstream infections, stroke, and device malfunction. The use of new-generation, implantable continuous flow devices like BiVADs has also been recently reported,<sup>[18]</sup> but this series noted a 41.2% (7 out of 17 patients) in-hospital mortality due to either multiorgan failure ( $n=4$ ), sepsis ( $n=2$ ), or respiratory complications ( $n=1$ ) and an 11.8% (2 out of 17 patients) mortality rate within one year of discharge. Although the implantable continuous flow devices appear to be the preferred choice for LV failure, we think that they must be refined for biventricular use since they have been designed as LVADs. Regarding the shortcomings of pulsatile paracorporeal devices and limited BiVAD experience with implantable continuous flow devices, we believe that TAH is currently the best option for those who are suffering from terminal biventricular ESHF who are at risk of imminent death (Intermacs Level 1-2). However, prospective studies are needed to compare the outcomes of TAH and new generation BiVADs serving as a BTT device in these patients.

The SynCardia TAH is driven by the Companion 2 Driver and consists of pneumatic pumps for both ventricles and transport batteries. It also has an alarm system inside and a touch-screen monitor on top and has been used as the primary driver in hospitals. However, it should be replaced by the smaller, lighter and portable Freedom Driver before the patient is discharged. Our patient was supported by the Companion 2 Driver for 50 days after the operation, and then the Freedom Driver was implemented because it facilitates patient mobilization and helps the patient to perform daily activities without any major limitations (Figure 2).<sup>[22]</sup>

When emergent HTx is indicated, MCS systems are the treatment of choice when a donor heart is unavailable. A TAH is effective for those who need MCS for severe biventricular ESHF (Intermacs Level 1-2). We hope that this type of implantation

will become a standard surgical alternative to other MCS systems and be utilized without hesitation when indicated at HTx centers in Turkey in order to decrease mortality and increase the quality of life (QoL) for patients on the HTx waiting list.

### Acknowledgement

The authors are grateful to Professor Latif Arusoglu for his perioperative proctorship and to Professor Paul E. Nolan for his contributions to the early postoperative management.

### Declaration of conflicting interests

The authors declared no conflicts of interest with respect to the authorship and/or publication of this article.

### Funding

The authors received no financial support for the research and/or authorship of this article.

### REFERENCES

1. Copeland JG 3rd, Arabia FA, Banchy ME, Sethi GK, Foy B, Long J, et al. The CardioWest total artificial heart bridge to transplantation: 1993 to 1996 national trial. *Ann Thorac Surg* 1998;66:1662-9.
2. LePrince P, Bonnet N, Rama A, Léger P, Bors V, Levasseur JP, et al. Bridge to transplantation with the Jarvik-7 (CardioWest) total artificial heart: a single-center 15-year experience. *J Heart Lung Transplant* 2003;22:1296-303.
3. Copeland JG, Smith RG, Arabia FA, Nolan PE, Sethi GK, Tsau PH, et al. Cardiac replacement with a total artificial heart as a bridge to transplantation. *N Engl J Med* 2004;351:859-67.
4. El-Banayosy A, Arusoglu L, Morshuis M, Kizner L, Tenderich G, Sarnowski P, et al. CardioWest total artificial heart: Bad Oeynhausen experience. *Ann Thorac Surg* 2005;80:548-52.
5. Roussel JC, Sénage T, Baron O, Périgaud C, Habash O, Rigal JC, et al. CardioWest (Jarvik) total artificial heart: a single-center experience with 42 patients. *Ann Thorac Surg* 2009;87:124-9.
6. Copeland JG, Copeland H, Gustafson M, Mineburg N, Covington D, Smith RG, et al. Experience with more than 100 total artificial heart implants. *J Thorac Cardiovasc Surg* 2012;143:727-34.
7. Morris RJ. Total artificial heart--concepts and clinical use. *Semin Thorac Cardiovasc Surg* 2008;20:247-54.
8. Kucukaksu DS, Pektok E, Arat N, Yildiz O, Demirozu ZT, Ece F, ve ark. Kalp nakline köprüleme amacıyla total yapay kalp implantasyonu: Türkiye'de yapay kalple evinde yaşayan ilk hasta. *Türk Kalp ve Damar Cerrahisi Derneği 12. Ulusal Kongresi*, 8-11 Kasım 2012, Antalya, Turkey; 2012. s. 77.
9. Copeland JG, Arabia FA, Smith RG, Covington D. Synthetic membrane neo-pericardium facilitates total artificial heart explantation. *J Heart Lung Transplant* 2001;20:654-6.
10. LePrince P, Rahmati M, Bonnet N, Bors V, Rama A, Léger P, et al. Expanded polytetrafluoroethylene membranes to wrap surfaces of circulatory support devices in patients undergoing bridge to heart transplantation. *Eur J Cardiothorac Surg* 2001;19:302-6.
11. Stehlik J, Edwards LB, Kucheryavaya AY, Benden C, Christie JD, Dobbels F, et al. The Registry of the International Society for Heart and Lung Transplantation: Twenty-eighth Adult Heart Transplant Report--2011. *J Heart Lung Transplant* 2011;30:1078-94.
12. Kormos RL, Teuteberg JJ, Pagani FD, Russell SD, John R, Miller LW, et al. Right ventricular failure in patients with the HeartMate II continuous-flow left ventricular assist device: incidence, risk factors, and effect on outcomes. *J Thorac Cardiovasc Surg* 2010;139:1316-24.
13. Ochiai Y, McCarthy PM, Smedira NG, Banbury MK, Navia JL, Feng J, et al. Predictors of severe right ventricular failure after implantable left ventricular assist device insertion: analysis of 245 patients. *Circulation* 2002;106:1198-202.
14. Fitzpatrick JR 3rd, Frederick JR, Hsu VM, Kozin ED, O'Hara ML, Howell E, et al. Risk score derived from pre-operative data analysis predicts the need for biventricular mechanical circulatory support. *J Heart Lung Transplant* 2008;27:1286-92.
15. Matthews JC, Koelling TM, Pagani FD, Aaronson KD. The right ventricular failure risk score a pre-operative tool for assessing the risk of right ventricular failure in left ventricular assist device candidates. *J Am Coll Cardiol* 2008;51:2163-72.
16. Drakos SG, Janicki L, Horne BD, Kfoury AG, Reid BB, Clayson S, et al. Risk factors predictive of right ventricular failure after left ventricular assist device implantation. *Am J Cardiol* 2010;105:1030-5.
17. Wang Y, Simon MA, Bonde P, Harris BU, Teuteberg JJ, Kormos RL, et al. Decision tree for adjuvant right ventricular support in patients receiving a left ventricular assist device. *J Heart Lung Transplant* 2012;31:140-9.
18. Krabatsch T, Potapov E, Stepanenko A, Schweiger M, Kukucka M, Huebler M, et al. Biventricular circulatory support with two miniaturized implantable assist devices. *Circulation* 2011;124:S179-86.
19. Nishimura M, Nishimura T, Ishikawa M, Masuoka A, Okamura N, Abe K, et al. Importance of luxury flow for critically ill patients receiving a left ventricular assist system. *J Artif Organs* 2006;9:209-13.
20. Copeland JG 3rd, Smith RG, Arabia FA, Nolan PE, Mehta VK, McCarthy MS, et al. Comparison of the CardioWest total artificial heart, the novacor left ventricular assist system and the thoratec ventricular assist system in bridge to transplantation. *Ann Thorac Surg* 2001;71:S92-7.
21. Pajaro OE, Kalya AV, Gopalan RS, et al. Survival to transplant in patients undergoing mechanical circulatory support as bridge: retrospective analysis of LVAD,

- BiVAD and TAH strategy. *J Heart Lung Transplant* 2012;30(Suppl 4):S134.
22. Demondion P, Fournel L, Niculescu M, Pavie A, Leprince P. The challenge of home discharge with a total artificial heart: the La Pitie Salpetriere experience. *Eur J Cardiothorac Surg* 2013. [Epub ahead of print]
23. Kirsch M, Mazzucotelli JP, Roussel JC, Bouchot O, N'loga J, Leprince P, et al. Survival after biventricular mechanical circulatory support: does the type of device matter? *J Heart Lung Transplant* 2012;31:501-8.