

## Absent right superior vena cava with persistent left superior vena cava and normal atrial arrangement

*Normal atriyal bağlantılı kalıcı sol superior vena cava ile birlikte sağ superior vena cava yokluğu*

Özben Ceylan,<sup>1</sup> Senem Özgür,<sup>1</sup> Utku Arman Örün,<sup>1</sup> Vehbi Doğan,<sup>1</sup> Murat Koç,<sup>2</sup>  
Osman Yılmaz,<sup>1</sup> Mahmut Keskin,<sup>1</sup> Selmin Karademir<sup>1</sup>

Departments of <sup>1</sup>Pediatric Cardiology and <sup>2</sup>Pediatric Cardiovascular Surgery,

Dr. Sami Ulus Obstetrics and Gynecology, Children's Health and Diseases Training and Research Hospital, Ankara, Turkey

**Background:** This study aims to investigate the role of echocardiography in the detection of venous anomalies of large thoracic veins in patients with large coronary sinus.

**Methods:** Between January 2010 and March 2012, six patients (3 boys, 3 girls; mean age 4.1; range 3 days - 9 years) were diagnosed with an absent right superior vena cava (RSVC) accompanied by persistent left superior vena cava (PLSVC) in our clinic. The diagnosis of the absent RSVC was established by echocardiography and angiography.

**Results:** Diagnosis of the absent RSVC was confirmed by echocardiography in four patients. The diagnosis was based on cardiac catheterization and angiography in two patients. Additional cardiac anomalies included peripheral pulmonary stenosis, patent ductus arteriosus, tetralogy of Fallot, atrial septal defect, ventricular septal defect and interrupted aortic arch type B. One patient had Trisomy 9p syndrome, while another one was the baby of a diabetic mother. Three patients were followed clinically, while other three patients were operated.

**Conclusion:** Absent RSVC should be thoroughly investigated in cases with a large coronary sinus along with increased coronary sinus flow and PLSVC, as evidenced by echocardiography.

**Key words:** Absent right superior vena cava; congenital heart disease; infant of diabetic mother; persistent left superior vena cava; Trisomy 9p syndrome.

**Amaç:** Bu çalışmada koroner sinüsü geniş olan hastalarda büyük torasik venlerin dönüş anormalliklerini saptayabilmeye ekokardiyografinin rolü araştırıldı.

**Çalışma planı:** Ocak 2010 - Şubat 2012 tarihleri arasında kliniğimizde altı hastaya (3 erkek, 3 kız; ort. yaş 4.1; dağılım 3 gün - 9 yıl) kalıcı sol superior vena kavanın (SVK) eşlik ettiği sağ superior vena cava (SVK) yokluğu tanısı konuldu. Sağ SVC yokluğu tanısı ekokardiyografi ve anjiyografi ile konuldu.

**Bulgular:** Dört hastada sağ SVK yokluğu tanısı ekokardiyografi ile teyit edildi. İki hastada ise, kardiyak kateterizasyon ve anjiyografi ile tanı konuldu. Ek kardiyak anomaliler periferik pulmoner darlık, patent duktus arteriyozus, Fallot tetralojisi, atriyal septal defekt, ventriküler septal defekt ve kesintili aortik ark tip B idi. Bir hasta Trizomi 9p sendromlu iken, diğeri diyabetik bir annenin bebeği idi. Üç hasta klinik izleme alındı, diğer üç hasta ameliyat edildi.

**Sonuç:** Ekokardiyografi ile ortaya konduğu üzere, koroner sinüsün geniş olduğu, koroner sinüs akımının arttığı ve kalıcı sol SVK'nin görüldüğü olgularda sağ SVK yokluğunun dikkatli bir şekilde araştırılması gerekmektedir.

**Anahtar sözcükler:** Sağ superior vena cava yokluğu; doğuştan kalp hastalığı; diyabetik anne bebeği; kalıcı sol superior vena cava; Trizomi 9p sendromu.



An absent right superior vena cava (RSVC) is quite rare in the viscerotrial situs and is observed in 0.07-0.13% of patients with cardiovascular malformation.<sup>[1,2]</sup> This anomaly is characterized by the drainage of the left azygos veins into the left superior vena cava (LSVC) and the persistent left superior vena cava (PLSVC) draining into the right atrium through the coronary sinus. In addition, the PLSVC is directly linked to the left atrium in some patients with normal atrial situs. When this occurs, all of the venous blood from the upper part of the body flows into the left atrium.<sup>[3]</sup>

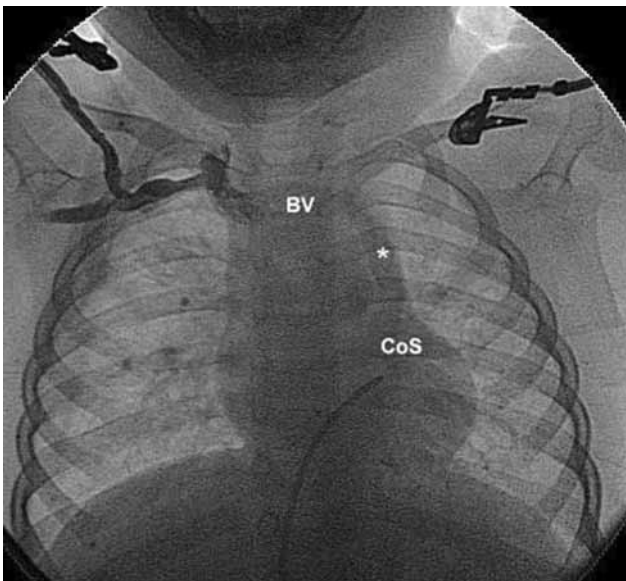
In this article, the clinical findings, diagnosis, and treatment methods along with the follow-up results of six patients with an absent RSVC accompanied by a PLSVC are described, and the literature is reviewed.

### PATIENTS AND METHODS

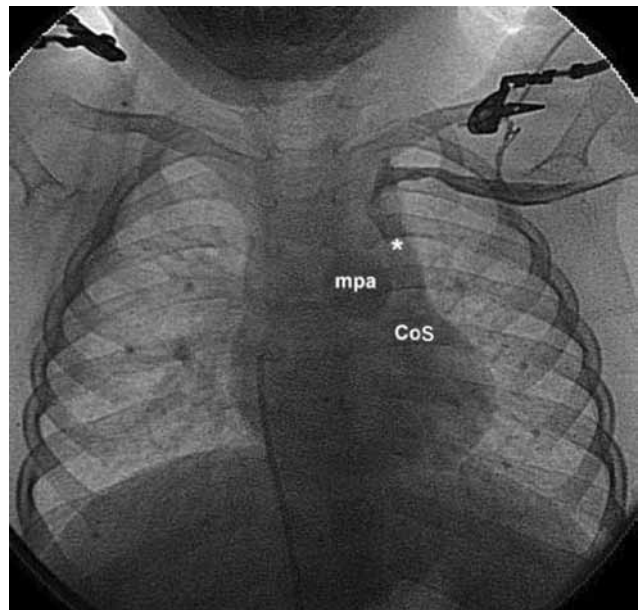
Between January 2010 and March 2012, six patients were diagnosed with an absent RSVC accompanied by a PLSVC at our clinics. In addition to the demographic and clinical findings, the telecardiography, echocardiography, cardiac catheterization, and angiography results of all of the patients at the time of initial diagnosis were obtained from their medical records. The diagnosis of an absent RSVC was established by echocardiography and angiocardiology, with each patient undergoing detailed two-dimensional (2D) and Doppler echocardiographic investigations using the 3 MHz

probe of a Vivid 7 ultrasound device (GE Vingmed Ultrasound AS, Horten, Norway). For all of the patients, the catheter could not be advanced into the RSVC. The diagnosis was established from the images obtained during the intravenous injection of contrast material through the right antecubital vein, revealing the absent RSVC while the PLSVC and coronary sinus were visible (Figure 1). In order to show the PLSVC, the angiographic images were taken while the contrast material was draining through the left antecubital vein and into the PLSVC. It subsequently then went into the coronary sinus (Figure 2). In the fifth patient, since there was no cardiac pathology except for an absent RSVC and a PLSVC, the diagnosis was confirmed by contrast echocardiography alone (Figures 3 and 4).

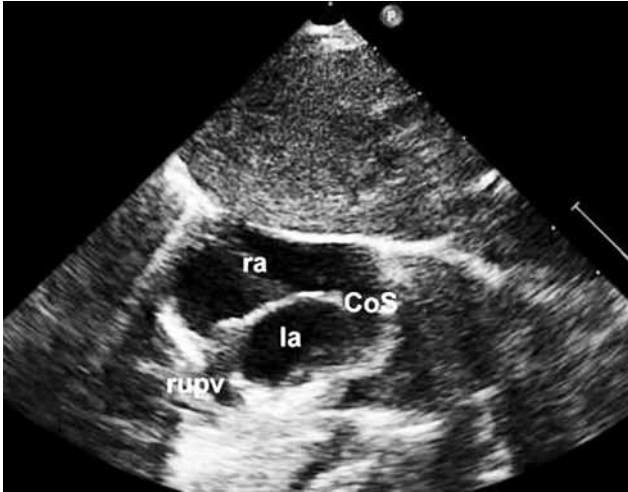**Patient 1-** A nine-year-old male patient was admitted to our clinic because of a murmur. A physical examination revealed a 3/6 systolic murmur at the upper left sternal area while the electrocardiography (ECG) and telecardiography were normal. On the echocardiography, the atrial situs was normal with a large coronary sinus, and peripheral left pulmonary stenosis (PS) was present. No RSVC was observed, but the PLSVC opening into the coronary sinus was detected. Cardiac catheterization and angiography showed that the contrast material, which was given through the right antecubital vein, reached the coronary sinus via the PLSVC and continued draining into the



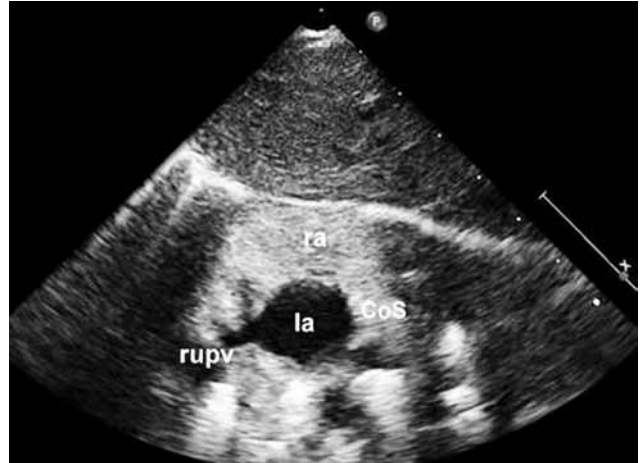**Figure 1.** The contrast material inserted into the right arm passed from the bridge vein (BV), formed by the joint of the right subclavian and right jugular vein, and into the persistent left superior vena cava (\*) joining the coronary sinus (CoS).



**Figure 2.** The contrast material inserted into the left arm passed from the persistent left superior vena cava (\*) and drained into the coronary sinus (CoS) main pulmonary artery (mpa).



**Figure 3.** An echocardiographic image shows the in-position subcostal short axis. The right superior vena cava was absent, and a large coronary sinus was present. rupv: Right upper pulmonary vein; la: Left atrium; ra: Right atrium; CoS: coronary sinus.



**Figure 4.** A contrast echocardiographic image shows the subcostal short axis position. The agitated saline filled the right atrium through the coronary sinus. The right superior vena cava was absent. rupv: Right upper pulmonary vein; la: Left atrium; ra: Right atrium; CoS: Coronary sinus.

right atrium, but an RSVC was not present. The contrast material given through the left antecubital vein passed into the coronary sinus via the PLSVC, and the right atrium was visualized (Figures 1 and 2). In addition, a 30 mmHg systolic pressure gradient was detected between the main pulmonary and left pulmonary arteries. No need for therapy was indicated, and the patient is currently being followed up.

**Patient 2**– A two and-a-half-year-old male patient was admitted with a diagnosis of patent ductus arteriosus (PDA). A physical examination revealed a weight of 9 kg (< third percentile), a height of 70 cm (< third percentile), and a head circumference of 43 cm (< third percentile). Furthermore, the peripheral pulses were hyperactive, and facial asymmetry, a low nasal root, and flattened ears were detected. In the neurological examination, he had no head and neck control and no bilateral convergent strabismus. The patient could not stand unsupported and crawled, but the muscle tone and deep tendon reflexes were normal. A chromosome analysis was performed due to the patient’s syndromic appearance, and the results were compatible with trisomy ninth percentile. However, the telecardiography and ECG were normal. Dandy-Walker syndrome (DWS) was also detected via cranial magnetic resonance imaging (MRI), and an echocardiographic examination revealed an atrial situs solitus and a large coronary sinus along with a PLSVC that was draining into the coronary sinus and a narrow PDA. The RSVC could not be entered through cardiac catheterization, so we concluded that it was absent. Angiography was then performed in

which contrast material was inserted through the right antecubital vein. However, this proceeded to drain into the coronary sinus with the PLSVC; thus, the RSVC could not be visualized. In addition, an aortic arcus injection also showed a narrow ductus arteriosus. The pulmonary-to-systemic flow ratios ( $Q_p/Q_s$ ) was 1:1; hence, no intervention was attempted on the ductus, and patient follow-up was recommended.

**Patient 3**– A seven-year-old female patient was admitted to our clinical center for cyanosis and convulsions when she was one year old, and she was hospitalized and followed up after being diagnosed with tetralogy of Fallot (TOF), right ventricular thrombus, and a bilateral cerebral infarction. Since completion of her therapy, she had received no follow-up for six years. In her physical examination, growth retardation, central cyanosis, left hemiplegia, and a 3/6 systolic murmur in the left sternal border were observed, and a neurological examination revealed mental and motor retardation. Furthermore, a “coeur-en-sabot” configuration was visible on telecardiography, and right ventricle hypertrophy was seen on echocardiography, which also showed an atrial situs solitus, patent foramen ovale (PFO), a large ventricular septal defect (VSD), aortic dextroposition, and right ventricular outflow tract (RVOT) obstruction. The RSVC could not be entered from the right atrium during cardiac catheterization. In addition, the patient’s right ventricular pressure was 95 mmHg, and she had an arterial oxygen saturation (OS) of 76%. During angiography, we observed that the contrast substance, which was given via her right arm vein, was draining into the coronary sinus and right

atrium via the PLSVC. A right ventricle angiogram also detected infundibular pulmonary valvular stenosis, aortic dextroposition, and a large subaortic VSD, and a McGoon ratio of 2.06. In the surgical procedure, the VSD was closed, and a transannular patch was placed in the RVOT. The diagnosis of absent RSVC and PLSVC was also verified during the operation.

**Patient 4**– A six-year-old female patient with a surgically closed atrial septal defect (ASD) and PS was referred to our clinic because the stitches that had been used to close the defect had loosened spontaneously. A physical examination detected a 3/6 murmur on the upper left sternal border. The telecardiography results were normal, but an rsR' pattern was detected on ECG, which also revealed an atrial situs solitus, a dilated coronary sinus and right ventricle, and a large ASD. No RSVC was seen, but a PLSVC that opened into the coronary sinus was detected. During the cardiac catheterization and angiography, the contrast material that was inserted into the right antecubital vein drained into the coronary sinus via the PLSVC, but an RSVC was not present. Furthermore, venous angiography via the left antecubital vein showed a PLSVC that was draining into the right atrium from the coronary sinus. The Qp/Qs was 3.14; therefore, it was decided to reclose the patient's ASD. No RSVC was ever observed during the operation, but the PLSVC was draining into the large coronary sinus. In the lower rim of the ASD, surgical material and a loosened patch were also observed.

**Patient 5**– A six-day-old male baby with a birth weight of 4400 g had been delivered by a diabetic mother via cesarean section due to fetal distress and preeclampsia six days earlier was brought to our

facility with suspected apnea. His lung sounds were normal, and there was no murmur heard in the physical examination. In addition, the telecardiography results were within normal limits. In the echocardiographic examination, PFO was present, and the coronary sinus was larger than normal. Although no RSVC was observed, a PLSVC was visualized which was opening into the coronary sinus (Figure 3). Contrast echocardiography was also performed using agitated saline that was inserted into the right antecubital vein. The substance passed into the right atrium through the coronary sinus, and no RSVC was detected. In the follow-up period, no apneic attacks occurred, and the patient was subsequently discharged (Figure 4).

**Patient 6**– A three-day-old female baby who weighed 3600 g at birth was hospitalized because of cyanosis and tachypnea along with a deterioration in her general condition. She was cyanotic and tachypneic on her physical examination. However, her lung sounds were normal, and no murmur was heard. In addition, her chest X-ray was normal. An echocardiographic examination found an atrial situs solitus, ASD, VSD, a type B interrupted aortic arch, a coronary artery anomaly (anomalous origin of the right coronary artery from the left sinus of valsalva), and a larger than normal coronary sinus. There was no RSVC, but a PLSVC was detected which opened into the coronary sinus. Like the other patients, contrast material was inserted through the right antecubital vein. It entered the coronary sinus via the PLSVC, but no RSVC was found. A left antecubital vein injection showed a PLSVC draining into the right atrium through the coronary sinus. In addition, an interrupted aortic arch

**Table 1. Demographic and clinical properties of the patients**

	Patient 1	Patient 2	Patient 3	Patient 4	Patient 5	Patient 6
Age/gender	9 years/M	2.6 years/M	7 years/F	6.6 years/F	6 days/M	3 days/F
Cause of admission	Murmur	Murmur	Convulsion, cyanosis	Residual ASD	Apnea	Cyanosis, tachypnea
Additional anomaly	–	MMR*	MMR <sup>e</sup>	–	DMB	–
ECG	Normal	Normal	Right axis, right ventricle hypertrophy	rsR in V1	Normal	Normal
Persistent left SVC	+	+	+	+	+	+
Additional cardiac anomaly	Stenosis in left pulmonary artery	PDA	PFO, TOF	ASD, PS	PFO	ASD, VSD, type B interrupted aortic arch, coronary artery anomaly

ASD: Atrial septal defect; MMR: Mental motor retardation; DMB: Diabetic mother's baby; ECG: Electrocardiography; SVC: Superior vena cava; PDA: Patent ductus arteriosus; PFO: Patent foramen oval; TOF: Tetralogy of Fallot; PS: Pulmonary stenosis; VSD: Ventricular septal defect; \* Based on trisomy 9p, <sup>e</sup> based on cerebrovascular accident.

**Table 2. Hemodynamic data of the patients**

	PLSVC	RA	LA	RV	PA	Ao	dAo	Qp/Qs	Rp
Patient 1									
Oxygen saturation (%)	–	–	–	–	–	–	–	–	–
Pressure (mmHg)	–	–	7	50	30/20/18‡	115/58/50	14/87/113	–	–
Patient 2									
Oxygen saturation (%)	70	71	97	71	72	–	93	1.1	0.42
Pressure (mmHg)	–	3	4	22	21/9/13	–	90/61/73	–	–
Patient 3									
Oxygen saturation (%)	–	–	–	–	–	–	86	–	–
Pressure (mmHg)	–	9	10	95	–	–	112/65/78	–	–
Patient 4									
Oxygen saturation (%)	69	87	94	87	87	–	91	3.14	0.96
Pressure (mmHg)	–	10	10	51	35/10/23	–	90/45/65	–	–
Patient 5									
Oxygen saturation (%)	60	61	–	–	–	–	–	–	–
Pressure (mmHg)	–	8	–	–	50/26/39	–	–	–	–

PLSVC: Persistent left superior vena cava; RA: Right atrium; LA: Left atrium; RV: Right ventricle; PA: Pulmonary artery; Ao: Ascending aorta; dAo: Descending aorta; Qp/Qs: Pulmonary to systemic blood flow ratio; Rp: Pulmonary resistance; ‡: Left pulmonary artery.

was observed between the left subclavian and left carotid arteries via a left ventricular injection. During the surgical procedure, the patient's ASD and VSD were closed, and continuation of the aortic arcus was achieved with prosthetic material.

The demographic and clinical features of the six patients are summarized in Table 1, and the hemodynamic data is summarized in Table 2.

## DISCUSSION

Systemic venous anomalies can cause complications during the surgical repair of cardiac defects. While often only minor asymptomatic anatomic variations are present, sometimes patients may be admitted with cyanosis or symptoms of other congenital heart diseases.<sup>[3]</sup> In the embryological process, the anterior venous cardinal system on the left side regresses into the coronary sinus and ligament of Marshall. The PLSVC, which appears in cases in which the left anterior cardinal vein has disappeared, is a systemic venous anomaly that is found in approximately 0.3-0.5% of the general population. However, the frequency could be as high as 3-10% in patients with congenital heart disease.<sup>[4]</sup> This anomaly is generally accompanied by an RSVC, but this is rarely absent.<sup>[5]</sup> Bartram et al.<sup>[6]</sup> detected congenital cardiac malformation in 46% (n=55) of 121 cases with a PLSVC but an absent RSVC the most frequent accompanying congenital heart diseases in their study were ASD, VSD, and TOF. Five of our patients had an accompanying congenital heart disease, with peripheral pulmonary artery stenosis, PDA, TOF, ASD, PS, a type B interrupted aortic

arch, and a coronary artery anomaly being detected. Since an absent RSVC is clinically asymptomatic, its occurrence should be investigated in patients who are admitted to a pediatric cardiology clinic prior to receiving invasive medical or surgical interventions. In so doing, complications during treatment might be avoided. Therapeutic difficulties due to an absent RSVC in conjunction with a PLSVC can be seen during the following procedures: (i) transvenous pacemaker implantation, (ii) the placement of a pulmonary artery catheter without fluoroscopy for intraoperative or intensive care monitorization, (iii) systemic venous cannulation for extracorporeal membrane oxygenation, (iv) systemic venous cannulation for cardiopulmonary bypass (CPB), (v) the creation of a partial or total cavopulmonary anastomosis, and (vi) orthotopic heart transplantation and endomyocardial biopsies. The presence of a PLSVC can cause some arrhythmias, sinus node dysfunction, and atrioventricular blocks,<sup>[7]</sup> with the rhythm anomalies being caused by the retarded transmission of impulses due to the enlarged coronary sinus.<sup>[8]</sup> However, no rhythm disturbance was detected in any of our patients.

An isolated PLSVC is quite rare and is found in only 0.07-0.13% of patients with a cardiovascular malformation involving the viscerotrial situs solitus.<sup>[1-3]</sup> A PLSVC with an RSVC was diagnosed in 63 out of 3,117 patients (2%) who were subjected to cardiac catheterization and angiography due to congenital heart disease (CHD) in our center between 2002 and 2012, but only five (0.16%) of our CHD cases had a PLSVC with an absent RSVC during the same period.

In addition, an absent RSVC accompanied by a PLSVC without CHD was observed in only one patient, and that patient was born to a diabetic mother. A review of the literature found no cases of RSVC deficiency with a PLSVC involving trisomy ninth percentile syndrome and a diabetic mother's baby.

An absent RSVC with a PLSVC is coincidentally diagnosed in adult patients primarily during examinations or investigations.<sup>[4-8]</sup> Four of the patients in this study were suspected of an absent RSVC and this was verified by echocardiography. In the other two patients, it was determined coincidentally during angiocardiology.

### **Conclusion**

In order to avoid therapeutic complications in childhood heart diseases, an absent RSVC with a PLSVC should be suspected in patients who show a large, overflowing coronary sinus and a PLSVC during echocardiographic analysis.

### **Declaration of conflicting interests**

The authors declared no conflicts of interest with respect to the authorship and/or publication of this article.

### **Funding**

The authors received no financial support for the research and/or authorship of this article.

## **REFERENCES**

1. Irlich G, Herzer JA, Schulte HD, Irnich W. Left persisting, singular superior vena cava and pacemaker electrode implantation by right cephalic vein. *Z Kardiol* 1976;65:575-82. [Abstract]
2. Lenox CC, Zuberbuhler JR, Park SC, Neches WH, Mathews RA, Fricker FJ, et al. Absent right superior vena cava with persistent left superior vena cava: implications and management. *Am J Cardiol* 1980;45:117-22.
3. Geva T, Praagh ST. Abnormal systemic venous connections. In: Allen HD, Driscoll DJ, Shaddy RE, Feltes TF, editors. *Moss and Adams' heart disease in infants, children, and adolescents: including the fetus and young adults*. 7th ed. Philadelphia: Lippincott Williams & Wilkins; 2008. p. 793-816.
4. Erdoğan M, Karakaş P, Uygur F, Meşe B, Yamak B, Bozkir MG. Persistent left superior vena cava: the anatomical and surgical importance. *West Indian Med J* 2007;56:72-6.
5. Chandra A, Reul GJ Jr. Persistent left superior vena cava discovered during placement of central venous catheter. *Tex Heart Inst J* 1998;25:90.
6. Bartram U, Van Praagh S, Levine JC, Hines M, Bensky AS, Van Praagh R. Absent right superior vena cava in viscerotrial situs solitus. *Am J Cardiol* 1997;80:175-83.
7. Huang SK. Persistent left superior vena cava in a man with ventricular fibrillation. *Chest* 1986;89:155-7.
8. Korkmaz L, Akyüz AR, Erkuş ME, Topal C. Isolated persistent left superior vena cava with absent right superior vena cava in two cases. *Türk Kardiyol Dern Ars* 2011;39:501-4.