

Xanthoma of the rib in a patient with normolipidemia

Serum lipid düzeyi normal olan bir hastada kaburgada ksantoma

Nurettin Yiyit,¹ Zafer Küçükodacı,² Rauf Görür,¹ Turgut Işıtmangil,¹ Fatih Hikmet Candaş,¹ Suat Gezer¹

Departments of ¹Thoracic Surgery and ²Pathology, GATA Haydarpaşa Training Hospital, İstanbul, Turkey

Xanthoma of the bone is a condition which is associated with hyperlipidemia with lipid deposits on the trunk, extremities, subcutaneous tissues, tendons and bone marrow. A 38-year-old male patient was admitted to our clinic with chest pain on the right side. Chest X-ray revealed an expansion on the right ninth rib. Thoracic computed tomography showed a lytic lesion involving the posterior arch of the right ninth rib. Serum lipid profile was within normal range. Technetium-99m methylene diphosphonate scintigraphy indicated a suspicious malignant neoplasm. A relatively hard mass in 3.5x1.5 cm size was excised together with the adjacent tissues. Postoperative histopathologic examination reported as an infiltration of xanthoma cells destroying the bone. A xanthoma of the rib was definite diagnosis. Postoperative period was uneventful with full recovery. No additional treatment was applied. The patient was healthy at 25 months of follow-up.

Key words: Costal xanthoma; hyperlipidemia; xanthoma.

Xanthomatosis is usually considered to be a cutaneous manifestation of hyperlipidemia. On the other hand, xanthoma of the bone is mostly associated with hyperlipidemia with lipid deposits on the trunk, extremities, subcutaneous tissues, tendons, or bone marrow and can be seen in rare instances in patients with normal serum lipid levels. Costal xanthoma associated with normolipidemia is an extremely rare entity, and to the best of our knowledge, this is only the fifth reported case in the literature.

CASE REPORT

A 38-year-old man was admitted to our clinic with chest pain on the right side, and a chest X-ray revealed

Kemik ksantoması genellikle gövde, ekstremiteler, cilt altı dokusu, tendon ve kemik iliğinde lipid birikimi ile hiperlipidemi ile ilişkili olan bir durumdur. Otuz sekiz yaşında erkek hasta sağ tarafta göğüs ağrısı ile kliniğimize başvurdu. Akciğer grafisinde sağ dokuzuncu kaburgada bir genişleme görüldü. Toraks bilgisayarlı tomografide dokuzuncu kaburganın arka arkında litik bir lezyon tespit edildi. Serum lipid profili normal sınırlarda idi. Teknesyum-99m metildifosfanat sintigrafide şüpheli bir malign neoplazm görüldü. Nispeten sert 3.5x1.5 cm boyutlarındaki kitle çevre dokular ile birlikte çıkarıldı. Ameliyat sonrası histopatolojik inceleme sonucu kemiği tahrip eden ksantoma hücreleri olarak bildirildi. Kesin tanı kaburganın ksantoması olarak konuldu. Ameliyat sonrası dönem sıkıntısız ve tam iyileşme ile neticelendi. Ek bir tedavi uygulanmadı. Hastamız 25. ayında sağlıklı olarak takip edilmektedir.

Anahtar sözcükler: Kaburga ksantoması; hiperlipidemi; ksantoma.

a mass-like opacity on the right ninth rib (Figure 1). A physical examination was normal, and there was no history of systemic diseases. Thoracic computed tomography (CT) showed a small, lytic lesion on the posterior arch of the right ninth rib (Figure 2) that was unifocal and limited to the rib without extending to the intrathoracic structures or adjacent tissues. Thus, it was initially thought to be a benign tumor of the rib. The patient's serum lipid profile, including his cholesterol and triglyceride levels, were all within normal limits. Technetium-99m (Tc-99m) methylene diphosphonate (MDP) scintigraphy identified a suspicious malignant (primary or metastatic) neoplasm (Figure 3), and surgical intervention for both diagnosis and treatment



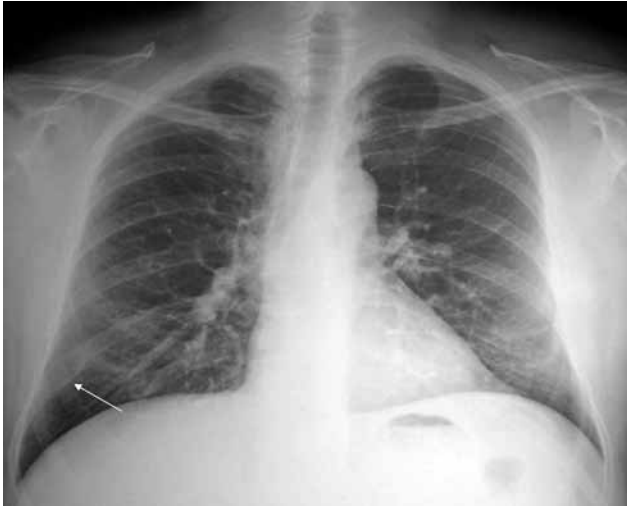

Figure 1. Chest X-ray revealed a mass-like opacity on the right ninth rib.

was planned. During the surgery, a mass with sizes of 3.5x1.5 cm with a relatively firm nature was detected on the posterior part of the ninth costa, and a total resection with enough surgical margins was performed. The postoperative histopathological findings were inconsistent with a benign nature, and infiltration of the xanthoma cells, which was destroying the rib, was noted along with cholesterol granulomas. However, the lesion showed no signs of infiltrating the lymphocytes, eosinophils, or plasma cells (Figure 4). Taking into account all of these findings, xanthoma of

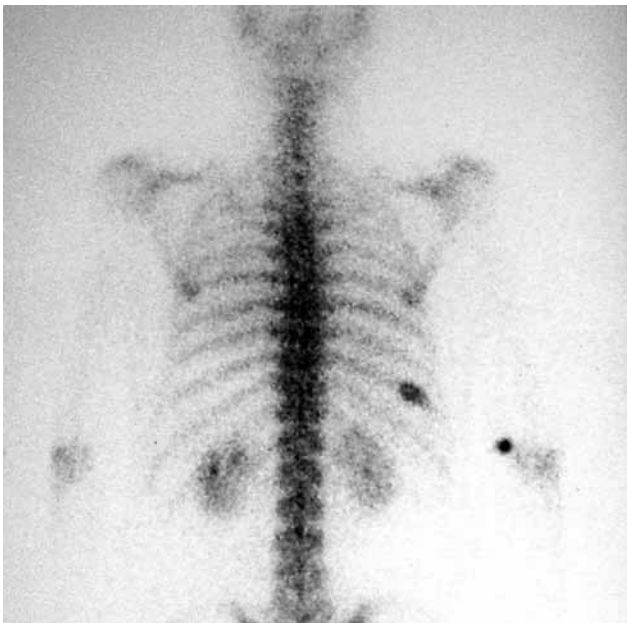


Figure 3. Technetium-99m methylene diphosphonate scintigraphy showing a suspicious malignant lesion.

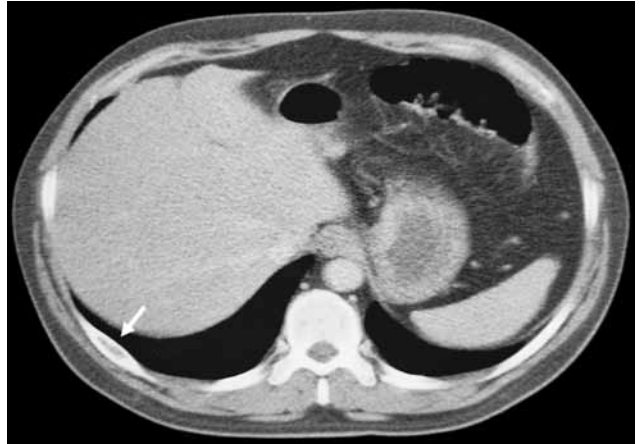

Figure 2. Thoracic computed tomography showing a small lytic lesion on the posterior arch of the right ninth rib.

the rib was definitively diagnosed. No complications were observed, and the patient was discharged on the postoperative fifth day. In addition, no further treatment was recommended except for outpatient follow-up. At the 25-month follow-up, the patient was healthy without any signs of recurrence.

DISCUSSION

Xanthoma of the bone is a very rare entity that is mostly associated with hyperlipidemia and lipid deposits on the trunk, extremities, subcutaneous tissues, tendons, and bone marrow.^[1-4] However, xanthoma of the rib is extremely rare, with only a few cases of costal xanthoma having been reported with normal serum lipid levels.^[5]

The condition is categorized as primary xanthoma when other diseases have been ruled out.^[2] In xanthoma

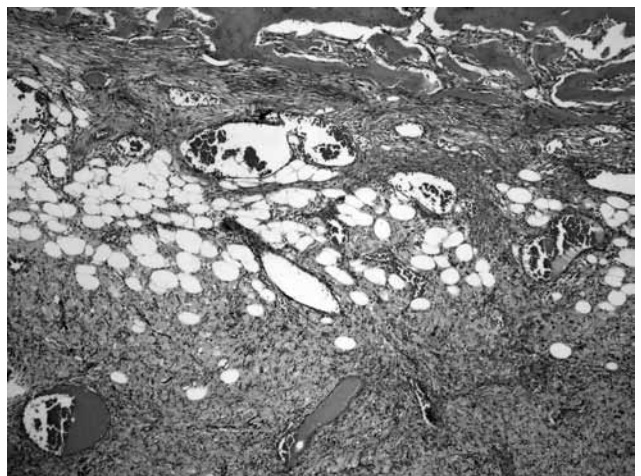


Figure 4. Histopathological examination revealing infiltration of the xanthoma cells with cholesterol granulomas (H-E x 100).

with hyperlipoproteinemia, bone marrow may be progressively infiltrated and replaced by lipid deposits, resulting in trabecular and cortical bone resorption.^[4] In xanthoma without lipid disorders, according to one hypothesis, the possible appearance of the lesion is the result of a reactive response to intramedullary hemorrhage following trauma.^[2,6] Curiously, our patient had no history of trauma, and his lipid profile was within normal limits.

Primary xanthoma of the bone is seen twice as often in men (average age 20-50 years).^[1,2,7] Our patient was a 38-year-old men who was good in health. The initial symptom of primary xanthoma of the bone is believed to be pain, but 30% of the patients with this condition are asymptomatic.^[2,7] In our case, the patient was admitted with chest pain.

Radiologically, xanthoma of the bone almost always appears in a solitary form and most frequently is located in flat bones.^[1,7] In patients with lipid disorders, the lesions are mostly multifocal and are especially found in the lower limbs.^[2] This tumor is benign in appearance and has a purely lytic matrix and good margination.^[2] In our case, despite the benign appearance radiologically, the bone scintigraphy findings with 20 mCi of Tc-99m MDP suggested a malignant lesion. Therefore, costal xanthoma should be considered in the differential diagnosis of diseases which produce xanthomatous changes.^[1]

A diagnosis of xanthoma is based on histological findings. Microscopically, foam cells, macrophages, cholesterol, fibrosis, and hemosiderin often exist.^[2] Xanthomatous lesions of the bone may also be observed as secondarily with various bone lesions, including malignant tumors. Such lesions also appear as xanthomatous nodules in primary and secondary hypercholesterolemic states, xanthomatous areas in meningiomas, histiocytosis X, benign and malignant fibrous xanthomas (histiocytomas), Erdheim-Chester disease (multicyclic granulomatosis), Rosai-Dorfman disease (bone involvement in sinus histiocytosis with massive lymphadenopathy), and xanthogranulomatous osteomyelitis. Subsequently, bone damages with a predominantly xanthomatous component and lesions which have a histological description, such as defective metaphyseal fibrous defect, benign fibrous histiocytoma, aneurysmal bone cysts, simple cysts, fibrous dysplasia, osteomyelitis, histiocytosis, and metastatic clear cell carcinoma should be considered in differential diagnosis.^[1,7] When diagnosis is difficult, an immunohistochemical analysis of the tissue may be helpful, especially when a specimen can be obtained via a needle biopsy.^[2]

In our case, we did not need a preoperative biopsy, and a complete resection of the lesion was planned because of its well-defined margination. The aim of this procedure was to make a definitive diagnosis and then resolve the issue.

In xanthoma with lipid disorders, medical treatment can be sufficient, whereas in xanthoma without hyperlipoproteinemia, a complete or partial removal of the lesion should be the treatment of choice.^[2] Xanthomas may recur if any underlying disorders are left untreated. Thus, medical treatment should be continued after the excision of the xanthoma in cases of hyperlipidemia.^[5] In cases of xanthoma without hyperlipidemia, two studies reported that there were no recurrences after the surgical excision.^[2,5] We also observed no recurrence after the complete surgical excision in our case.

In conclusion, costal xanthoma is an exceptional diagnosis in normolipidemic patients. We believe that xanthoma should be considered in the differential diagnosis of costal lesions that are seemingly benign when viewed on X-rays but are revealed to be malignant on scintigraphy. In these cases, complete surgical excision should be performed.

Declaration of conflicting interests

The authors declared no conflicts of interest with respect to the authorship and/or publication of this article.

Funding

The authors received no financial support for the research and/or authorship of this article.

REFERENCES

1. Kuroiwa T, Ohta T, Tsutsumi A. Xanthoma of the temporal bone: case report. *Neurosurgery* 2000;46:996-8.
2. Ayadi-Kaddour A, Mlika M, Marghli A, Kilani T, El Mezni F. Xanthoma of the rib without hyperlipoproteinemia. *Respiratory Medicine CME* 2008;1:40-2.
3. Lee JY, Pozderac RV, Domanowski A, Torres A. Benign histiocytoma (xanthoma) of the rib. *Clin Nucl Med* 1986;11:769-70.
4. Inserra S, Einhorn TA, Vigorita VJ, Smith AG. Intraosseous xanthoma associated with hyperlipoproteinemia. A case report. *Clin Orthop Relat Res* 1984;187:218-22.
5. Elwood ET, Shahwan TG, Dajani N, Murray JD. Isolated xanthoma of the frontal bone. *J Craniofac Surg* 2005;16:391-4.
6. Parker F. Normocholesterolemic xanthomatosis. *Arch Dermatol* 1986;122:1253-7.
7. Marqués Mateo M, Puche Torres M, Miragall Alba L, Iglesias Gimilio ME, Pascual Gil JV. Primary mandibular bone xanthoma. A case report. *Int J Oral Maxillofac Surg* 2004;33:806-7.