

Recurrent aneurysms following endovascular stent-grafting repair in vascular Behçet's disease

Vasküler Behçet hastalığında endovasküler stent greft onarımı sonrasında gelişen tekrarlayan aort anevrizmaları

Aytaç Gülcü,¹ Naciye Sinem Gezer,¹ Erdem Erinç Silistreli²

Institution where the research was done:
Medical Faculty of Dokuz Eylül University, İzmir, Turkey

Author Affiliations:

Departments of ¹Radiology, ²Cardiovascular Surgery, Medical Faculty of Dokuz Eylül University, İzmir, Turkey

Endovascular stent-graft treatment is one of the treatment modalities in prevention of recurrent aneurysms at the anastomosis site which are common following surgical repair of aneurysms in vascular Behçet's disease. Pseudoaneurysms may also develop at the distal and proximal landing zones of the stent-graft. In this article, we report a 38-year-old male case of vascular Behçet's disease in whom ineffective immunosuppression resulted in the development of recurrent pseudoaneurysms at the proximal and distal ends of the stent graft and all around it. Although stent graft placement may be considered as an alternative treatment to surgery in patients with vascular Behçet's disease, a relatively low, but ongoing risk of recurrent pseudoaneurysm still remains.

Keywords: Aortic pseudoaneurysm; endovascular stent-grafting repair; vascular Behçet's disease.

The incidence of vascular involvement in Behçet's disease (BD) ranges from 2 to 46% and it is four to five times more common in men in the endemic regions, particularly.^[1] Additionally, arterial involvement is less common than venous involvement with a prevalence of 1.5 to 3% worldwide.^[2] The arterial lesions are primarily caused by necrosis in the intimal and medial layers of the artery due to microvasculitis-induced ischemia that affects the vasa vasorum.

Endovasküler stent greft tedavisi vasküler Behçet hastalığında cerrahi onarım sonrasında sıklıkla anastomoz düzeylerinde gelişen tekrarlayıcı anevrizmaların önlenmesinde kullanılan bir tedavi yöntemidir. Stent greft distal ve proksimal tutunma bölgelerinde de psödoanevrizmalar gelişebilir. Bu yazıda, etkisiz immünsüpresyonun stent greftin proksimal ve distal uçlarında ve çevresinde tekrarlayan psödoanevrizma gelişimine neden olduğu vasküler Behçet hastalığı olan, 38 yaşında bir erkek olgu sunuldu. Vasküler Behçet hastalarında endovasküler stent-greft tedavisi cerrahiye alternatif olarak düşünülebilmekle birlikte, nispeten düşük, ancak devam eden tekrarlayan psödoanevrizma riski halen mevcuttur.

Anahtar sözcükler: Aortik psödoanevrizma; endovasküler stent greft onarımı; vasküler Behçet hastalığı.

Aneurysms are reported to be more common than occlusions and may occur in almost all named arteries, however, they are most commonly found in the abdominal aorta.^[2] Moreover, ruptured aneurysms are the most frequent causes of vascular disease-related mortality.^[3]

Stent grafting has been accepted as one of the treatment modalities for aneurysms in prevention of recurrent aneurysms at the anastomosis site, accounting for up to 50% of patients who are treated surgically.^[4-6]



Available online at
www.tgkdc.dergisi.org
doi: 10.5606/tgkdc.dergisi.2014.9279
QR (Quick Response) Code

Received: September 10, 2013 *Accepted:* December 18, 2013

Correspondence: Naciye Sinem Gezer, M.D. Dokuz Eylül Üniversitesi Tıp Fakültesi Radyoloji Anabilim Dalı, 35210 Alsancak, İzmir, Turkey.

Tel: +90 232 - 412 59 90 e-mail: drsinemgezer@gmail.com

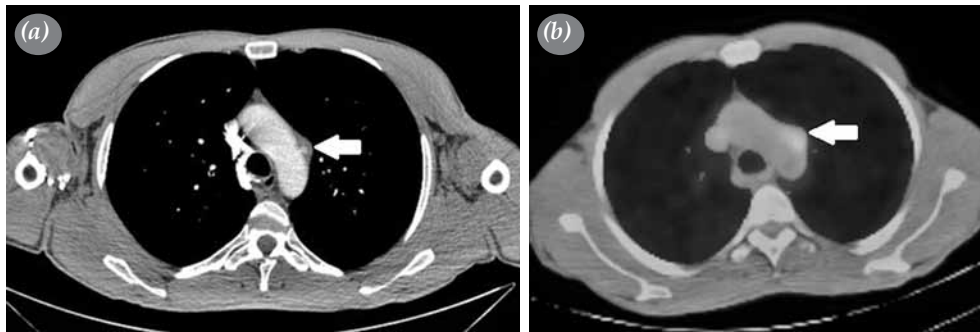


Figure 1. (a) Computed tomographic angiogram of the pseudoaneurysm in the aortic arch. (b) Positron emission tomography-computed tomography showing metabolic activity in the area of the pseudoaneurysm.

However, recent studies have noted that pseudoaneurysms may also develop at the landing zones of the stent graft. Preventive treatment is primarily consisted of immunosuppressive therapy, as it substantially decrease the risk of recurrent aneurysm.^[7]

CASE REPORT

A 38-year-old man presented to our facility with headaches and blurred vision persisting for three months. A fundoscopic examination revealed papilledema in both eyes. He had no past medical, surgical or interventional history or other significant findings on detailed physical examination. Further cerebral magnetic resonance imaging showed a partial venous thrombosis of the superior sagittal, right transverse, and sigmoid sinuses along with a total venous thrombosis of the left transverse and sigmoid sinuses.

The patient had a history of multiple oral aphthae and scrotal ulcerations. Based on the presence of cerebral venous thrombosis, skin lesions, and positive pathergy test, the patient was diagnosed with vascular BD and a combination therapy of corticosteroid, oral prednisolone 20 mg/day, and azathioprine 50 mg/day was immediately initiated. The cerebral venous thrombosis was treated with body weight-adjusted subcutaneous full anticoagulant dose of low-molecular-weight heparin.

On repeated posteroanterior chest X-ray, four to five uniform nodular densities measuring less than 2 cm in diameter were detected in the left lower lobe. As a result, thoracoabdominal computed tomography angiography (CTA) was performed to determine whether pulmonary nodules were vascular in nature. It revealed a small (8x9x11 mm) pseudoaneurysm in the aortic arch (Figure 1a), however, pulmonary nodules

were not consistent with aneurysms. The patient then underwent positron emission tomography (PET)-CT, which verified that the nodules were pneumonic consolidation. Also, metabolic activity was seen in the area of the pseudoaneurysm, confirming the presence of inflammation (Figure 1b).

On a CTA examination two months after the initial diagnosis, the size of the pseudoaneurysm in the aortic arch increased and progressed into a 25x26x30 mm saccular pseudoaneurysm, although the patient was on immunosuppressive therapy (Figure 2). Therefore, we performed a stent-graft implantation procedure. A Valiant® Captive® stent graft (Medtronic Inc. Minneapolis, MN, US) measuring 32x150 mm was implanted in the lumen of the descending thoracic aorta which overlaid the origin of the left subclavian artery.

Two months after the procedure, repeated CTA confirmed that the aortic arch aneurysm was totally

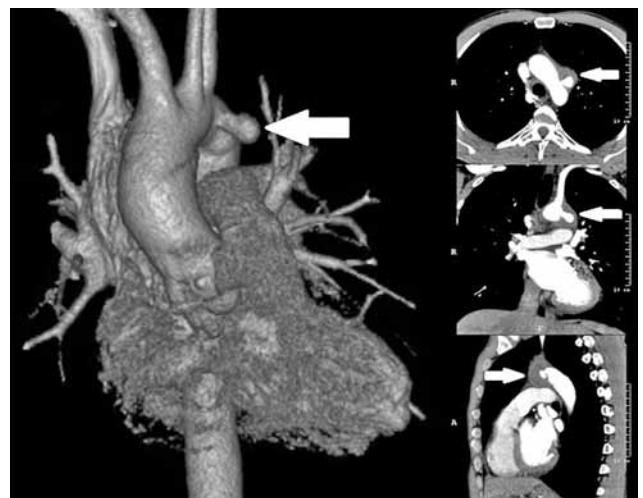

Figure 2. Three-dimensional view via multiplanar reconstruction showing the growing saccular pseudoaneurysm in the aortic arch.

thrombosed and reduced in size. No other pathological findings were observed in the aorta.

During the follow-up period, C-reactive protein (CRP) levels increased to 112-217 mg/L which supported the presence of the vascular complication of BD. Approximately 10 months after the stent grafting, the patient was admitted to the emergency room with massive hemoptysis, and CTA showed a pseudoaneurysm sac formation (8 cm in diameter) surrounding the stent graft in the descending thoracic aorta. In addition, a 1.5 cm saccular pseudoaneurysm proximal to the stent graft and a 2 cm saccular pseudoaneurysm formation at the distal landing zone were seen with the complication of an aortobronchial fistula (Figure 3).

We then performed a second endovascular aneurysm repair (EVAR) procedure for the recurrent pseudoaneurysm at the distal landing zone and implanted a second stent graft (36x150 mm) (Bolton Relay Plus®, Bolton Medical Inc., Sunrise, FL, USA) throughout the first one at the diaphragmatic level. Both of the endovascular procedures were performed with spinal anesthesia under conscious sedation. No complication was observed. As arch pseudoaneurysms necessitate a hybrid repair procedure, surgery was carried out after the suppression of the active inflammatory course.

Repeated CTA at three months showed that the recurrent aneurysm at the distal landing zone of of

the stent graft which was treated previously was thrombosed and regressed, whereas the one at the proximal site progressed to 18x20x21 mm in size (Figure 4).

DISCUSSION

Of all the vascular lesions, aneurysms are the most complicated and challenging vascular pathologies associated with BD due to the technical difficulties for vascular surgeons and the high incidence of anastomotic and new-onset aneurysms.^[8,9] An aortoenteric fistula and graft occlusion are other serious complications of surgery that may be seen in abdominal aortic reconstruction of BD.^[10]

The aneurysm-related mortality rate with EVAR is between 10 and 30%, while recurrent pseudoaneurysms at anastomotic sites develop in 10 to 50% of patients.^[7] Kwon et al.^[2] reported that the overall recurrence rate of abdominal aortic aneurysms after surgical treatment was 38.1%. Furthermore, investigating the complications associated with vascular surgery in 24 patients, Tüzün et al.^[3] reported that anastomotic aneurysms occurred in four patients and other various complications were noted as well.

The combined morbidity (for anastomotic pseudoaneurysm, in particular) and mortality of BD patients after EVAR is low.^[11] However, in a study including five patients who underwent stent grafting for

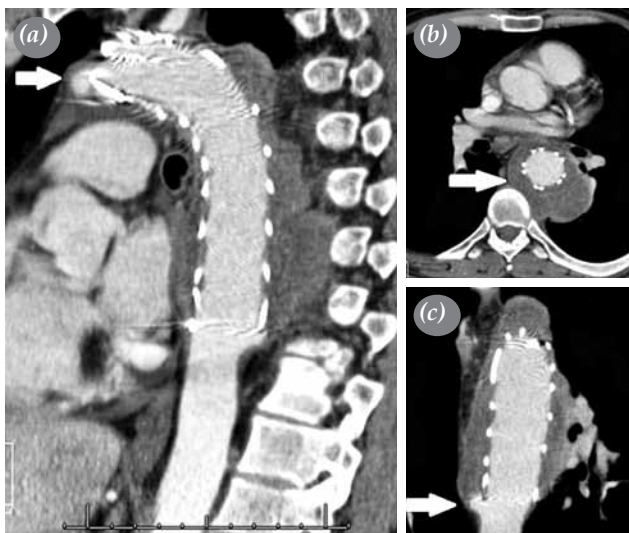


Figure 3. Computed tomographic angiography showing (a) the saccular pseudoaneurysm proximal to the stent graft, (b) the pseudoaneurysm sac formation surrounding the stent graft in the descending thoracic aorta, and (c) the saccular pseudoaneurysm formation at the distal landing zone of the stent graft, which was complicated by an aortobronchial fistula.

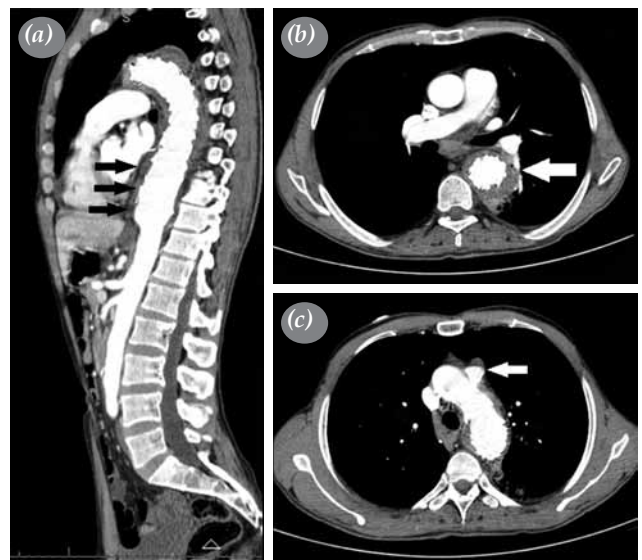


Figure 4. Repeated computed tomographic angiography showing (a and b) the progression of the pseudoaneurysm sac formation inferiorly surrounding the second stent graft in the descending thoracic aorta and (c) the progression in size of the saccular pseudoaneurysm proximal to the first stent graft.

an original lesion (one patient) and recurrent aneurysms (n=4), Kwon et al.^[2] found recurrent aneurysms at the site proximal or distal to the stent graft in two patients who were previously thought to have normal aortas (40% of the recurrence rate).

Ishikawa et al.^[12] reported a case of BD in which they successfully treated an infrarenal abdominal aortic aneurysm with stent grafting, however, the patient presented with a new aneurysm at the proximal site of the stent graft 10 months after the initial procedure.

Furthermore, in a prospective study including seven BD patients with nine aneurysms after stent grafting, Park et al.^[5] reported that the aneurysms resolved and completely regressed in four patients and completely disappeared in other two. Nonetheless, a total occlusion of the artery with a stent occurred in one of their patients, and a recurrent aneurysm developed at the distal margin of the stent graft in another after 10 months. In addition, Kwon Koo et al.^[13] found a recurrent aneurysm in two of 11 patients who were treated with EVAR Erpenbach et al.^[14] suggested that vessel injuries caused by stent grafts or by manipulations during the stent-grafting procedure may trigger the inflammatory process, thereby, leading to aforementioned complications.

Furthermore, some authors have insisted that establishing remission by the use of glucocorticoids before the surgical intervention may decrease the incidence of postoperative anastomotic complications.^[15,16] Kwon et al.^[2] suggested that adequate immunosuppressive treatment may decrease the risk of recurrent aneurysms. Ishikawa et al.^[12] also hypothesized that in spite of the use of oral corticosteroids, elevated CRP levels and an increased white blood cell count may induce recurrent aneurysms at the landing zones of a stent graft.

In our case, although the patient received immunosuppressive treatment, CRP levels were higher. We found that the ineffective immunosuppression resulted in the development of recurrent pseudoaneurysms all around the stent graft and at the proximal and distal ends. Our experience with this patient suggests that PET-CT in conjunction with laboratory tests to obtain the erythrocyte sedimentation rate and CRP and ferritin levels, may be effective in establishing the efficiency of immunosuppressive treatment. Furthermore, PET-CT may detect the inflammatory activity in the artery wall, as it did in our case, which is a predictor of a pseudoaneurysm. Supporting our suggestion, a recent study by Kim et al.^[17] reported that PET-CT

revealed a bilateral pulmonary artery aneurysm in a patient with BD.

Conclusion

The postoperative complication rates associated with open surgery in patients with BD such as graft occlusions or anastomotic pseudoaneurysm formation are considerably higher than with EVAR. While endovascular stent grafting may provide a feasible and safe alternative to surgery, it may not be a definitive treatment. It is evident that there is a comparatively low risk with this procedure, however, there is an ongoing risk of developing recurrent pseudoaneurysms. An effective immunosuppression is a must to prevent such complications. Therefore, we recommend PET-CT as an appropriate modality for assessing the disease activity and identifying inflammation in the artery wall probably originating from associated complications. Furthermore, further studies are needed to determine the outcome in patients treated with endovascular stent grafting as well as to tailor the optimal medication which should be prescribed. Long-term follow-up is also recommended.

Declaration of conflicting interests

The authors declared no conflicts of interest with respect to the authorship and/or publication of this article.

Funding

The authors received no financial support for the research and/or authorship of this article.

REFERENCES

1. Tohmé A, Aoun N, El-Rassi B, Ghayad E. Vascular manifestations of Behçet's disease. Eighteen cases among 140 patients. *Joint Bone Spine* 2003;70:384-9.
2. Kwon TW, Park SJ, Kim HK, Yoon HK, Kim GE, Yu B. Surgical treatment result of abdominal aortic aneurysm in Behçet's disease. *Eur J Vasc Endovasc Surg* 2008;35:173-80.
3. Tüzün H, Beşirli K, Sayin A, Vural FS, Hamuryudan V, Hizli N, et al. Management of aneurysms in Behçet's syndrome: an analysis of 24 patients. *Surgery* 1997;121:150-6.
4. Vasseur MA, Haulon S, Beregi JP, Le Tourneau T, Prat A, Warembourgh H. Endovascular treatment of abdominal aneurysmal aortitis in Behçet's disease. *J Vasc Surg* 1998;27:974-6.
5. Park JH, Chung JW, Joh JH, Song SY, Shin SJ, Chung KS, et al. Aortic and arterial aneurysms in behçet disease: management with stent-grafts--initial experience. *Radiology* 2001;220:745-50.
6. Bonnotte B, Krause D, Fanton AL, Theron J, Chauffert B, Lorcerie B. False aneurysm of the internal carotid artery in Behçet's disease: successful combined endovascular

- treatment with stent and coils. *Rheumatology (Oxford)* 1999;38:576-7.
7. Liu CW, Ye W, Liu B, Zeng R, Wu W, Dake MD. Endovascular treatment of aortic pseudoaneurysm in Behçet disease. *J Vasc Surg* 2009;50:1025-30.
 8. Sener E, Bayazit M, Göl MK, Mavitas B, Tasdemir O, Bayazit K. Surgical approach to pseudoaneurysms with Behçet's disease. *Thorac Cardiovasc Surg* 1992;40:297-9.
 9. Sasaki Sh, Yasuda K, Takigami K, Shiiya N, Matsui Y, Sakuma M. Surgical experiences with peripheral arterial aneurysms due to vasculo-Behçet's disease. *J Cardiovasc Surg (Torino)* 1998;39:147-50.
 10. Ozguc H, Topal NB, Topal E. Secondary aortoenteric fistula in a patient with Behçet disease: successful surgical treatment by direct suture and use of omental flap. *Vascular* 2008;16:300-2.
 11. Nitecki SS, Ofer A, Karram T, Schwartz H, Engel A, Hoffman A. Abdominal aortic aneurysm in Behçet's disease: new treatment options for an old and challenging problem. *Isr Med Assoc J* 2004;6:152-5.
 12. Ishikawa S, Kawasaki A, Suzuki Y, Neya K, Wada S, Kugawa S, et al. Progression of abdominal aortic aneurysm after endovascular stent-grafting in a patient with Behçet's disease: report of a case. *Surg Today* 2007;37:82-5.
 13. Kwon Koo B, Shim WH, Yoon YS, Kwon Lee B, Choi D, Jang Y, et al. Endovascular therapy combined with immunosuppressive treatment for pseudoaneurysms in patients with Behçet's disease. *J Endovasc Ther* 2003;10:75-80.
 14. Erpenbach S, Arlart IP, Tremmel-Lehnert C, Hupp T. Abdominal aortic aneurysm in Behçet's disease: treatment with endovascular stent graft. *Eur Radiol* 2001;11:2539-42.
 15. Kalko Y, Basaran M, Aydin U, Kafa U, Basaranoglu G, Yasar T. The surgical treatment of arterial aneurysms in Behçet disease: a report of 16 patients. *J Vasc Surg* 2005;42:673-7.
 16. Denecke T, Staeck O, Amthauer H, Hänninen EL. PET/CT visualises inflammatory activity of pulmonary artery aneurysms in Behçet disease. *Eur J Nucl Med Mol Imaging* 2007;34:970.
 17. Kim WH, Choi D, Kim JS, Ko YG, Jang Y, Shim WH. Effectiveness and safety of endovascular aneurysm treatment in patients with vasculo-Behçet disease. *J Endovasc Ther* 2009;16:631-6.