

## Is there a novel alternative advantageous technique for closure of thoracotomy?

*Torakotomiyi kapatmada yeni bir avantajlı alternatif yöntem var mıdır?*

**Murat Öncel, Güven Sadi Sunam, Hüseyin Yıldırım**

Department of Thoracic Surgery, Selçuk University, Medical Faculty of Selçuklu, Konya, Turkey

Thoracotomy is a commonly used approach for thoracic cavity exploration for lung and cardiac procedures. There are many causes of poor closure including infection, pain, weak tissue or muscle at the wound site, injury to the wound area, and other factors. In this article, we describe a novel technique for the closure of thoracotomy. The advantages of our technique are simplicity, speed, effectiveness, and using lesser sutures in closing the thorax.

*Key words:* Closing thoracotomy; novel technique; post-thoracotomy pain; suture.

One of the most important considerations in the care of thoracic surgery patients is the proper closure of a thoracotomy since this prevents pain, chondritis, subcutaneous emphysema, and dehiscence.<sup>[1]</sup> Herein, we describe an alternative technique for closing a thoracotomy.

### TECHNIQUE DESCRIPTION

When carrying out a muscle-sparing thoracotomy at our facility, the surgery is performed, and the thoracotomy is closed under general anesthesia in the posterolateral position. First, the intercostal area is released, and the inferior costa is raised to prevent nerve injury. However, this region is not sutured for the closing. The double-layered loop polydioxanone material is then placed in the upper costal region, thus bypassing the lower rib, and both the inside and outside of the thorax are closed by crossing the sutures over each other (Figure 1). The advantage of our technique

Torakotomi, pulmoner ve kardiyak işlemlerdeki göğüs boşluğu eksplorasyonu için sık kullanılan bir yaklaşımdır. Yetersiz kapamanın enfeksiyon, ağrı, yara bölgesinde zayıf doku veya kas, yara alanında hasarlanma ve diğer faktörler gibi birçok nedeni vardır. Bu yazıda, torakotomi kapatılması için yeni bir teknik tanımlandı. Tekniğimizin avantajları basitlik, hız, etkinlik ve toraks kapatılmasında daha az dikiş kullanılmasıdır.

*Anahtar sözcükler:* Torakotomi kapatılması; yeni teknik; torakotomi sonrası ağrısı; dikiş.

lies in its simplicity, speed, effectiveness, and the use of fewer sutures.

### DISCUSSION

A thoracotomy is a commonly used approach for thoracic cavity exploration as well as lung and cardiac procedures. There are many etiologies, including infection, pain, weak tissue or muscles at the wound site, and injury to the wound area as well as other factors that are frequently associated with poor closure techniques.<sup>[2]</sup> In the traditional technique, circumcostal sutures are placed around the ribs on the cranial and caudal side of the thoracotomy; hence, the caudal neurovascular bundles are likely to be trapped between the suture and caudal rib. Closure of the incision begins by inserting one or two chest tubes followed by the placement of pericostal sutures, which are usually made of heavy absorbable material such as No. 2 polyglycolic acid. The rib spaces are then

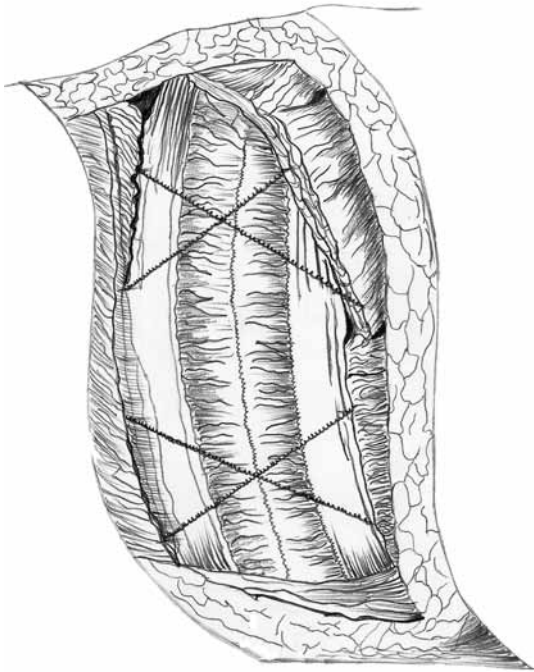


Available online at  
www.tgkdc.dergisi.org  
doi: 10.5606/tgkdc.dergisi.2014.8917  
QR (Quick Response) Code

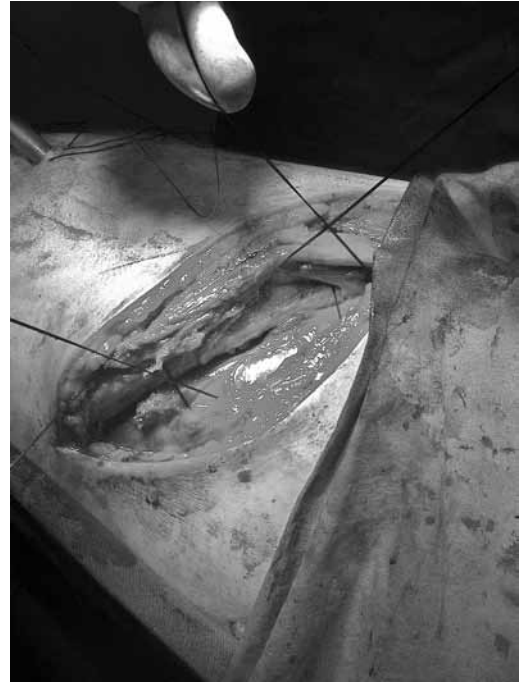*Received:* June 18, 2013 *Accepted:* September 16, 2013

Correspondence: Murat Öncel, M.D. Selçuk Üniversitesi Tıp Fakültesi Göğüs Cerrahisi Anabilim Dalı, 42131 Selçuklu, Konya, Turkey.

Tel: +90 535 - 223 40 68 e-mail: moncel01@hotmail.com



**Figure 1.** Demonstration of our alternative technique for closing a thoracotomy.



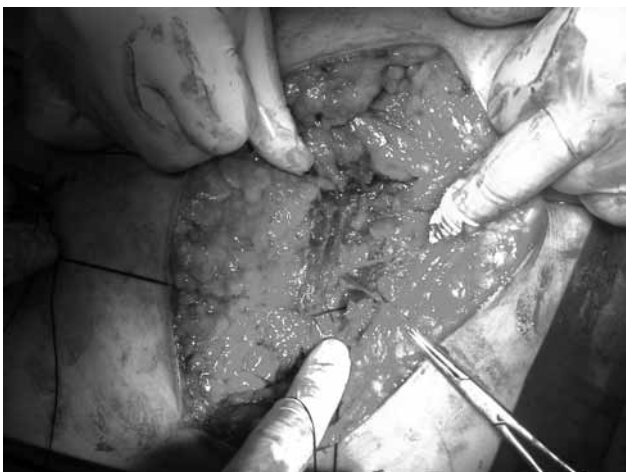**Figure 2.** The thoracotomy was closed using crossed sutures.

reapproximated to their original position, and care is taken not to overcorrect, even when a rib has been resected. Blum and Fry<sup>[3]</sup> also advocate intercostal suture placement through holes drilled in the lower rib because this may minimize intercostal nerve injury and decrease postoperative pain associated with the transected muscles, spreading of the ribs, and neurovascular compression with sutures during closure.<sup>[4-7]</sup> In addition, the possibility of neurovascular entrapment and intercostal arterial lacerations should also be considered with the traditional circumcostal

thoracotomy closure technique. Furthermore, if the thoracotomy is not be closed properly, coughing and clearing of the secretions may be compromised, which can lead to possible bronchial obstruction, atelectasis, and/or a lung infection.

We performed our new technique in 163 patients with intrathoracic disease. Patient-controlled analgesia was not routinely used, but intravenous paracetamol was given four times per day for three days. Only four patients required an additional analgesic. No thoracic dehiscence was encountered, but there were two cases of superficial wound infection that were successfully treated with antibiotics. One of the cases involved a 55-year-old man with lung cancer who had undergone a right pneumonectomy. In the late postoperative period, external cardiac massage was applied for 20 minutes, and he stayed on mechanical respiratory support for seven days afterwards. At that time there was no thoracic dehiscence or major wound complication, which we believe was related to the technique that we employed.

Using our alternative technique to close thoracotomies essentially avoids the possibility of flail, dehiscence, infections, and subcutaneous emphysema while significantly decreasing acute post-thoracotomy pain, increasing pulmonary function, and promoting the early discharge of patients from the hospital.



**Figure 3.** The closed thoracotomy.

### **Declaration of conflicting interests**

The authors declared no conflicts of interest with respect to the authorship and/or publication of this article.

### **Funding**

The authors received no financial support for the research and/or authorship of this article.

### **REFERENCES**

1. Bayram AS, Ozcan M, Kaya FN, Gebitekin C. Rib approximation without intercostal nerve compression reduces post-thoracotomy pain: a prospective randomized study. *Eur J Cardiothorac Surg* 2011;39:570-4.
2. Ridderstolpe L, Gill H, Granfeldt H, Ahlfeldt H, Rutberg H. Superficial and deep sternal wound complications: incidence, risk factors and mortality. *Eur J Cardiothorac Surg* 2001;20:1168-75.
3. Blum MG, Fry AW. Thoracic incisions. In: Shields TW, Locicero III J, Reed CE, Feins RH, editors. *General Thoracic Surgery*. 7th ed. Philadelphia: Lippincott Williams & Wilkins; 2009. p. 391-9.
4. Ferrante FM, Chan VW, Arthur GR, Rocco AG. Intercostal analgesia after thoracotomy. *Anesth Analg* 1991;72:105-9.
5. Cerfolio RJ, Price TN, Bryant AS, Sale Bass C, Bartolucci AA. Intercostal sutures decrease the pain of thoracotomy. *Ann Thorac Surg* 2003;76:407-11.
6. Karmakar MK, Ho AM. Postthoracotomy pain syndrome. *Thorac Surg Clin* 2004;14:345-52.
7. Rogers ML, Duffy JP. Surgical aspects of chronic post-thoracotomy pain. *Eur J Cardiothorac Surg* 2000;18:711-6.