

## Effects of hyperbaric oxygen treatment on cartilage regeneration: an experimental study

*Hiperbarik oksijen tedavisinin kırıkta rejenerasyonu üzerine etkileri: Deneysel çalışma*

Burçin Çelik,<sup>1</sup> Mehmet Kefeli,<sup>2</sup> Hale Kefeli Çelik,<sup>3</sup> Ömer Serdar Bekdemir,<sup>1</sup> Evin Koç Gülen<sup>4</sup>

*Institution where the research was done:*

Medical Faculty of Ondokuz Mayıs University, Samsun, Turkey

*Author Affiliations:*

Departments of <sup>1</sup>Thoracic Surgery and <sup>2</sup>Pathology, Medical Faculty of Ondokuz Mayıs University, Samsun, Turkey

<sup>3</sup>Department of Anaesthesiology and Reanimation, Samsun Training and Research Hospital, Samsun, Turkey

<sup>4</sup>Special Baroclinic Oxygen Therapy Center, Samsun, Turkey

### ABSTRACT

**Background:** This experimental study evaluated possible effects of hyperbaric oxygen treatment on cartilage regeneration in the perichondrial bed of costal cartilage in a rabbit model.

**Methods:** Twenty-four New Zealand rabbits were divided into four groups, each of which included six rabbits. The third and fourth costal cartilages in both hemithoraces were excised totally in all groups. The perichondrial beds were closed at both hemithoraces, but reshaped cartilages were implanted into the left hemithorax. Group 1 and group 2 were selected as control groups. After surgery, groups 3 and 4 received hyperbaric oxygen treatment of 2.5 ATA pressure once a day for one week. The rabbits in groups 1 and 3 were sacrificed at the fourth week and in groups 2 and 4 at the eighth week after the operation. A numerical scoring scheme modified from histological evaluations of fracture healing was used to assess the neocondrogenesis and scar tissue formation. Histopathological scoring was made according to the amount of fibrous tissue and cartilage in perichondrial bed for each specimen.

**Results:** According to the numerical scoring scheme, the score of left perichondrial bed was significantly higher for group 4, compared to the other groups ( $p=0.027$ ). However, it was not significant in the right perichondrial bed ( $p=0.063$ ). The differences in the diameter of the newly developed cartilage was not significant among the groups ( $p>0.05$ ).

**Conclusion:** Our study indicated that receiving postoperative hyperbaric oxygen treatment increased the chondrogenesis in the perichondrial bed in rabbits, which is very important to obtain a flexible and stable chest wall after the correction of pectus deformities.

**Keywords:** Cartilage; chest wall; hyperbaric oxygen treatment; pectus deformity; regeneration.

### ÖZ

**Amaç:** Bu deneysel çalışmada bir tavşan modelinde hiperbarik oksijen tedavisinin perikondriyal yatakta bulunan kırıkta rejenerasyonuna olan muhtemel etkileri değerlendirildi.

**Çalışma planı:** Yirmi dört Yeni Zelanda tavşanı, her birinde altı tavşan olmak üzere, dört gruba ayrıldı. Tüm gruplarda, her iki hemitorakstaki üçüncü ve dördüncü kostal kırıkta tamamen çıkarıldı. Her iki hemitorakstaki perikondriyal yataklar kapatıldı; ancak sol hemitoraksta, yeniden şekillendirilen kırıkta grefti yerleştirildi. Grup 1 ve grup 2 kontrol grupları olarak seçildi. Grup 3 ve 4'e, cerrahi sonrası bir hafta boyunca günde bir kez 2.5 ATA basınç altında hiperbarik oksijen tedavisi uygulandı. Cerrahi sonrası grup 1 ve 3'deki tavşanlar ameliyat sonrası dördüncü haftada ve grup 2 ve 4'deki tavşanlar ameliyat sonrası sekizinci haftada sakrifiye edildi. Neokondrogenez ve skar doku oluşumunu değerlendirmek için, kırık iyileşmesinin histolojik değerlendirilmesinden modifiye edilmiş sayısal puanlama sistemi kullanıldı. Histopatolojik puanlama, her bir örnek için perikondriyal yataktaki fibröz doku ve kırıkta miktarına göre yapıldı.

**Bulgular:** Sayısal puanlama şemasına göre, grup 4'ün sol perikondriyal yataktaki puanı, diğer gruplarla karşılaştırıldığında, anlamlı olarak yüksekti ( $p=0.027$ ). Ancak, bu sağ perikondriyal yatakta anlamlı değildi ( $p=0.063$ ). Gruplar arasında yeni oluşan kırıkta çapları açısından anlamlı bir farka rastlanmadı ( $p>0.05$ ).

**Sonuç:** Çalışmamız tavşanlarda, cerrahi sonrası hiperbarik oksijen tedavisi uygulamasının pektus deformitelerinin düzeltilmesinden sonra esnek ve stabil bir göğüs duvarı elde etmek için çok önemli olan, perikondriyal yataktaki kondrogenezi artırdığını gösterdi.

**Anahtar sözcükler:** Kırıkta; göğüs duvarı; hiperbarik oksijen tedavisi; pektus deformitesi; rejenerasyon.



Available online at  
www.tgkdc.dergisi.org  
doi: 10.5606/tgkdc.dergisi.2015.9657  
QR (Quick Response) Code

Received: December 10, 2013 Accepted: April 12, 2014

Correspondence: Burçin Çelik, M.D. Ondokuz Mayıs Üniversitesi Tıp Fakültesi Göğüs Cerrahisi Anabilim Dalı, 55139 Samsun, Turkey.

Tel: +90 505 - 724 24 13 e-mail: cburcin@hotmail.com

Pectus excavatum (PE) and pectus carinatum (PC) are the two most common congenital anterior chest wall deformities. Pectus excavatum is characterized by the posterior depression of the middle and lower parts of the sternum and the posterior curvature of the related costal cartilages; whereas PC is a congenital anomaly characterized by sternal protrusion due to frontal inclinations of the middle and lower parts of the sternum and the related costal cartilages. Furthermore, PE occurs in 1/300-1/400 live births, but PC is seen seven times less frequently.<sup>[1-3]</sup>

The usual treatment for congenital anterior chest wall deformities is surgery, with correction being performed using either open or minimally invasive techniques. In open surgery, the deformity is corrected by the subperichondrial removal of the cartilage structures that are causing the deformity. After performing a transverse sternal osteotomy, the surgery is completed by either transsternal fixation, the application of an episternal plate, or placement of material under the sternum.<sup>[1,4,5]</sup> Ensuring effective cartilage regeneration in the early period is important for stabilizing the chest wall, preventing possible complications (e.g., postoperative chest pain, sternocostal/costocostal instability, or pseudarthroses), and providing chest wall flexibility.

In the literature, there are studies that have focused on the effectiveness of hyperbaric oxygen treatment (HBOT) as it relates to the regeneration of cartilage and bone tissues and the healing of tracheal anastomosis.<sup>[6-10]</sup> In practice, hyperbaric oxygen has also been successfully employed in the treatment of chest wall radionecrosis.<sup>[11,12]</sup> However, there is insufficient data in the literature regarding cartilage regeneration and growth after the resection of the deformed cartilages on the chest wall.

The purpose of this experimental study was to investigate the effects of HBOT on cartilage regeneration in the perichondrial bed of costal cartilage in a rabbit model.

## MATERIALS AND METHODS

This randomized, controlled, non-blinded, interventional animal study was conducted at the Animal Laboratory and Research Center of Ondokuz Mayıs University with the approval of the Ethics Committee for Animal Research. Twenty-four young New Zealand rabbits (age 10-12 weeks; weight 1500-2000 g) that were bred in the university laboratory were used in this study. The animals were kept under the natural day/night cycle at room temperature and were allowed to eat standard pellet feed and drink water *ad libidum*.

## Experimental protocol

The rabbits were divided into four groups containing six rabbits each, and they were sacrificed at either the fourth or eighth postoperative weeks. Groups 1 and 2 served as the control groups while groups 3 and 4 received HBOT after the surgery. While the third and fourth costal cartilages on the right and left sides were removed, the costochondral junctions were saved in all of the groups. In addition, the perichondrium on the right side of each rabbit was closed immediately after the surgery, but on the left side, it was closed after the reimplantation of the reshaped cartilages.

## Anesthesia and surgical procedure

The animals were anesthetized via the intraperitoneal administration of 40 mg/kg of ketamine hydrochloride (Ketalar®, 50 mg/mL, Pfizer, Istanbul, Turkey) and 5 mg/kg of xylazine (Rompun® 2% solution, 50 mL, Bayer Türk Kimya San. Ltd. Şti., Istanbul, Turkey). The operations were performed under general anesthesia with surgical loupes and a microsurgical set. The animal was first placed in the supine position, and a mid-sternal skin incision was made. The pectoral muscles were then carefully dissected to expose the costal cartilages, and the subperichondrial costal cartilage resections were performed. Afterwards, the perichondrial beds were closed with continuous 6/0 the Vicryl Rapide™ polyglactin 910 absorbable sutures (Vicryl; Ethicon, Somerville, NJ, USA) on the right hemithorax, and the reshaped cartilages were reimplanted into the left hemithorax. Next, the pectoral muscles were approximated with Vicryl Rapide™ 3/0 polyglactin 910 absorbable sutures (Vicryl; Ethicon, Somerville, NJ, USA), and the skin was closed with 2/0 polypropylene sutures (Prolene, Johnson & Johnson Medical N.V/S.S., Diegem, Belgium). All of the rabbits were also given sefazolin sodium intramuscularly (30 mg/kg of body weight).

## Hyperbaric oxygen treatment

Groups 3 and 4 underwent HBOT starting at the postoperative 24<sup>th</sup> hour in a Hiper Tech Zyron hyperbaric chamber (Hiper Tech Hyperbaric Systems Manufacturing, Ltd., Istanbul, Turkey). We designed a system to simulate the hoods in clinical use and put the caged animals in locked, airproof, soft plastic bags that had supply and exhaust hoses. Through this system, the rabbits were able to breathe 100% oxygen (Figure 1). Each group received one session of HBOT [100% oxygen with an absolute pressure (ATA) of 2.5 ATA for 90 minutes with a compression/decompression rate of 0.15 ATA/min] for seven days. Every session had three steps. In the first step, the rabbits were compressed at



**Figure 1.** Photograph showing the rabbits receiving hyperbaric oxygen treatment.

a rate of 0.15 ATA/min for 10 minutes. The rabbits then received 100% oxygen at an ATA of 2.5 for 90 minutes. During these sessions, the hyperbaric chamber was flushed with 100% oxygen to prevent carbon dioxide (CO<sub>2</sub>) retention. In the third step, the rabbits were decompressed at a rate of 0.15 ATA/min as described elsewhere.<sup>[9,10]</sup>

**Histopathological evaluation**

The neochondrogenesis on the perichondrial beds of the resected costal cartilages were evaluated at the fourth and eighth postoperative weeks. All tissues were fixed with 10% formalin solution, and demonstrative sample tissues were then taken from each chest wall. In addition, all of the specimens were stained with hematoxylin and eosin (H-E), and the sections were studied under a Zeis Axiophot microscope (Carl Zeiss Microscopy GmbH, Göttingen, Germany) to examine the neochondrogenesis, scar tissue, and diameter of the new cartilage. We then used a numerical scoring scheme, which had been modified from histological evaluations of fracture healing, to assess the neochondrogenesis and scar tissue formation. The scores ranged from 0-5 and were assigned to each specimen based on the amount of fibrous tissue and cartilage in the perichondrial bed. This semi-quantitative scoring system is summarized in Table 1.<sup>[13]</sup>

The diameters of the cartilages were determined planimetrically. First, the cartilage images obtained under 40x magnification under the microscope were computerized with a digital camera (Insight Diagnostic Instrument, USA) designed to be used in morphometric studies. Then these images were evaluated via a morphometric analysis software program (Samba Technologies 2005, Morphometry Analysis, France). After this, the coronal and sagittal diameters of the cartilages for each section were determined morphometrically using the images that had been transferred to the computer monitor. Next,

the pathological sections were assessed under the microscope using a semi-quantitative scoring system. The same pathologist, who was blinded to the study groups, evaluated all of the tissue samples.

**Statistical analysis**

The data was analyzed using the SPSS version 15.0 for Windows software program (SPSS, Chicago, IL, USA). The microscopic findings and new cartilage diameters were calculated for each group using mean ± standard deviation (SD). In addition, chi-square and Tukey’s honestly significant difference (HSD) tests were used to compare the mean scores of the groups. A *p* value of <0.05 was considered to be statistically significant.

**RESULTS**

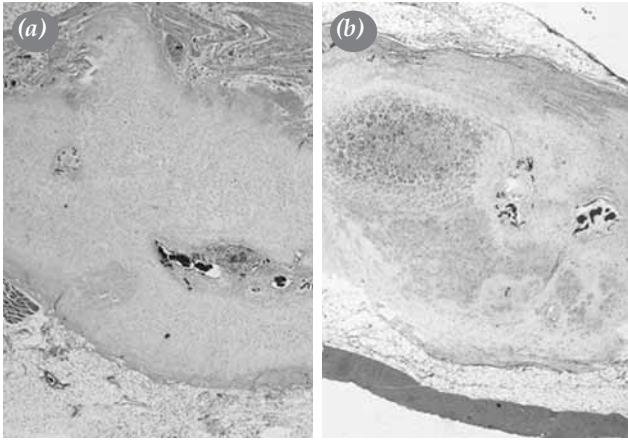
All of the rabbits survived the study period. When groups 1 and 2 were compared with groups 3 and 4, the differences in the scores in the right hemithorax were not statistically significant (*p*=0.063) (Figures 2 and 3). However, when the scores in the left perichondrial bed were compared, we found that they were significantly higher for group 4 than for group 2 (*p*=0.007). We also determined that there were no statistically significant differences between the scores in groups 1 and 3 (*p*=1) (Table 2).

The mean diameter of the new cartilages on the right hemithorax for groups 1, 2, 3 and 4 were 3.08±0.72, 3.6±0.78, 3.4±0.25, and 3.8±0.43 mm, respectively, and no statistically significant differences were present between the control groups and the HBOT groups at the postoperative fourth week (groups 1 and 3; *p*=0.793) or the postoperative eighth week (groups 2 and 4; *p*=0.972) (Table 3).

The mean diameter of the new cartilages in the left hemithorax for groups 1, 2, 3 and 4 were 3.3±0.75, 3.9±0.51, 3.7±0.62, and 3.8±0.52 mm, respectively.

**Table 1. The numerical scoring scheme used for the histopathological evaluation of the perichondrial bed<sup>[13]</sup>**

Score	Histopathological findings in the perichondrial bed
1	Fibrous tissue
2	Predominantly fibrous tissue with a small amount of cartilage
3	Equal mixture of fibrous tissue and cartilaginous tissue
4	Predominantly cartilage with a small amount of fibrous tissue
5	Cartilage



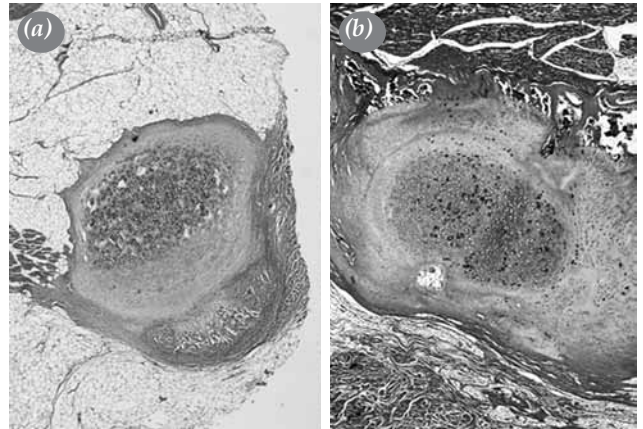
**Figure 2.** Microscopic view showing the cartilage tissue formation within the fibroadipose tissue. (a) Group 1, (b) group 3 (H-E x 40).

In addition, we found no statistically significant differences in the diameters between the control groups and the HBOT groups at the postoperative fourth week (groups 1 and 3;  $p=0.583$ ) or the postoperative eighth week (groups 2 and 4;  $p=0.956$ ) (Table 3).

**DISCUSSION**

Pectus excavatum is the most common congenital deformity of the anterior chest wall, and it results from the posterior depression of the sternum together with abnormally developed costal cartilages. Surgery is based on social status and self-limiting aesthetic concerns as well as the presence of cardiac and respiratory problems.<sup>[2,3,14]</sup>

Surgery is the main treatment option for patients with a pectus deformity. The first PE surgeries were



**Figure 3.** Microscopic view showing the cartilage graft in the soft tissue and the new cartilage tissue around it. (a) Group 2, (b) group 4 (H-E x 40).

performed by Meyer<sup>[14]</sup> in 1911 and by Sauerbruch<sup>[16]</sup> in 1913. Ravitch<sup>[17]</sup> performed his first operation in 1947, and since that time more than 50 surgical treatment methods have been defined.<sup>[14]</sup> Recently, minimally invasive procedures have become a viable alternative to pectus correction surgeries, which are usually done for cosmetic reasons. In 1987, at the time that laparoscopic and minimally invasive surgeries were beginning to be performed, Dr. Donald Nuss<sup>[18]</sup> first used a minimally invasive surgical method to treat PE. In fact, the minimally invasive Nuss technique and the Ravitch technique, which has been modified over time, and are still the most popular surgical options used today.

In this type of surgery, the first step is to remove the deformed cartilages and then put the sternum and chest

**Table 2. Microscopic evaluation (score 0-5)**

Groups	Right hemithorax		Left hemithorax	
1: Surgery at 4 weeks	3.3±0.5	} 0.063	3.5±0.5	} 0.027
2: Surgery at 8 weeks	3.6±0.5		3.3±0.8	
3: Surgery + HBOT at 4 weeks	4.0±0.6		3.5±0.5	
4: Surgery + HBOT at 8 weeks	4.1±0.4		4.0±0.0	

HBOT: Hyperbaric oxygen treatment.

**Table 3. Comparison of the diameter of new cartilage**

Groups	Right hemithorax (mm)		Left hemithorax (mm)	
1: Surgery at 4 weeks	3.1±0.7	} 0.243	3.3±0.8	} 0.339
2: Surgery at 8 weeks	3.6±0.8		3.9±0.5	
3: Surgery + HBOT at 4 weeks	3.4±0.3		3.7±0.6	
4: Surgery + HBOT at 8 weeks	3.8±0.4		3.8±0.5	

HBOT: Hyperbaric oxygen treatment.

wall back into their normal positions. After correcting the chest deformity surgically, the chest wall loses cartilage and bone support, leading to stabilization problems. Therefore, patients should be protected against traumas and should be kept away from forceful body movements and sports for three to six months. In these cases, the regeneration of the cartilage in the early period is essential for stabilizing the chest wall and preventing complications which could develop in the late period, such as sternocostal or costocostal pseudarthroses. In studies specifically carried out on PE patients with respiratory and cardiac problems, it was determined that after open surgical treatment, pulmonary functions may increase in the early period. However, this increase does not last, and a decrease may even occur in the late period. This situation can be attributed to the decrease in chest wall compliance after surgery.<sup>[19-21]</sup>

In HBOT, patients receive high concentrations of oxygen under pressure to increase the oxygen level in the blood and tissues. This procedure has been widely used to support the treatment of chronic wounds such as diabetic ulcers, necrotizing soft tissue infection, tissue damage related to radiation, refractory osteomyelitis, sternal infection, tissue grafts and flaps, and sports injuries.<sup>[11,12]</sup> The physiological effects of HBOT include improved oxygenation, the promotion of neovascularization, increased antimicrobial activity, a modulation in inflammation, enhanced wound healing via the activation of fibroblasts, and angiogenesis.<sup>[22]</sup>

Cartilage is composed of chondrocytes, an avascular extracellular matrix of collagen fibers, and connective tissue formed by specialized cells (e.g., bone cells). Normal cartilage is hypocellular and avascular, with nourishment occurring via passive diffusion through the perichondrium. Cartilage can be classified into three groups: hyaline cartilage, elastic cartilage, and fibrocartilage. Hyaline cartilage is the most common type and is found at the tips of the ribs, in the trachea and bronchial rings, and in the larynx of the adults.<sup>[23]</sup> The repair process associated with full-thickness cartilage after a resection starts with local bleeding and hematoma formation. This is followed by the migration of mesenchymal stem cells and the transformation of these cells into chondrocytes. The next step involves the proliferation of the chondrocytes, and the process then ends with type 1 collagen synthesis and the filling of the defect with fibrocartilage.<sup>[24]</sup>

It has been shown in many clinical trials that HBOT is an important clinical treatment choice for the repair or regeneration of damaged tissues. Chergn

et al.<sup>[22]</sup> reported in their study that HBOT performed under an ATA pressure of 2.5 caused an increase in cartilage tissue. In addition, Ueng et al.<sup>[25]</sup> detected that oxygen plays an important role in the production of the extracellular matrix of collagen fibers and in osteochondral regeneration after cartilage damage. They also found that HBO increases heat shock protein 70 (HSP70) expression and that it inhibits nitric oxide (NO)-induced apoptosis in both *in vivo* and *in vitro* studies. Accordingly, they also stated that HBOT can be used clinically in cartilage repair but that its effect should be verified in human chondrocytes.

Both clinical and basic studies have demonstrated that HBOT increases collagen formation and neovascularization in damaged tissues. When the vascular endothelial factors and neovascularization detected in young, growing cartilage have been studied, the results showed that HBOT triggers neovascularization and accelerates osteochondral healing.<sup>[26]</sup> It is also known that HBOT induces angiogenesis and increases collagen synthesis. Furthermore, it directly affects the increase in neovascularization. In addition, Chen et al.<sup>[6]</sup> reported that HBOT can serve as a noninvasive treatment for cartilage repair.

In several studies, it has been shown that scar tissue formation in the perichondrium detected after cartilage resection can prevent new cartilage regeneration and the development of the chest wall.<sup>[21,27,28]</sup> In their study on young rabbits, Calık et al.<sup>[29]</sup> reported that costal cartilage resection is an innocent method and that the removal of the growth centers of the ribs and the resection of four or more cartilages can affect rib cage growth.

Additionally, Sirin et al.<sup>[7]</sup> reported in their study that there was more fibrous connective tissue in the new bone formation in groups which did not undergo HBOT. They also observed that HBOT decreased fibrous tissue formation significantly in rats sacrificed at the first and second weeks and that it had a favorable effect on bone regeneration in rats sacrificed at the first, second, and fourth weeks.

Yuan et al.<sup>[30]</sup> conducted a study on rabbits to investigate chondrocytes in cartilage and demonstrated that HBOT attenuates the apoptosis and enhances proteoglycan synthesis by suppressing NO production. However, further animal studies are needed to verify the influence of hyperbaric oxygenation on intervertebral disc degeneration.

In our experimental study, we observed better healing in the cartilage beds and improved formation of new cartilage in the HBOT groups (groups 3 and 4);

however, this could not be demonstrated statistically. A statistical difference was only observed in group 4, which received cartilage grafts and HBOT. Our data showed that in clinical practice, HBOT also promoted neochondrogenesis and the stabilization of the chest wall in the early period after pectus surgery. Thus, the patients can return to their preoperative activities sooner via this procedure.

Most of the experimental studies published in the literature to date have been related to the effects of HBOT either on cartilage cell cultures or cartilage grafts, or they have investigated the results of surgery performed at sites other than the chest wall. Therefore, our study is of special importance since it was conducted on young rabbits, and the surgical technique applied to the chest wall was the same as the one applied to humans.

### Conclusion

After surgically treating chest deformities, regeneration of cartilage in the early period is vital for stabilizing the chest wall. In this study, HBOT provided increased healing in the cartilage beds and allowed for the formation of new cartilage, although we were unfortunately not able to demonstrate this statistically. Hence, further clinical studies on this issue are needed.

### Acknowledgements

We thank Professor Doctor Yuksel Bek of the Department of Biostatistics at the Medical Faculty of Ondokuz Mayıs University for his statistical analysis and Salih Yilmaz for editing the earlier English version of this manuscript.

### Declaration of conflicting interests

The authors declared no conflicts of interest with respect to the authorship and/or publication of this article.

### Funding

This work was supported by the University Scientific Research Foundation (PYO.TIP.1901.10.005).

## REFERENCES

- Williams AM, Crabbe DC. Pectus deformities of the anterior chest wall. *Paediatr Respir Rev* 2003;4:237-42.
- Shamberger RC, Hendren III WH. Congenital deformities of the chest wall and sternum. In: Pearson FG, Cooper JD, editors. *Thoracic Surgery*. Philadelphia: Churchill Livingstone; 2002. p. 1351-73.
- Shamberger RC, Chest wall deformities. In: Shields TW, LoCicero III J, editors. *General Thoracic Surgery*. Philadelphia: Lippincott Williams Wilkins; 2005. p. 653-81.
- Kuenzler KA, Stolar CJ. Surgical correction of pectus excavatum. *Paediatr Respir Rev* 2009;10:7-11.
- Genc O, Gurkok S, Gözübüyük A, Dakak M, Caylak H, Yücel O. Repair of pectus deformities: experience and outcome in 317 cases. *Ann Saudi Med* 2006;26:370-4.
- Chen AC, Lee MS, Lin SS, Pan LC, Ueng SW. Augmentation of osteochondral repair with hyperbaric oxygenation: a rabbit study. *J Orthop Surg Res* 2010;5:91.
- Sirin Y, Olgac V, Dogru-Abbasoglu S, Tapul L, Aktas S, Soley S. The influence of hyperbaric oxygen treatment on the healing of experimental defects filled with different bone graft substitutes. *Int J Med Sci* 2011;8:114-25.
- Gungor A, Poyrazoglu E, Cincik H, Sali M, Candan H, Ay H. The effectiveness of hyperbaric oxygen treatment in tracheal reconstruction with auricular cartilage grafts (experimental study). *Am J Otolaryngol* 2003;24:390-4.
- Gorur R, Hahoglu A, Uzun G, Kutlu A, Turut H, Yiyit N, et al. Effects of hyperbaric oxygen therapy on wound healing after tracheal resection and end-to-end anastomoses in rats: results of early observations. *Thorac Cardiovasc Surg* 2008;56:359-62.
- Celik B, Meydan AD, Kefeli M, Gülen EK, Okumus NO. The effects of hyperbaric oxygen treatment on the healing of tracheal anastomosis following irradiation in rats. *Thorac Cardiovasc Surg* 2010;58:481-5.
- Wang C, Schwaitzberg S, Berliner E, Zarin DA, Lau J. Hyperbaric oxygen for treating wounds: a systematic review of the literature. *Arch Surg* 2003;138:272-9.
- Mills C, Bryson P. The role of hyperbaric oxygen therapy in the treatment of sternal wound infection. *Eur J Cardiothorac Surg* 2006;30:153-9.
- Huo MH, Troiano NW, Pelker RR, Gundberg CM, Friedlaender GE. The influence of ibuprofen on fracture repair: biomechanical, biochemical, histologic, and histomorphometric parameters in rats. *J Orthop Res* 1991;9:383-90.
- Robicsek F, Watts LT. Surgical correction of pectus excavatum. How did we get here? Where are we going? *Thorac Cardiovasc Surg* 2011;59:5-14.
- Meyer WL. Zur chirurgischen Behandlung der angeborenen Trichterbrust. *Berl Klin Wschr* 1911;84:1563-6.
- Sauerbruch F. Operative beseitigung der angeborenen Trichter-brust. *Deutsch Zeitschr Chirurgie* 1931;234:760-4.
- Ravitch MM. Operative technique of pectus excavatum repair. *Ann Surg* 1949;129:429-44.
- Nuss D, Kelly RE Jr, Croitoru DP, Katz ME. A 10-year review of a minimally invasive technique for the correction of pectus excavatum. *J Pediatr Surg* 1998;33:545-52.
- Malek MH, Berger DE, Marelich WD, Coburn JW, Beck TW, Housh TJ. Pulmonary function following surgical repair of pectus excavatum: a meta-analysis. *Eur J Cardiothorac Surg* 2006;30:637-43.
- Malek MH, Berger DE, Housh TJ, Marelich WD, Coburn JW, Beck TW. Cardiovascular function following surgical repair of pectus excavatum: a metaanalysis. *Chest* 2006;130:506-16.
- Martinez D, Juame J, Stein T, Pena A. The effect of costal cartilage resection on chest wall development. *Ped Surg Int* 1990;5:170-3.

22. Cherng JH, Chang SC, Chen SG, Hsu ML, Hong PD, Teng SC, et al. The effect of hyperbaric oxygen and air on cartilage tissue engineering. *Ann Plast Surg* 2012;69:650-5.
23. Roughley PJ, Lee ER. Cartilage proteoglycans: structure and potential functions. *Microsc Res Tech* 1994;28:385-97.
24. Panasyuk A, Frati E, Ribault D, Mitrovic D. Effect of reactive oxygen species on the biosynthesis and structure of newly synthesized proteoglycans. *Free Radic Biol Med* 1994;16:157-67.
25. Ueng SW, Yuan LJ, Lin SS, Niu CC, Chan YS, Wang IC, et al. Hyperbaric oxygen treatment prevents nitric oxide-induced apoptosis in articular cartilage injury via enhancement of the expression of heat shock protein 70. *J Orthop Res* 2013;31:376-84.
26. Carlevaro MF, Cermelli S, Cancedda R, Descalzi Cancedda F. Vascular endothelial growth factor (VEGF) in cartilage neovascularization and chondrocyte differentiation: auto-paracrine role during endochondral bone formation. *J Cell Sci* 2000;113:59-69.
27. Weber TR, Kurkchubasche AG. Operative management of asphyxiating thoracic dystrophy after pectus repair. *J Pediatr Surg* 1998;33:262-5.
28. Tokat AO, Tastan E, Karasu S, Yucel O, Gamsızkan M, Arslan S, et al. An enhanced method of rapid cartilage healing after costal cartilage resection. *Turk Gogus Kalp Dama* 2012;20:323-8.
29. Calik M, Aribas OK, Kanat F. The effect of costal cartilage resection on the chest wall development: a morphometric evaluation. *Eur J Cardiothorac Surg* 2007;32:756-60.
30. Yuan LJ, Ueng SW, Lin SS, Yeh WL, Yang CY, Lin PY. Attenuation of apoptosis and enhancement of proteoglycan synthesis in rabbit cartilage defects by hyperbaric oxygen treatment are related to the suppression of nitric oxide production. *J Orthop Res* 2004;22:1126-34.