

Valve-sparing aortic root replacement in a patient with anomalous origin of circumflex artery: a case report

*Sirkumfleks arter kaynaklı anomalisi olan bir hastada kapak koruyucu aort kökü replasmanı:
Olgu sunumu*

Mehmet Çakıcı,¹ Evren Özçınar,¹ Ali Bulut,² Uğursay Kızıltepe²

Institution where the research was done:

Dışkapı Yıldırım Beyazıt Training and Research Hospital, Ankara, Turkey

Author Affiliations:

¹Department of Cardiovascular Surgery, Medical Faculty of Ankara University, Ankara, Turkey

²Department of Cardiovascular Surgery, Dışkapı Yıldırım Beyazıt Training and Research Hospital, Ankara, Turkey

ABSTRACT

Today, valve-sparing aortic root replacement techniques have started to become safe alternatives which are being used more commonly. In this article, we present a successful valve-sparing aortic root replacement experience in a 19-year-old male patient of sinus valsalva aneurysm associated with anomalous circumflex artery arising from right coronary sinus.

Keywords: Anomalous coronary artery; aortic valve-sparing; reimplantation.

Valve-sparing aortic root replacement (V-SARR) has emerged as an alternative technique to composite graft replacement for patients whose dilation of the aortic root or ascending aorta meets the indications for surgical repair and whose aortic valve anatomy is suitable for valve preservation.^[1] Good operative results have been reported in patients who have undergone elective V-SARR for degenerative aortic root aneurysms, and reimplanting the aortic valve appears to provide more stable and durable aortic valve function.^[1,2]

Coronary artery anomalies are rare, occurring in just 1.3% of the population. Most individuals are diagnosed incidentally, but in approximately 20% of patients, these anomalies may result in myocardial infarction, arrhythmia, and sudden death.^[3] Anomalous coronary arteries are usually sporadic but may also be

ÖZ

Günümüzde, kapak koruyucu aort kökü replasman teknikleri giderek yaygın olarak uygulanan güvenli seçenekler olmaya başlamıştır. Bu yazıda, sinüs valsalva anevrizması ile birlikte sağ koroner sinüsten köken alan sirkumfleks arter anomalili 19 yaşında bir erkek hastadaki başarılı kapak koruyucu aort kökü replasmanı deneyimi sunuldu.

Anahtar sözcükler: Koroner arter anomalisi; aort kapak koruyucu; reimplantasyon.

associated with congenital heart diseases and bicuspid aortic valves.

Herein, we present the case of a sinus of Valsalva aneurysm associated with an anomalous origin of the circumflex coronary artery in a patient with Peter's syndrome that was successfully treated with the modified Tirone David-V procedure.

CASE REPORT

A 19-year-old man was admitted to our clinic with progressive chest pain and exertional dyspnea. A physical examination revealed pectus carinatum, eye findings and hearing loss due to Peter's syndrome, and an early diastolic murmur and hypertension (HT) were also present. In addition, computed tomography (CT) showed a sinus of Valsalva



Available online at
www.tgkdc.dergisi.org
doi: 10.5606/tgkdc.dergisi.2015.10393
QR (Quick Response) Code

Received: May 24, 2014 Accepted: June 06, 2014

Correspondence: Mehmet Çakıcı, M.D. Dışkapı Yıldırım Beyazıt Eğitim ve Araştırma Hastanesi, Kalp ve Damar Cerrahisi Kliniği, 06330 Dışkapı, Ankara, Turkey.

Tel: +90 505 - 265 34 71 e-mail: mcakici21@gmail.com

aneurysm (5.8 cm) originating from the right coronary sinus. Transthoracic (TTE) and transesophageal echocardiography (TEE) revealed a turbulent flow in the aneurysm with severe regurgitation of the tricuspid aortic valve. However, no coronary angiogram was performed preoperatively because of the risk of rupture and the patient's young age.

The operative procedure was performed through a median sternotomy using moderate hypothermic cardiopulmonary bypass (CPB). Following the aortotomy incision, the circumflex coronary artery (Cx) presented with an anomalous origin from the right coronary sinus that had a retroaortic and subannular path. The right coronary artery (RCA) and the Cx were then dissected as a whole button, and a 1 mm probe was placed within the Cx, which detected the subannular retroaortic course of the RCA (Figure 1). Next, we assessed whether the annular suture line was secure via the probe, and after examining the aortic valve, including the thickness and coaptation of each leaflet, V-SARR was accomplished using two individual 30 mm and 28 mm conduit grafts (Figure 1). First, the 30 mm Dacron conduit was implanted in the subannular position using pledgetted polypropylene sutures, and all three commissures were re-suspended inside the tube graft after determining the correct height and alignment. Then the aortic annulus and remnant sinuses are re-suspended within the tube graft with continuous 4/0 polypropylene sutures. After this, the 28 mm Dacron conduit was attached to the first conduit with continuous 4/0 polypropylene sutures

after the edges were fashioned, and this was followed by the reimplantation of the coronary artery buttons to create neosinuses. The osteal opening was also examined. Thus, the aortic root implantation and reconstruction of the neosinuses was performed via the use of two Dacron conduits of different sizes. Anastomoses was completed via a de-airing procedure, and the cross-clamp was then removed. Weaning from CPB was uneventful, and intraoperative TEE revealed mild aortic valve regurgitation. The patient was extubated on postoperative day one and was subsequently discharged on postoperative day seven. The follow-up TTE and CT at the first month showed a successful repair of the sinus of Valsalva aneurysm and an intact coronary artery flow (Figure 2).

DISCUSSION

Patients with aortic root aneurysms often have normal or minimally stretched aortic cusps when they are referred for surgery.^[4] Nevertheless, as the aortic sinuses dilate, the sinotubular junction and aortic annulus may also dilate and cause aortic insufficiency (AI).

Although a separate annuloplasty can be performed during the remodeling procedure, it is already incorporated into the reimplantation technique. Kvitting et al.^[1] reported in their series that the patients with the longest follow-up had undergone reimplantation of the aortic valve, and at the five-year follow up, over 95% had not undergone an aortic valve reoperation.

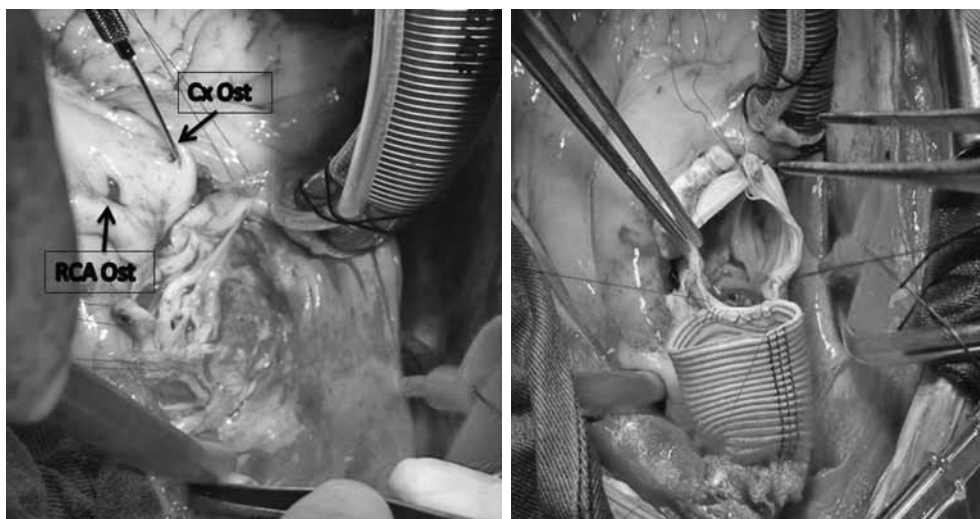


Figure 1. Surgical view of the aortic valve and the anomalous origin of the circumflex coronary artery from the right coronary sinus that had a retroaortic and subannular path (seen via a vascular probe). A valve-sparing aortic root replacement using the modified Tirone David-V procedure was performed with a 30 mm graft proximally and a 28 mm graft distally.

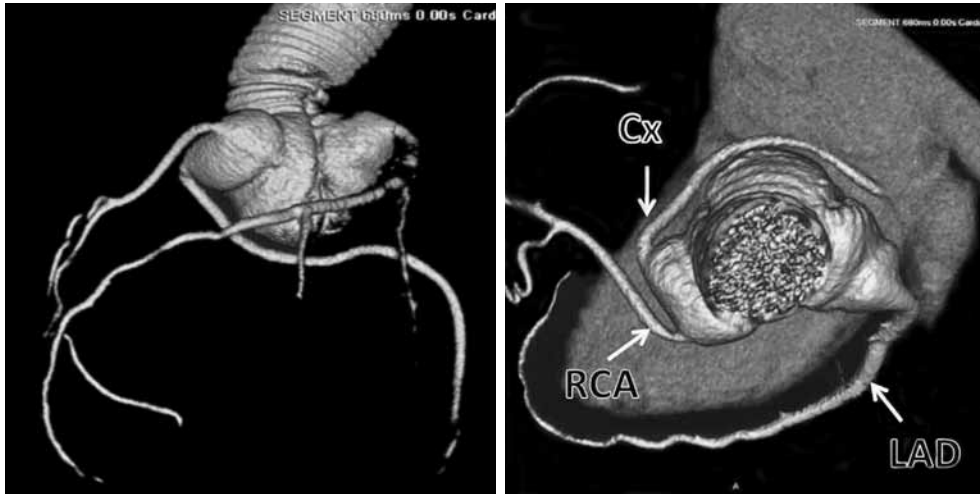


Figure 2. Postoperative one-month three-dimensional computed tomography of the patient showing the intact coronary flow and preserved aortic annulus. The right coronary artery button is visible in the right graft pseudosinus. Cx: Circumflex artery; RCA: Right coronary artery; LAD: Left anterior descending artery.

Our preferred method is the reimplantation of the aortic root because recent studies have reported that this procedure is ideal for young patients whose primary problem is an aortic root aneurysm.^[2] The benefit of the reimplantation technique versus the remodeling technique is that the aortic annulus is more stabilized; therefore, the probability for late aortic insufficiency is lower. Theoretically, the creation of pseudosinuses produces more natural leaflet motion, minimizes systolic contact between the valve cusps and the Dacron graft, and reduces diastolic closing cusp stress, all of which may enhance long-term valve durability and maintain relatively normal coronary flow patterns.

Coronary anomalies can be classified as anomalies of origin and course, anomalies of the intrinsic coronary arterial anatomy, or anomalies of termination. The retroaortic course is the most common and is seen in up to 0.9% of the population, particularly in cases in which the left Cx arises from either the right sinus of Valsalva or the RCA.^[3] While the retroaortic or prepulmonic course is considered to be “benign” or “nonmalignant”, Samarendra et al.^[5] suggested that when the Cx arises from the contralateral sinus with a retroaortic course, it may result in a predisposition toward selective coronary atherosclerosis.

It is important to recognize the retroaortic course of the anomalous coronary artery in patients with aortic valve disease since this artery may be inadvertently compressed during aortic valve or aortic root surgery. As previously mentioned, our patient did not undergo coronary imaging, so the rare coronary anomaly was

detected intraoperatively. A coronary probe was used to determine the appropriate and safe annular suture verge to avoid a possible coronary injury. Hence, despite the close proximity of the abnormal coronary to the aortic annulus at the non-coronary and left coronary scallops, a modified David-V procedure was performed successfully with minimal aortic regurgitation.

Valve-sparing aortic root replacement is a safe and effective surgical option for the management of aortic root aneurysms in young patients, and the challenging coronary anatomy should not preclude performing this procedure. We also recommend that routine conventional coronary angiography or multislice computed tomographic coronary angiography be performed preoperatively to delineate the coronary anatomy.

Declaration of conflicting interests

The authors declared no conflicts of interest with respect to the authorship and/or publication of this article.

Funding

The authors received no financial support for the research and/or authorship of this article.

REFERENCES

1. Kvitting JP, Kari FA, Fischbein MP, Liang DH, Beraud AS, Stephens EH, et al. David valve-sparing aortic root replacement: equivalent mid-term outcome for different valve types with or without connective tissue disorder.

- J Thorac Cardiovasc Surg 2013;145:117-26.
2. David TE. How I do aortic valve sparing operations to treat aortic root aneurysm. J Card Surg 2011;26:92-9.
 3. Patel S. Normal and anomalous anatomy of the coronary arteries. Semin Roentgenol 2008;43:100-12.
 4. Valo J, Jokinen JJ, Kaarne M, Ihlberg L. Expanding indications for valve-sparing aortic root reconstruction: early and midterm results. Ann Thorac Surg 2013;95:579-85.
 5. Samarendra P, Kumari S, Hafeez M, Vasavada BC, Sacchi TJ. Anomalous circumflex coronary artery: benign or predisposed to selective atherosclerosis. Angiology 2001;52:521-6.