

Is it safe to work in a fast-food kitchen? a case of recurrent spontaneous pneumothorax with cholesterol granuloma

*Hazır gıda mutfağında çalışmak güvenli mi?
kolesterol granülomlu bir nüks spontan pnömotoraks olgusu*

Timuçin Alar,¹ Aslı Muratlı,² Ahmet Uludağ,³ İsmail Ertuğrul Gedik¹

Departments of ¹Thoracic Surgery, ²Pathology and ³Medical Genetics,
Medical Faculty of Çanakkale Onsekiz Mart University, Çanakkale, Turkey

ABSTRACT

Cholesterol granulomas are defined as cystic lesions containing cholesterol crystals surrounded by foreign body giant cells, fibrous tissue reaction and chronic inflammation. A 31-year-old male patient presented at the thoracic surgery outpatient clinic with a left apical recurrent pneumothorax. Bullectomy with multiple wedge resections was performed through a mini-thoracotomy. Histopathological examination of the resection material showed emphysematous lung and bullae + cholesterol granuloma. The patient had been working in a fast-food kitchen and at the french fries section, in particular, for nearly the past four years and had been exposed through inhalation to exogenous oil and oil products derived from vaporized vegetable and animal oil. We believe that staff working at a fast food kitchen and at the french fries section, in particular, should work using protective measures such as a mask and good ventilation.

Keywords: Cholesterol granuloma; lung; pneumothorax; surgery.

Cholesterol granulomas are defined as cystic lesions that contain cholesterol crystals surrounded by foreign body giant cells, fibrous tissue reaction, and chronic inflammation.^[1] However, pulmonary cholesterol granulomas (PCGs) are rare conditions that can be seen in some patients with endogenous lipoid pneumonia, alveolar proteinosis, lysinuric protein intolerance, and severe pulmonary hypertension (PH),^[2] but there are no cases involving spontaneous pneumothorax. Herein, we present a patient diagnosed with PCG following a wedge resection for left recurrent pneumothorax, an extremely rare clinical condition.

ÖZ

Kolesterol granülomları, kolesterol kristalleri içeren, çevresi yabancı cisim dev hücreleri, fibröz doku reaksiyonu ve kronik enflamasyon ile çevrili kistik lezyonlar olarak tanımlanmaktadır. Otuz bir yaşında erkek hasta sol apikal nüks pnömotoraks yakınması ile göğüs cerrahisi polikliniğine başvurdu. Minitorakotomi ile çoklu kama rezeksiyon ve büllektomi yapıldı. Alınan materyalin histopatolojik incelemesinde amfizematöz akciğer ve bül + kolesterol granülomu tespit edildi. Hasta hazır gıda mutfağında, özellikle de patates kızartma bölümünde yaklaşık dört yıl süreyle çalışmış ve buharlaşan bitkisel ve hayvansal kaynaklı eksojen yağ ve yağ ürünlerine solunma yolu ile maruz kalmıştı. Hazır gıda mutfağında, özellikle patates kızartma bölümünde görev yapan personelin, maske kullanımı ve iyi bir havalandırma sistemi gibi koruyucu önlemler alınarak çalıştırılmaları gerektiği kanaatindeyiz.

Anahtar sözcükler: Kolesterol granülomu; akciğer; pnömotoraks; cerrahi.

CASE REPORT

A 31-year-old male patient presented at our thoracic surgery outpatient clinic with a 10-day history of left chest pain. The pain had started suddenly and grew more intense with deep breathing. The patient had no history of smoking or alcohol use, and a physical examination revealed a lack of respiratory sounds in the upper zone of the left lung. A posterior-anterior chest X-ray showed left apical pneumothorax, and the patient was subsequently admitted to the thoracic surgery department where he was taken to the operating



Available online at
www.tgkdc.dergisi.org
doi: 10.5606/tgkdc.dergisi.2015.9111
QR (Quick Response) Code

Received: July 27, 2013 Accepted: September 27, 2013

Correspondence: Timuçin Alar, M.D. Çanakkale Onsekiz Mart Üniversitesi Tıp Fakültesi, Göğüs Cerrahisi Anabilim Dalı, 17020 Çanakkale, Turkey.

Tel: +90 286 - 218 00 18 e-mail: timalar@comu.edu.tr

room following the necessary preparations. A catheter thoracostomy (Tru-Close® Thoracic vent, UreSil, LLC, Skokie, IL, USA) was then performed at the junction of the left second intercostal space and the midclavicular line under local anesthesia. Afterwards, the respiratory sounds were equal bilaterally, and a follow-up X-ray yielded normal results. The catheter was withdrawn 48 hours after air drainage was discontinued, and the patient made arrangements for a follow-up appointment at which time he would undergo thoracic computed tomography (CT) to evaluate bilateral lung parenchyma.

The thoracic CT was performed approximately one week after the patient was discharged, and it showed left spontaneous recurrent pneumothorax and bilateral bullous pulmonary areas. Furthermore, the patient underwent another physical examination because he was suffering from shortness of breath, and this revealed decreased respiratory sounds on the left side. After preparing the patient, a bullectomy with multiple wedge resections was then performed via a mini-thoracotomy because of the widespread bullous areas in the thoracic CT, with the left serratus anterior muscle being protected at all times. A histopathological evaluation of the resected material showed emphysematous lung and bullae + cholesterol granuloma (Figure 1). Tests for hyperlipidemia were then performed which showed the following results: total cholesterol 157 mg/dL (range: 0-200), triglycerides 79 mg/dL (range: 0-200), very-low-density lipoprotein (VLDL) cholesterol 16 mg/dL (range: 5-40), high-density lipoprotein (HDL) cholesterol 49 mg/dL (range: 35-60), and low-density lipoprotein (LDL) cholesterol 115 mg/dL (range: 160-190). The blood lipid values were normal, so real-time polymerase chain reaction (RT-PCR) and

apolipoprotein E (ApoE) E2/E3/E4 analyses were performed by the medical genetics department to investigate the presence of hyperlipidemia with a genetic basis. In addition, peripheral blood samples with ethylenediaminetetraacetate (EDTA) were used for genomic DNA isolation, and all genomic DNA was recovered from the peripheral blood samples using the MagNA Pure Compact System (Roche Diagnostics Corporation, Indianapolis, IN, USA). Furthermore, the ApoE gene was amplified via the RT-PCR using the LightCycler 2.0 software (Roche Diagnostics Corporation, Indianapolis, IN, USA), and the mutant or normal genes were then detected using the same software. This analysis revealed the E3/E3 normal genotype.

The patient had been working at the french fries station at a fast food restaurant for approximately four years. We hypothesized that the patient's long-term exposure to vaporized oil and other oil products was a risk factor and suggested a change in his work duties. He was then transferred to the pizza section where he continues to work. He experienced no recurrence during the thrice-monthly follow-ups for approximately the next two years. Moreover, chest CT also showed no progression of the bilateral bullous pulmonary fields during that time.

DISCUSSION

Cholesterol granuloma is a histological term defined by tissue reaction against foreign bodies like cholesterol crystals, and it is most commonly seen at the petrous apex of the temporal bone. The origin of cholesterol crystals is controversial, but it is accepted that they originate from the cleaning of the tympanic cavity with air exchange, the air cell complexes in the temporal

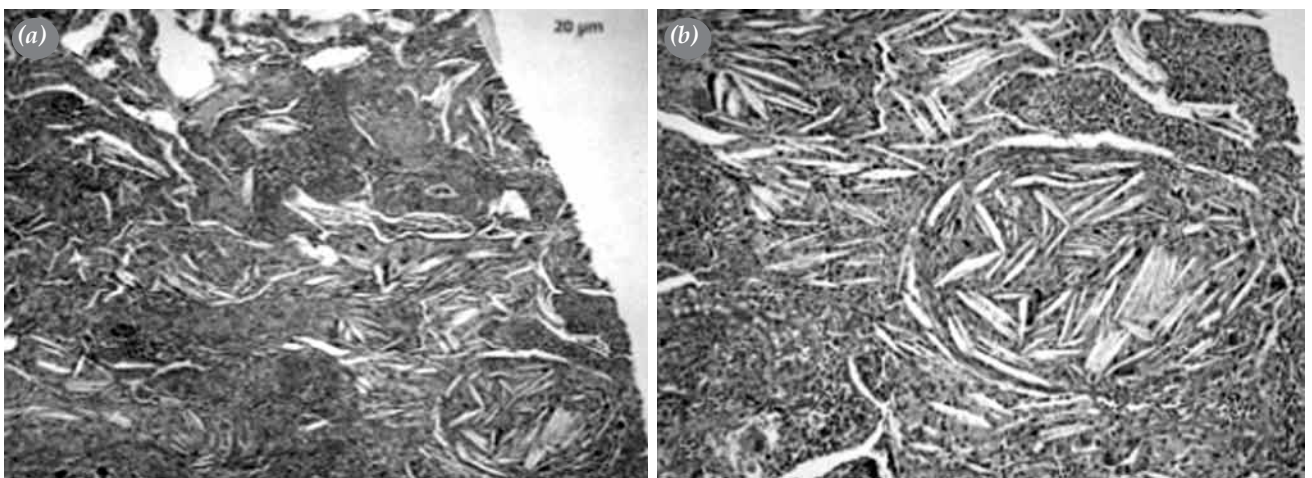


Figure 1. (a) Microscopic view of the granulomatous structures in the pulmonary parenchyma consisted of cholesterol grooves, giant cells, and inflammation that had a local follicular pattern (H-E x 5). (b) A close-up view of the cholesterol granulomas in Figure 1a (H-E x 10).

bone, and blood extravasation. Hemoglobin is degraded following blood extravasation, causing the appearance of the cholesterol crystals. They are very irritating and stimulate giant cells, which are responsible for the irreversible tissue reaction.^[1,3] Cholesterol granulomas can be seen in various organs, such as the breast, thymus, and kidneys, and the source of the granuloma formation was identified as bleeding into the tissues by Ezzat and Alowami.^[4] In our case, however, there was no evidence of previous intrapulmonary bleeding.

Pulmonary cholesterol granulomas are rare lesions with no definitive cause, but they do have characteristic morphological features. There are only a few studies in the literature that have focused on PCGs. Several articles have reported that they are associated with PH, but cases with this condition are extremely scarce. Long-term severe PH or other factors are believed to contribute to PCG development. Nolan et al.^[2] found PCGs in 25% of their PH patients. However, this is quite a rare occurrence because the prognosis of PH is so unfavorable that such a severe clinical picture cannot continue for a long period of time. Therefore, it is probable that granuloma formation is facilitated by other factors. One possible pathogenetic factor is the membrane lipids that appear following erythrocyte lysis. Microangiopathic hemolytic anemia and thrombocytopenia can be seen with primary PH, and the consumption of these cells is thought to center around the lysis that occurs while passing through plexiform lesions.^[5] In addition, hemolytic anemia and thrombocytopenia may also contribute to cholesterol granuloma formation, but no definitive pathogenesis has been identified as of yet. The lack of a history of PH, microangiopathic hemolytic anemia, thrombocytopenia, and trauma in our patient indicated the presence of a different pathogenetic factor in the development of the cholesterol granuloma.

The ApoE gene encodes a protein that combines with lipids to be transformed into a lipoprotein. Furthermore, ApoE is a VLDL that enables the transfer of cholesterol in the blood. Hence, ApoE gene variations also affect cholesterol metabolism, and these variations can cause an increased incidence of coronary artery disease (CAD), stroke, and Alzheimer's disease (AD) as well as various other disorders.^[6,7] The three most common ApoE variations are Apo E2, Apo E3, and Apo E4, and these variations also have subtypes. The most common ApoE genotype is the standard Apo E3 genotype,^[6,7] and the presence of the Apo E3/E3 genotype in our patient decreased the possibility of a diagnosis of familial hyperlipidemia and cholesterol granuloma due to an ApoE polymorphism.

Positron emission tomography-computed tomography (PET-CT) is used for the diagnosis and staging of malignant disease and can show increased activity in some benign inflammatory conditions.^[8] However, we found only one report in the literature that detected increased fluorodeoxyglucose (FDG) activity on PET-CT in a PCG case. However, there are very few PCG cases in the literature; therefore, no gold standard test has been established for its diagnosis or a differential diagnosis. The diagnostic chest X-ray and thoracic CT of our patient only showed pneumothorax and bullous pulmonary areas, and no PET-CT was performed.

Inhalation of mineral oils does not stimulate the cough reflex in the tracheobronchial system, but it disturbs the mucociliary transport system. These oils cannot be eliminated, so they accumulate in the alveoli, causing cholesterol pneumonia over time.^[9,10] After eliminating all other reasons for the cholesterol granuloma in our case, we determined that the clinical picture involved an occupational disease.

Our findings showed that an increased cholesterol crystal content in the tissues caused by various mechanisms can lead to the development of cholesterol granulomas in other regions. Our patient had been working at the french fry station in a fast food restaurant, for approximately four years and had been exposed via inhalation to exogenous oil and oil products derived from vaporized vegetable and animal oil. We believe that the irritation that developed after the transfer of these oil products to the lungs resulted in the patient's chronic inflammation and PCG. However, a search of the literature revealed no information regarding the development of bullous lung or pneumothorax following mineral oil inhalation. Thus, as a precautionary measure, we advise that the staff working in a fast food restaurant kitchen, especially those cooking french fries, should wear protective masks and that good ventilation should be provided until this topic can be studied further.

Declaration of conflicting interests

The authors declared no conflicts of interest with respect to the authorship and/or publication of this article.

Funding

The authors received no financial support for the research and/or authorship of this article.

REFERENCES

1. Hoa M, House JW, Linthicum FH Jr. Petrous apex cholesterol granuloma: maintenance of drainage pathway, the

- histopathology of surgical management and histopathologic evidence for the exposed marrow theory. *Otol Neurotol* 2012;33:1059-65.
2. Nolan RL, McAdams HP, Sporn TA, Roggli VL, Tapson VF, Goodman PC. Pulmonary cholesterol granulomas in patients with pulmonary artery hypertension: chest radiographic and CT findings. *AJR Am J Roentgenol* 1999;172:1317-9.
 3. Jackler RK, Cho M. A new theory to explain the genesis of petrous apex cholesterol granuloma. *Otol Neurotol* 2003;24:96-106.
 4. Ezzat TF, Alowami S. Cholesterol granuloma of the anterior mediastinum with osseous metaplasia. *Rare Tumors* 2012;4:e47.
 5. Jubelirer SJ. Primary pulmonary hypertension. Its association with microangiopathic hemolytic anemia and thrombocytopenia. *Arch Intern Med* 1991;151:1221-3.
 6. Zlokovic BV. Cerebrovascular effects of apolipoprotein E: implications for Alzheimer disease. *JAMA Neurol* 2013;70:440-4.
 7. Tanguturi P, Pullareddy B, Kumar PS, Murthy DK. Association between apolipoprotein E gene polymorphism and myocardial infarction. *Biochem Genet* 2013;51:398-405.
 8. Wada H, Sakashita T, Shigemori W, Nagao T, Nakano Y. A case of pulmonary cholesterol granuloma: an (18) F-fluorodeoxyglucose positron emission tomography image. *Am J Med Sci* 2012;344:414-5.
 9. Banjar H. Lipoid pneumonia: a review. *Bahrain Med Bull* 2003;25:36-9.
 10. Khilnani GC, Hadda VI. Lipoid pneumonia: an uncommon entity. *Indian J Med Sci* 2009;63:474-80.