

Unusual location of hydatid cyst: thoracic outlet

Kist hidatiğin sıradışı yerleşim yeri: Torasik outlet

Bayram Altuntaş,¹ Sami Ceran,² Ebru Şener³

Institution where the research was done:

Erzurum Regional Education and Research Hospital, Erzurum, Turkey

Author Affiliations:

Departments of ¹Thoracic Surgery, ²Pathology, Erzurum Regional Education and Research Hospital, Erzurum, Turkey

²Department of Thoracic Surgery, Necmettin Erbakan University, Meram Medical Faculty, Konya, Turkey

ABSTRACT

Hydatid cyst is an infectious disease caused by cestodes. The organs most frequently involved are the liver and lung (70% and 25%, respectively). The other organs are affected by less than 10%. The spleen, kidneys, bile ducts, mesentery, heart, brain, vertebral column, ovaries, pancreas, gallbladder, thyroid gland, breast and musculoskeletal system or soft tissue are less frequently involved. In this article, we report a 49-year-old female patient with a histopathologically proven hydatid cyst which was located in the right thoracic outlet region. To our knowledge, a primary hydatid cyst of the thoracic outlet without invasion to the adjacent structures has not been previously reported.

Keywords: Hydatid cyst; thoracic outlet; tomography.

Hydatid cyst is an infectious disease caused by a cestode. The organs most frequently involved by Echinococcus infestations are the liver and lungs at rates of 70 and 25%, respectively.^[1] The other organs of the body have rates of less than 10%, with the spleen, kidneys, bile ducts, mesentery, heart, brain, vertebral column, ovaries, pancreas, gallbladder, thyroid gland, breast, and musculoskeletal or soft tissue being less frequently involved.^[2,3] Musculoskeletal involvement is seen even less often and has been reported in only 1-4% of the patients with this disease.^[3] Muscular hydatidosis at several locations (i.e., the supraspinatus, sartorius, thoracic wall, gluteus, and biceps brachii

ÖZ

Kist hidatik, sestodların neden olduğu infeksiyöz bir hastalıktır. En sık tutulan organlar karaciğer ve akciğerdir (sırasıyla %70 ve %25). Diğer organlar %10'dan daha az etkilenir. Dalak, böbrekler, safra yolları, mezenter, kalp, beyin, vertebral kolon, yumurtalıklar, pankreas, safra kesesi, troid bezi, meme ve kas-iskelet sistemi veya yumuşak doku daha az tutulur. Bu yazıda, histopatolojik olarak ispatlanan, sağ torasik outlet bölgesinde kist hidatiği olan 49 yaşında bir kadın hasta sunuldu. Bilgilerimize göre, torasik outlette çevre dokulara yayılmayan bir kist hidatik daha önce sunulmamıştır.

Anahtar sözcükler: Hidatik kist; torasik outlet; tomografi.

muscles) has also been reported.^[3] Although a hydatid cyst may be seen in any part of the body, to the best of our knowledge, no cases involving a primary thoracic outlet cyst without invasion to the adjacent structures have been previously reported. Hence, we present our case in which this rare event occurred.

CASE REPORT

A 49-year-old woman who complained of right upper extremity pain was admitted to our facility. During the physical examination, swelling was detected in the right infraclavicular region, and the patient was then referred to the department of thoracic



Available online at
www.tgkdc.dergisi.org
doi: 10.5606/tgkdc.dergisi.2015.7221
QR (Quick Response) Code

Received: May 31, 2012 Accepted: March 02, 2013

Correspondence: Bayram Altuntaş, M.D. Erzurum Bölge Eğitim ve Araştırma Hastanesi Göğüs Cerrahisi Kliniği, 25240 Yakutiye, Erzurum, Turkey.

Tel: +90 442 - 232 54 03 e-mail: draltuntas@hotmail.com

surgery for surgical consultation. Another physical examination showed that the patient's chest was clear on auscultation, but mild swelling was noted at the surface of the right infraclavicular region. The blood and pulmonary function tests along with the electrocardiogram results were all normal. However, thoracic computed tomography (CT) revealed a mass measuring 74x73x55 mm in diameter in the right thoracic outlet that was not enhanced after the injection of a contrast medium. There was no invasion to the adjacent structures, and the subclavian artery was in the inferior position (Figure 1). In addition, Doppler ultrasonography (USG) revealed that the flow of the subclavian vein diminished, but the electromyographic findings of the right upper extremity were normal. A right infraclavicular incision was made. The cyst was located superior to the brachial plexus and the subclavian artery was in the inferior position, and it was totally removed. A pathological examination of the lesion confirmed the diagnosis of hydatid cyst, and in the immunohistochemical staining of the cyst membrane, the periodic asid-Schiff staining was positive (Figure 2). The patient's postoperative recovery was uneventful, and at the postoperative 20th month, no problems or complications have been reported.

DISCUSSION

Hydatid cysts in an unusual location are a diagnostic enigma; thus the diagnosis in most patients usually takes place during or after surgery. There are many reports regarding unusual locations of hydatid cysts, but we believe this is the first reported case in the literature of one located in the thoracic outlet.

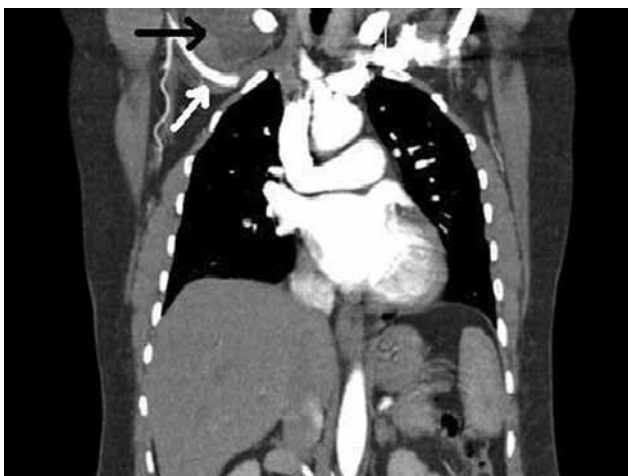


Figure 1. Computed tomography shows a mass measuring 74x73x55 mm in diameter in the right thoracic outlet (black arrow). The subclavian artery was in the inferior position (white arrow).

In our patient, the primary hydatid cyst in the thoracic outlet may have occurred when parasite eggs passed through the duodenal wall and the small intestine of the main host and into the portal venous system or lymphatic system. They ultimately would have reached the liver and lungs, ending in the development of hydatid cyst.^[1] Furthermore, the parasite eggs may have also passed through the hepatic sinusoid and pulmonary capillary barriers. Then they would have participated in the systemic circulation and been located in any part of the body, including the thoracic outlet.^[1]

The symptoms of this disease are related to the part of the body that is involved. Dispnea, cough, chest and abdominal pain, jaundice, headaches, and dizziness can be seen, and in our patient, there was a complaint of right upper extremity pain. We believe that this symptom was related to thoracic outlet syndrome (TOS) because the cyst was located superior to the brachial plexus and the subclavian artery.

Diagnosis of this disease can be established based on the history of exposure in an endemic area along with the radiological findings.^[4] Plain radiography, CT, and magnetic resonance imaging (MRI) can detect and localize the cysts. Ruptured and infected hydatid cysts are often confused with malignancy, tuberculosis (TB), abscesses, or empyema.^[5] Furthermore, early diagnosis is crucial to prevent complications, and complement fixation, specific immunoglobulin G, indirect fluorescent, and enzyme-linked immunosorbent assay (ELISA) tests can be used to support the diagnosis.^[4] Serological tests are only

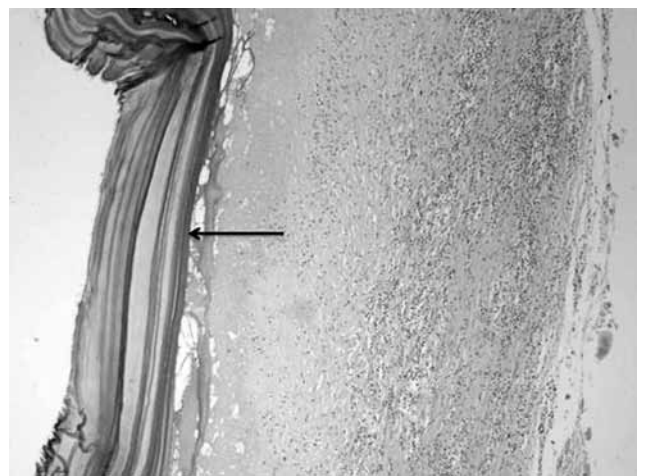


Figure 2. In the immunohistochemical staining of the cyst membrane (arrow), the periodic asid-Schiff test was positive (PAS x 200).

significant when the results are positive, but negative results do not necessarily rule out hydatid disease.^[4] As previously mentioned, some cases with hydatid cysts are diagnosed intra- and postoperatively,^[6,7] but in our case, it was detected preoperatively with CT and Doppler USG. Although the electromyographic results of the right upper extremity were normal, the Doppler USG and CT findings of our patient combined with her symptoms supported the diagnosis of TOS. The histopathological diagnosis of hydatid cyst was confirmed after resection.

Surgical intervention is the primary choice of treatment for hydatid disease with a goal of removing the cyst contents without contaminating the patient. This is followed by the suitable closure of any remaining cavity.^[1] In our case, there was no conspicuous invasion to the adjacent structures such as the ribs, muscles, brachial plexus, or subclavian artery and vein. Therefore, we removed the mass completely, and then closed the layers in a usual manner. In addition, no contamination occurred during the operation.

Declaration of conflicting interests

The authors declared no conflicts of interest with respect to the authorship and/or publication of this article.

Funding

The authors received no financial support for the research and/or authorship of this article.

REFERENCES

1. Iynen I, Sogut O, Guldur ME, Kose R, Kaya H, Bozkus F. Primary hydatid cyst: an unusual cause of a mass in the supraclavicular region of the neck. *J Clin Med Res* 2011;3:52-4.
2. Atalay F, Orug T, Arda K, Tosun O, Atalay F. An unusual case of hydatid disease located in the erector spinae muscle. *JBR-BTR* 2003;86:329-31.
3. Kouskos E, Chatziantoniou J, Chrissafis I, Anitsakis C, Zamtrakis S. Uncommon locations of hydatid cysts. *Singapore Med J* 2007;48:e119-21.
4. Ozpolat B, Ozeren M, Soyal T, Yucel E. Unusually located intrathoracic extrapulmonary mediastinal hydatid cyst manifesting as Pancoast syndrome. *J Thorac Cardiovasc Surg* 2005;129:688-9.
5. Orhan Z, Kara H, Tuzuner T, Sencan I, Alper M. Primary subcutaneous cyst hydatid disease in proximal thigh: an unusual localisation: a case report. *BMC Musculoskelet Disord* 2003;4:25.
6. Findikcioglu A, Kilic D, Canpolat T, Hatipoglu A. Primary hydatid disease of the chest wall. *Ann Thorac Cardiovasc Surg* 2007;13:203-5.
7. Kulaçoğlu IH, Oruç MT, Kocaerkek Z, Seçkin S, Coşkun F. Unusual locations of hydatid disease: an evaluation of 77 cases. *Turk J Gastroenterol* 2001;12:299-302.