

Distal radial artery ligation for treatment of steal syndrome in a distal radiocephalic arteriovenous fistula

Distal radiosefalik arteriyovenöz fistülde çalma sendromu tedavisi için distal radial arter ligasyonu

Kamil Boyacıoğlu,¹ Özgür Kocamaz,² Bülent Mert,¹ Nihan Kayalar,¹ Vedat Erentuğ¹

Institution where the research was done:

Bağcılar Training and Reserach Hospital, İstanbul, Turkey

Author Affiliations:

¹Department of Cardiovascular Surgery, Bağcılar Training and Reserach Hospital, İstanbul, Turkey

²Department of Cardiovascular Surgery, İstanbul Research and Training Hospital, İstanbul, Turkey

ABSTRACT

Hand ischemia in patients on hemodialysis treatment due to end-stage renal failure is a special condition. The presence of steal syndrome in patients with a radiocephalic arteriovenous fistula is quite rare with a different pathophysiological etiology. In this article, we present a 65-year-old female patient who underwent distal radial artery ligation. The patient presented with a nonhealing ulcer of her right hand as a result of ischemic steal syndrome 11 years after opening of a right radiocephalic arteriovenous fistula due to shunting from ulnar artery to the arteriovenous fistula retrogradely via palmar arch.

Keywords: Arteriovenous fistula; chronic kidney failure; radial artery; steal syndrome; surgery.

An arterial steal is an important cause of hand ischemia associated with upper extremity arteriovenous fistulas (AVFs). Although this devastating complication is most frequently associated with brachial artery fistulas, it can also occur with forearm AVFs at low incidence rates ranging between 0.25 and 1.8%.^[1] In these cases, the blood flow is directed from the ulnar and interosseous arteries to a low-resistant arteriovenous access site with a retrograde flow via the palmar arch, resulting in distal hypoperfusion and peripheral ischemia.^[2] If left untreated, arterial steal syndrome may cause extremity weakness and coolness, severe pain, ulceration, and gangrene.

ÖZ

Son dönem böbrek yetersizliği nedeniyle hemodiyaliz tedavisi gören hastalarda ortaya çıkan el iskemisi özel bir durumdur. Radiosefalik arteriyovenöz fistülü olan hastalarda çalma sendromu oluşması farklı bir patofizyolojik etyoloji ile oldukça nadirdir. Bu yazıda, distal radial arter ligasyonu yapılan 65 yaşında bir kadın hasta sunuldu. Sağ radiosefalik arteriyovenöz fistül açılan hasta 11 sene sonra ulnar arterden palmar ark yoluyla retrograd olarak arteriyovenöz fistüle şant yapan ve iskemik çalma sendromu oluşturan ve bu nedenle iyileşmeyen sağ el ülseri ile başvurdu.

Anahtar sözcükler: Arteriyovenöz fistül; kronik böbrek yetersizliği; radial arter; çalma sendromu; cerrahi.

A number of techniques have been proposed to prevent arterial steals and maintain arteriovenous hemodialysis function at the access point,^[2-7] and occlusion of the distal radial artery flow may correct hand ischemia secondary to a longstanding radiocephalic AVF. Herein, we present the successful treatment of hand ischemia associated with a radiocephalic fistula at the snuff box via ligation of the radial artery distal to the AVF.

CASE REPORT

A 65-year-old woman with a history of end-stage renal disease secondary to type 1 diabetes mellitus (DM)



Available online at
www.tgkdc.dergisi.org
doi: 10.5606/tgkdc.dergisi.2015.11142
QR (Quick Response) Code

Received: November 09, 2014 Accepted: November 19, 2014

Correspondence: Kamil Boyacıoğlu, M.D. Bağcılar Eğitim ve Araştırma Hastanesi Kalp ve Damar Cerrahisi Kliniği, 34200 Bağcılar, İstanbul, Turkey.

Tel: +90 505 - 494 99 59 e-mail: kamilboyacioglu@yahoo.com.tr

and hypertension (HT) was evaluated at our outpatient clinic. She also had a two-month history of right second finger ulceration and paresthesia along with pain in the first to third fingers of her right hand. In addition, the patient had a right radiocephalic AVF which had been functional for 11 years, and she was receiving hemodialysis three times a week through this fistula. Severe pain associated with arterial steals typically develops during dialysis.

A physical examination revealed that she had a well-developed right radiocephalic AVF with a palpable thrill. Her radial pulse was not palpable distal to the AVF, but she did have monophasic Doppler signals. Moreover, when compression was performed on the fistula by hand until the thrill disappeared, the radial pulse could be palpated distal to the fistula. The thenar part of her hand was cool to the touch, and she had a circumscribed 1 cm ulceration on her right second finger as well as nail atrophy on her first and second fingers. There was no arm edema or sign of high-output heart failure, which might have been due to the overflow through the AVF.

Conventional angiography was performed in order to diagnose the steal syndrome and rule out the presence of any arterial stenosis which might have caused the ischemia. It showed the absence of an

antegrade radial artery flow beyond the radiocephalic anastomosis along with the presence of a retrograde flow at that arterial segment (Figure 1). The ulnar artery and palmar arch were patent, and the ulnar artery flow was shunted to the AVF in a retrograde manner via the palmar arch (Figure 2).

Although we initially considered banding the venous outflow of the AVF, the absence of arm edema and lack of any signs of heart failure along with the relatively small size of the venous outflow suggested that there would be a high risk of AVF thrombosis after the procedure. The intact palmar arch was well perfused by the ulnar artery, so we decided that the best option, both to relieve her symptoms and salvage the AVF, was to interrupt the retrograde flow to the AVF. Because the ulnar artery was primarily supplying the AVF in a retrograde manner and the AVF was close to the thenar zone, we chose surgery as the best treatment option for our patient.

Ligation of the distal radial artery was performed using a 1.0 cm incision and blunt dissection, and a 2.0 nylon suture (Ethicon Inc., Somerville, NJ, USA) was used to tie off the artery while the patient was under local anesthesia. There were no complications after the ligation, and no infections occurred at the

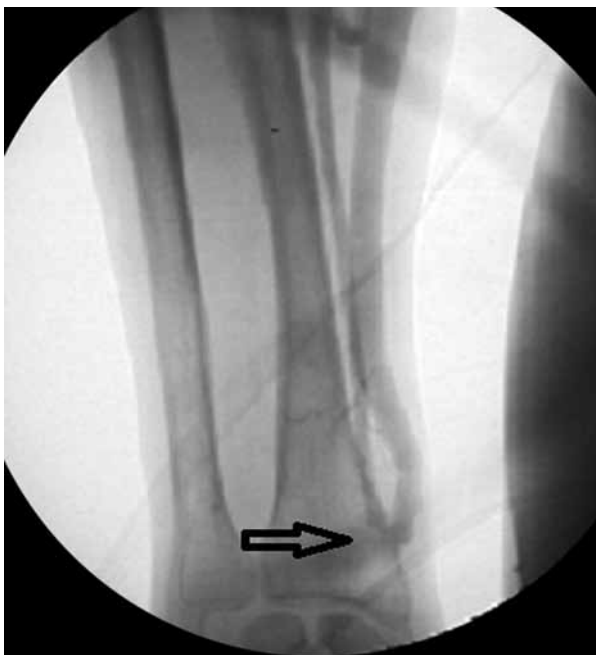

Figure 1. Conventional angiography shows the absence of antegrade radial artery flow beyond the radiocephalic anastomosis. The entire flow of the radial artery drains into the arteriovenous fistula.

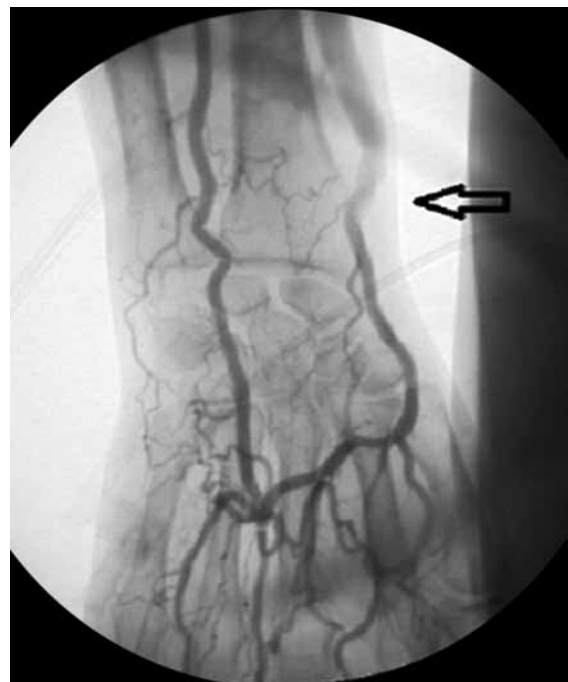


Figure 2. Conventional angiography shows the retrograde flow of the ulnar artery into the arteriovenous fistula via the palmar arch.

cut-down site. The AVF thrill was also palpable after the surgery. The patient was discharged on the same day uneventfully, but prior to being discharged, a pulse oximeter demonstrated increased wave amplitude on the first and second fingers and the OS levels of all of the fingers were almost the same. The ulceration of the finger healed within one month, and after nine months of follow-up, the patient had complete symptomatic relief. Furthermore, her fistula was patent and functional at that time.

DISCUSSION

Although many patients are asymptomatic, the presence of AVFs may significantly alter the physiology of local blood flow and can also affect the general circulation, brachial arterial origin, peripheral arteriosclerosis, DM, female gender, age, previous ipsilateral AVFs, and high-flow AVFs are the risk factors for arterial steals associated with arteriovenous hemodialysis access sites.^[1,8] Ischemic steal syndrome is less common in radiocephalic AVFs.

A retrograde flow in the radial artery away from the hand occurs in 70% of radiocephalic AVFs, and this usually does not cause ischemia.^[9] In addition, the augmentation of the radiocephalic AVF from the ulnar artery via the shunting of blood through a hypertrophied palmar arch may cause steals and distal ischemia, as was the case with our patient. If the steal syndrome becomes severe, surgical intervention should be carried out.

Noninvasive Doppler ultrasonography (USG), access flow measurements, noninvasive digital pressure tests, and angiography are vital for diagnosing steal syndrome and may help in the selection of treatment options. In our patient, we used Doppler USG and conventional angiography to confirm the diagnosis, and the angiography showed the retrograde direction of flow in the radial artery distal to the AVF and confirmed the presence of an intact ulnar artery and palmar arch. These findings were the impetus for our decision to interrupt the retrograde flow to the distal radial artery from the ulnar artery.

Closing the AVF usually resolves the symptoms of these patients, but arteriovenous access is lost. Banding is another alternative intervention that can be utilized to treat steals associated with high flow, but it has a high risk of thrombosis. Moreover, banding has a success rate of just 62%, and reintervention is often necessary.^[10] In our opinion, these techniques were not the best option for our patient because the number of access sites was limited due to multiple

previous AVF operations. Since there were no other clinical signs of high fistula flow, such as arm edema or heart failure, we preferred a method that would save the functional AVF. Furthermore, interrupting the retrograde ulnar flow to the AVF was supposed to decrease the total fistula flow and prevent other high-flow symptoms.

The distal revascularization and interval ligation (DRIL) procedure is commonly used to treat ischemic steal syndrome in arteriovenous access sites in the upper arm. This strategy is safe, relieves the hand ischemia, and effectively ensures access patency. The five-year patency rate for DRIL is 71%.^[4] Although this technique is durable and useful, it has limited success when small target vessels are present^[2] and is rarely performed in the forearm. For this reason, we preferred to use only distal radial artery ligation to eliminate the flow reversal, and the presence of a patent ulnar artery and a well developed palmar arch ensured the success of the distal perfusion.

In radiocephalic AVFs, distal radial artery ligation or coil embolization may prevent ischemic steal syndrome and maintain fistula function,^[2] but a correct diagnosis in these cases is crucial. Therefore, the presence of a patent ulnar artery and shunting from the ulnar artery via the palmar arch should be documented. Distal radial artery ligation is more cost effective and less risky than the coil embolization. Moreover, coil embolization has the risk of migration during deployment^[2] and adds complications such as access zone hematomas, pseudoaneurysms, arterial thromboembolisms, and dissection that are associated with this procedure. We opted for surgical intervention for our patient because it could be implemented much easier than any other option.

In conclusion, distal radial artery ligation is a safe and effective technique for treating steal syndrome associated with radiocephalic fistulas. It ameliorates hand ischemia by interrupting the retrograde flow to the distal radial artery from the ulnar artery while preserving access. In addition, this method is quite easy to perform and has minimal morbidity and fewer complications.

Declaration of conflicting interests

The authors declared no conflicts of interest with respect to the authorship and/or publication of this article.

Funding

The authors received no financial support for the research and/or authorship of this article.

REFERENCES

1. Padberg FT Jr, Calligaro KD, Sidawy AN. Complications of arteriovenous hemodialysis access: recognition and management. *J Vasc Surg* 2008;48:55-80.
2. Miller GA, Khariton K, Kardos SV, Koh E, Goel N, Khariton A. Flow interruption of the distal radial artery: treatment for finger ischemia in a matured radiocephalic AVF. *J Vasc Access* 2008;9:58-63.
3. Corfield L, Muller J, Ryan J, Bond R. Distalization of the anastomosis: an effective treatment for dialysis access-associated steal syndrome. *Ann Vasc Surg* 2012;26:572.e11-3
4. Huber TS, Brown MP, Seeger JM, Lee WA. Midterm outcome after the distal revascularization and interval ligation (DRIL) procedure. *J Vasc Surg* 2008;48:926-32.
5. Zanol J, Kruger U, Scholz H. Proximalization of the arterial inflow: a new technique to treat access-related ischemia. *J Vasc Surg* 2006;43:1216-21.
6. Shukla PA, Contractor S, Huang JT, Curi MA. Coil embolization as a treatment alternative for dialysis-associated steal syndrome. *Vasc Endovascular Surg* 2012;46:546-9.
7. Hastaoğlu İA, Parlar H, Toköz H, Bilgen F. Hemodiyaliz amaçlı arteriyovenöz fistüllerde distal hipoperfüzyona bağlı iskemik sendrom. *Türk Gogus Kalp Dama* 2013;21:936-43.
8. Tordoir JH, Dammers R, van der Sande FM. Upper extremity ischemia and hemodialysis vascular access. *Eur J Vasc Endovasc Surg* 2004;27:1-5.
9. Hye RJ, Wolf YG. Ischemic monomelic neuropathy: an under-recognized complication of hemodialysis access. *Ann Vasc Surg* 1994;8:578-82.
10. Gupta N, Yuo TH, Konig G 4th, Dillavou E, Leers SA, Chaer RA, et al. Treatment strategies of arterial steal after arteriovenous access. *J Vasc Surg* 2011;54:162-7.