

## Guide wire-balloon technique to prevent occlusion of the left main coronary artery during transcatheter aortic valve implantation: Case report

*Transkateter aort kapak implantasyonu sırasında sol ana koroner arter tıkanıklığını önlemede kılavuz tel-balon tekniği: Olgu sunumu*

Hüseyin Ayhan, Hacı Ahmet Kasapkara, Hakan Süygün, Tahir Durmaz, Engin Bozkurt

*Institution where the research was done:*

Ankara Atatürk Training and Research Hospital, Ankara, Turkey

*Author Affiliations:*

Department of Cardiology, Medical Faculty of Yıldırım Beyazıt University, Ankara, Turkey

### ABSTRACT

Transcatheter aortic valve implantation (TAVI) is an effective and reliable method in the treatment of patients with serious aortic stenosis who are at high risk or inconvenient for surgery. Nevertheless, various procedure-related complications may develop. One of these complications is the obstruction of the ostial left main coronary artery (LMCA) due to calcification, native valve cusp, or bioprosthesis valve. It is difficult to treat LMCA obstruction and potentially it ends up catastrophically. Therefore, the aim must be to prevent LMCA obstruction. This article presents an 85-year-old female patient in whom acute LMCA obstruction was prevented by noticing that native valve calcification would obstruct LMCA during TAVI. To our knowledge, the effective method we used to prevent LMCA obstruction has not been reported in the literature.

**Keywords:** Calcification; left main coronary artery; transcatheter aortic valve implantation.

### ÖZ

Ciddi aort darlığı olan, cerrahi açıdan yüksek riskli veya uygun olmayan hastaların tedavisinde transkateter aort kapak implantasyonu (TAKİ) etkili ve güvenilir bir yöntemdir. Buna rağmen, işleme ait çeşitli komplikasyonlar gelişebilmektedir. Bu komplikasyonlardan biri, sol ana koroner arter (SAKA) ostiyumunun kalsifikasyon, natif kapak küspü veya biyoprotez kapak tarafından tıkanmasıdır. Sol ana koroner arter tıkanması zor tedavi edilir ve olasılıkla katastrofik şekilde sonuçlanır. Dolayısıyla, amaç SAKA'nın tıkanmasını önlemek olmalıdır. Bu yazıda TAKİ sırasında natif kapak kalsifikasyonunun SAKA'yı tıkayacağı fark edilerek akut SAKA tıkanmasının önlenildiği 85 yaşında bir kadın hasta sunuldu. Bildiğimiz kadarıyla, SAKA tıkanıklığını önlemek için kullandığımız etkili yöntem literatürde bildirilmemiştir.

**Anahtar sözcükler:** Kalsifikasyon; sol ana koroner arter; transkateter aort kapak implantasyonu.

Transcatheter aortic valve implantation (TAVI) is a therapeutic method used for patients with serious aortic stenosis who are at high risk or those for whom surgery is not feasible. Although it is a less invasive procedure than surgery, major vascular complications and stroke are more common during TAVI.<sup>[1,2]</sup> Coronary artery obstruction during valve implantation is a rare

but potentially fatal complication,<sup>[3]</sup> and Thomas et al.<sup>[4]</sup> determined that there is an incidence rate of 0.6% after TAVI,<sup>[4]</sup> with left main coronary artery (LMCA) obstruction being the most common complication.<sup>[5]</sup> With this type of obstruction, treatment is quite difficult for the patients that develop cardiac arrest and collapse. First, obstruction is prevented by performing

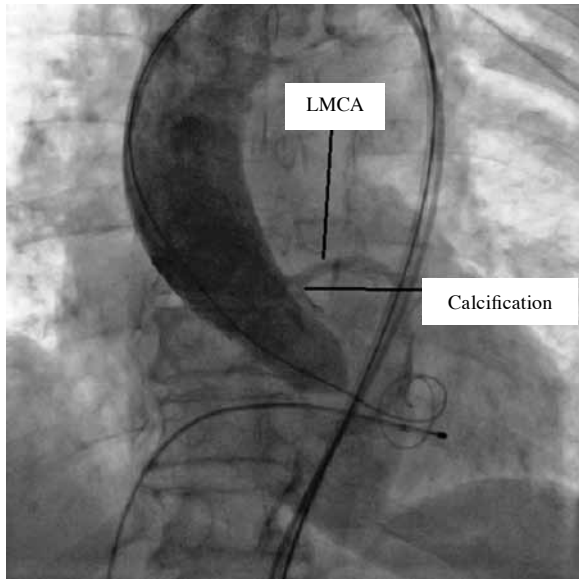


Available online at  
www.tgkdc.dergisi.org  
doi: 10.5606/tgkdc.dergisi.2015.10969  
QR (Quick Response) Code

Received: September 27, 2014 Accepted: December 30, 2014

Correspondence: Hüseyin Ayhan, M.D. Ankara Atatürk Eğitim ve Araştırma Hastanesi Kardiyoloji Kliniği, 06800 Çankaya, Ankara, Turkey.

Tel: +90 312 - 291 25 25 e-mail: huseyinayhan44@yahoo.com



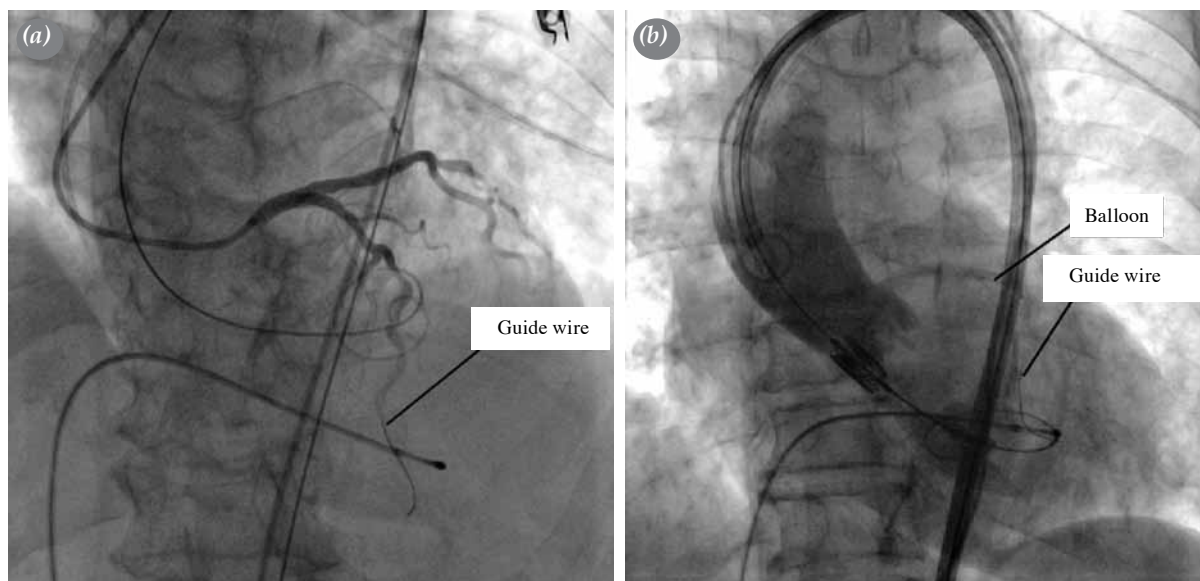
**Figure 1.** Fluoroscopic image of the calcification displacement toward the left main coronary artery (LMCA) ostium during the aortic balloon valvuloplasty.

the necessary interventions before, during, and after the procedure. Herein, we present the case of a patient who did not experience obstruction because our careful evaluation recognized that the LMCA would have become obstructed by calcification if a transfemoral aortic valve implantation had been performed. Hence, our goal is to show that LMCA obstruction can be prevented if precise evaluations take place during the procedure.

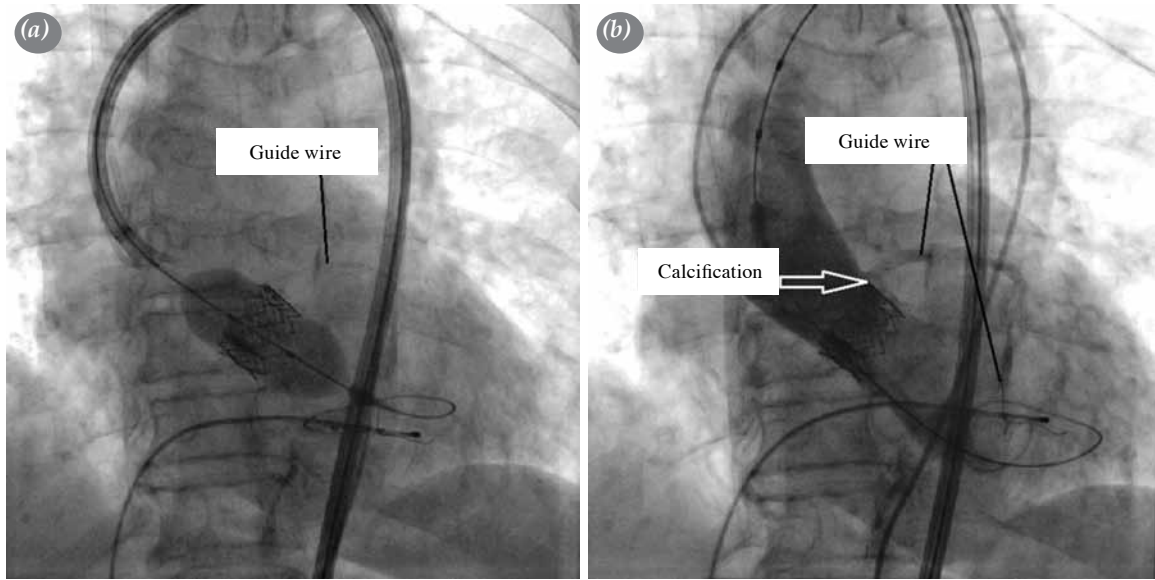
## CASE REPORT

An 85-year-old female patient with known hypertension (HT) and chronic obstructive pulmonary disease (COPD) was admitted to our clinic because of a one-month history of gradually worsening shortness of breath. A physical examination of the patient, who had been categorized as New York Heart Association (NYHA) class 3, revealed a 3/6 systolic ejection murmur in all cardiac foci, which was heard best in the aortic focus, as well as crepitating rales and decreased breathing sounds in the basal aspect of the lungs. Electrocardiography revealed sinus rhythm and nonspecific ST-T wave changes, and severe aortic stenosis (an aortic velocity of 5.5 m/sec, a maximum gradient of 123 mmHg, a mean gradient of 80 mmHg; and an aortic valve area of 0.31 cm<sup>2</sup>) was diagnosed based on the results of transthoracic echocardiography (TTE). The patient's systolic pulmonary artery pressure (sPAP) was 60 mmHg, and her left ventricular ejection fraction (LVEF) was 60%. In addition, her Society of Thoracic Surgeons (STS) score was 7.8, and she had a logistic European System for Cardiac Operative Risk Evaluation (EuroSCORE) of 29.8%. Based on her advanced age and concomitant diseases, the cardiac team decided that TAVI was the best treatment option.

A calcified tricuspid aortic valve was observed on transesophageal echocardiography (TEE), and the diameter of the aortic annulus was 19 mm. A coronary angiogram (CAG) performed prior to the TAVI revealed minimal coronary artery disease (CAD).



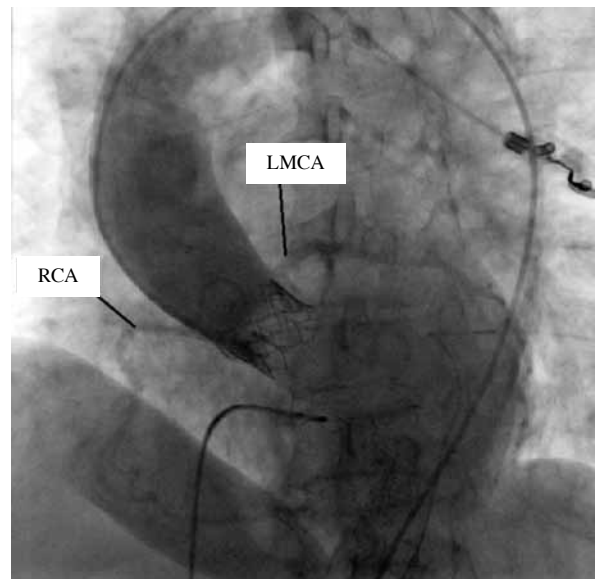
**Figure 2.** Fluoroscopic image of (a) the cannulation of the left main coronary artery (LMCA) ostium via a guide catheter inserted into the left anterior descending artery with a guidewire and (b) the insertion of the balloon.



**Figure 3.** Fluoroscopic image of (a) the removal of the guide catheter and the guidewire and (b) the balloon protecting the coronary blood flow backwards.

Furthermore, we verified via peripheral angiography that the diameter and morphology of the iliofemoral arteries were suitable for TAVI. The distance between the aortic annulus and LMCA was 12 mm; however, the calcification had already moved to the LMCA ostium. The patient was admitted to the catheter laboratory where a balloon valvuloplasty was first performed under local anesthesia in company with rapid pacing. Native aortic valve calcification was detected in the ostium of the LMCA during the aortography performed along with the balloon valvuloplasty (Figure 1). We then decided to preserve the LMCA so that this calcification did not obstruct this artery. A 6 French (F) sheath was inserted into the brachial artery because the right femoral artery would be used for the TAVI and the left femoral artery would be used for the arcus aortography, the latter of which was necessary to determine the correct position of the valve during the valve implantation. Thereafter, the LMCA was cannulated using a Judkins left 4.0 (JLe) guide catheter (Cordis Corporation, a Johnson & Johnson Company, Miami, FL), and a 0.014 inch floppy guidewire was inserted into the left anterior descending (LAD) artery. Next, a 3.0x20 mm balloon was inserted into the LAD if intervention was needed for a calcification-obstructed LMCA (Figures 2a and b). Because the LMCA was safe, the guidewire and balloon were left in the LMCA to protect the coronary flow, but the guide catheter was pulled back so it was not left between the bioprosthetic valve and aorta. A 23 mm Edwards Sapien XT transcatheter heart valve

(Edwards Lifesciences Corp., Irvine, CA, USA) was then implanted in company with rapid pacing. The subsequent aortography demonstrated that the calcification was between the bioprosthetic valve and the aortic wall and that the LMCA flow was good (Figures 3a and b). We also observed that the aortic valve was in the proper position. The mean gradient was 8 mmHg, and there was mild paravalvular aortic regurgitation. Angiography of the arcus aorta demon-



**Figure 4.** Aortographic image demonstrating the patency of the left main coronary artery (LMCA) and the right coronary artery (RCA) after the valve implantation.

strated non-selectively patent left and right coronary arteries and mild aortic regurgitation (Figure 4), and the procedure was deemed to be successful. After the procedure, the right femoral artery was closed using the Prostar® XL 10F Percutaneous Vascular System (PVS) (Abbott Vascular, Santa Clara, CA, USA). The patient was discharged from the hospital after three days, and she was categorized as NYHA class 2 on the first-month control visit with a mean gradient of 12 mmHg as detected by TTE.

## DISCUSSION

Acute coronary syndrome is a life-threatening, rarely encountered complication of TAVI with an incidence rate of 0.6-4.1% in the case studies or TAVI series.<sup>[5]</sup> Obstruction may occur either during the procedure or several hours later. Clinical presentation may include hemodynamic impairment, hypotension, ST-T alterations, and newly developed segmental wall motion abnormalities. The most comprehensive evaluation on this subject was the review published by Ribeiro et al.,<sup>[6]</sup> who found that coronary obstruction takes place in females, in patients who have not undergone a bypass, and in cases where an expandable valve was used. They also determined that the LMCA is obstructed more frequently than other arteries. In addition, LMCA and right coronary artery obstructions have been reported after transfemoral implantation involving the Edwards Sapien XT valve.<sup>[7-9]</sup> The mechanisms of coronary obstruction are the following:<sup>[6]</sup> native cusps displacement and an obstructed coronary ostium, a short distance (<10 mm) between the low-set ostial LMCA and the aortic annulus, serious calcification of the leaflets, a stenotic aortic root, and a shallow sinus of Valsalva. Although a low-set LMCA is a risk factor, the distance between the LMCA and annulus is >10 mm in half of the cases<sup>[6]</sup> because other mechanisms can make up for this troubling issue. Although the distance was 12 mm in our patient, the calcification had moved to the LMCA ostium. In addition, there was no data available regarding the relationship between the access site and the LMCA obstruction.

Uyar et al.<sup>[10]</sup> evaluated whether the transapical, transfemoral and transaortic approach is best and determined that the transfemoral way should be the first choice for an access site. In previous case reports, percutaneous coronary intervention (PCI) was successfully performed in the treatment of such patients;<sup>[2,7]</sup> however, since sudden circulatory collapse is a common condition following LMCA obstruction, manual circulatory support must be initiated as soon as possible for this to be successful.

A precise evaluation of the aortic valve and aortic root is of great importance for the prevention of coronary obstructions because it is likely to cause catastrophic results. Previous publications on the management of coronary occlusion following TAVI have suggested that patients should undergo concurrent aortography with a balloon valvuloplasty and routine aortography after valve implantation to determine whether a coronary obstruction is present.<sup>[4]</sup> In our case, the calcification was recognized via careful scrutinization of the aortography that was performed during the balloon valvuloplasty.

To the best of our knowledge, no previous studies exist that have focused on using routine aortography or selective coronary angiography after an aortic valvuloplasty and valve replacement for this group of patients. Our aim was to highlight the importance of being meticulous when performing this procedure since these patients are at a high risk for coronary obstruction and have a low-set LMCA. Furthermore, we wanted to stress the benefits of keeping the guide-wire and balloon in the coronary artery during the PCI before the valve implantation if coronary obstruction is suspected.

### Declaration of conflicting interests

The authors declared no conflicts of interest with respect to the authorship and/or publication of this article.

### Funding

The authors received no financial support for the research and/or authorship of this article.

## REFERENCES

1. Lefèvre T, Kappetein AP, Wolner E, Nataf P, Thomas M, Schächinger V, et al. One year follow-up of the multi-centre European PARTNER transcatheter heart valve study. *Eur Heart J* 2011;32:148-57.
2. Stabile E, Sorropago G, Cioppa A, Cota L, Agrusta M, Lucchetti V, et al. Acute left main obstructions following TAVI. *EuroIntervention* 2010;6:100-5.
3. Webb JG, Chandavimol M, Thompson CR, Ricci DR, Carere RG, Munt BI, et al. Percutaneous aortic valve implantation retrograde from the femoral artery. *Circulation* 2006;113:842-50.
4. Thomas M, Schymik G, Walther T, Himbert D, Lefèvre T, Treede H, et al. Thirty-day results of the SAPIEN aortic Bioprosthesis European Outcome (SOURCE) Registry: A European registry of transcatheter aortic valve implantation using the Edwards SAPIEN valve. *Circulation* 2010;122:62-9.
5. Bartorelli AL, Andreini D, Sisillo E, Tamborini G, Fusari M, Biglioli P. Left main coronary artery occlusion after percutaneous aortic valve implantation. *Ann Thorac Surg* 2010;89:953-5.

6. Ribeiro HB, Nombela-Franco L, Urena M, Mok M, Pasian S, Doyle D, et al. Coronary obstruction following transcatheter aortic valve implantation: a systematic review. *JACC Cardiovasc Interv* 2013;6:452-61.
7. Kapadia SR, Svensson L, Tuzcu EM. Successful percutaneous management of left main trunk occlusion during percutaneous aortic valve replacement. *Catheter Cardiovasc Interv* 2009;73:966-72.
8. Spiro J, Nadeem A, Doshi SN. Delayed left main stem obstruction following successful TAVI with an Edwards SAPIEN XT valve: successful resuscitation and percutaneous coronary intervention using a non-invasive automated chest compression device (AutoPulse). *J Invasive Cardiol* 2012;24:224-8.
9. Gogas BD, Zacharoulis AA, Antoniadis AG. Acute coronary occlusion following TAVI. *Catheter Cardiovasc Interv* 2011;77:435-8.
10. Uyar IS, Gül I, Okur FF. Which one is the best access when the transfemoral way is not a suitable access for TAVI patients? *Türk Gogus Kalp Dama* 2014;22:897-8.