

Epithelial membrane antigen in differential diagnosis of malignant mesothelioma, metastatic adenocarcinoma, and reactive mesothelial hyperplasia

Malign mezotelyoma, metastatik adenokarsinoma ve reaktif mezotelyal hiperplazi ayırıcı tanısında epitelyal membran antijeni

Sibel Arslan,¹ Kemal Bakır,² Levent Elbeyli³

Institution where the research was done:
Medical Faculty of Gaziantep University, Gaziantep, Turkey

Author Affiliations:

¹Department of Pathology, Gaziantep Şehitkamil State Hospital, Gaziantep, Turkey
Departments of ²Pathology, ³Thoracic Surgery, Medical Faculty of Gaziantep University, Gaziantep, Turkey

ABSTRACT

Background: This study aims to investigate the usefulness of epithelial membrane antigen immunohistochemical marker in differential diagnosis of malignant mesothelioma, reactive mesothelial hyperplasia, and metastatic adenocarcinoma.

Methods: In this study, 67 malignant mesothelioma, 18 reactive mesothelial hyperplasia, and 33 metastatic adenocarcinoma specimens were examined and stained with epithelial membrane antigen.

Results: Staining with epithelial membrane antigen was observed in 45 of 67 malignant mesotheliomas cases (68.7%) and all the metastatic adenocarcinoma cases (100%). All metastatic adenocarcinomas showed prominently expressed epithelial membrane antigen, whereas weak positivity with epithelial membrane antigen was detected in only one case with reactive mesothelial hyperplasia. Metastatic adenocarcinoma showed a statistically significantly stronger expression compared to mesothelial hyperplasia ($p<0.001$). Sensitivity and specificity for malignant and benign cases were 78% and 94%, respectively.

Conclusion: Epithelial membrane antigen is a useful positive marker of malignant mesothelioma and metastatic adenocarcinoma. Also, it plays a significant role in distinguishing neoplastic mesothelium from non-neoplastic mesothelium.

Keywords: Epithelial membrane antigen; malignant mesothelioma; metastatic adenocarcinoma; reactive mesothelial hyperplasia.

ÖZ

Amaç: Bu çalışmada malign mezotelyoma, reaktif mezotelyal hiperplazi ve metastatik adenokarsinoma ayırıcı tanısında epitelyal membran antijeni immünohistokimyasal belirleyicisinin yararlılığı araştırıldı.

Çalışma planı: Çalışmada 67 malign mezotelyoma, 18 reaktif mezotelyal hiperplazi ve 33 metastatik adenokarsinoma örneği incelendi ve epitelyal membran antijeni ile boyandı.

Bulgular: Altmış yedi malign mezotelyoma olgusunun 45'inde (%68.7) ve tüm metastatik adenokarsinoma olgularında (%100) epitelyal membran antijeni ile pozitif boyanma izlendi. Tüm metastatik adenokarsinomlar epitelyal membran antijeni ile güçlü pozitiflik gösterir iken, yalnızca bir reaktif mezotelyal hiperplazi olgusunda zayıf pozitiflik saptandı. Metastatik adenokarsinom, mezotelyal hiperplasiye kıyasla, istatistiksel olarak anlamlı açıdan daha güçlü bir ilişki gösterdi ($p<0.001$). Malign ve benign olgular için duyarlılık ve özgüllük sırası ile %78 ve %94 idi.

Sonuç: Epitelyal membran antijeni malign mezotelyoma ve metastatik adenokarsinoma olguları için yararlı bir pozitif belirleyicidir. Ayrıca, neoplastik mezoteli neoplastik olmayan mezotelden ayırmada önemli rol oynar.

Anahtar sözcükler: Epitelyal membran antijeni; malign mezotelyoma; metastatik adenokarsinoma; reaktif mezotelyal hiperplazi.



Available online at
www.tgkdc.dergisi.org
doi: 10.5606/tgkdc.dergisi.2016.11606
QR (Quick Response) Code

Received: February 19, 2015 Accepted: May 02, 2015

Correspondence: Sibel Arslan, MD. Gaziantep Şehitkamil Devlet Hastanesi, Patoloji Kliniği, 27100 Şehitkamil, Gaziantep, Turkey.

Tel: +90 530 - 693 69 11 e-mail: dr.sibelkarahan@hotmail.com

Malignant mesothelioma (MM) is a primary tumor of serous membranes, especially seen in the pleura which accounts for approximately 70% of all cases of MM.^[1] Histologically, MM has been divided into epithelioid, sarcomatoid and biphasic types.^[2] Median survival after diagnosis is 4.5 to 17 months, depending on histological type, tumor stage, performance status and treatment, and other factors such as sex and age.^[3-5]

Histopathological differentiation of MM from metastatic adenocarcinoma (MA) and reactive mesothelial hyperplasia (RMH) is often difficult, particularly in small biopsy specimens.^[6,7] Several morphological features have been identified,^[8] but these are not specific criteria. Clinical, radiologic, histological, and histochemical studies can be helpful in differential diagnosis, but their diagnostic utility is limited.

Immunohistochemistry is valuable for the differential diagnosis.^[9] There are several studies about immunohistochemical markers. International Mesothelioma Panel recommended using at least two mesothelial cell makers and two carcinoma-related markers in distinction of MM from MA.^[10]

Epithelial membrane antigen (EMA) is expressed both in MM and MA,^[11] and appears to be the most useful marker in distinguishing benign from malignant mesothelial proliferations since EMA appears to be preferentially expressed in neoplastic mesothelium.^[12] Thus, in this study, we aimed to investigate the usefulness of EMA in differential diagnosis of MM, RMH, and MA.

PATIENTS AND METHODS

Paraffin-embedded blocks from surgical material of 67 malign mesotheliomas, 18 reactive mesothelial hyperplasias, and 33 metastatic adenocarcinomas were retrieved between January 2005 and June 2011 from the archive of the Department of Pathology of the University of Gaziantep. Each case was reviewed, and all cases were diagnosed by currently accepted histological criteria combined with immunohistochemical features. Immunohistochemistry was performed on

formalin-fixed, paraffin-embedded tissue sections using an avidin-biotin-peroxidase technique EMA (clone E29, Cellmarq, dilution 1: 200). Appropriate sections were cut 4 µm thick. Immunoreactivity was scored as negative (no immunostaining) or positive.

Differences of staining ratio between MM, RMH, and MA groups were tested by the chi-square. A *p* value of <0.05 was accepted as statistically significant.

RESULTS

The immunohistochemical results are summarized in Table 1. Epithelial membrane antigen was stained in 45 of 67 MMs (68.7%) and in all the MAs (100%). All MA cases had strong positivity with EMA, whereas only one RMH case showed weak immunoreactivity with EMA. Immunohistochemical staining pattern did not make a differential diagnosis between MM, MA, and RMH cases. Both MM and MA cases showed membranous and cytoplasmic staining and cytoplasmic staining was prominent in most of cases. The positive staining of EMA in MA and negativity of EMA stain in RMH were statistically significant (*p*<0.000). Sensitivity and specificity for malignant and benign cases were 78% and 94%, respectively.

DISCUSSION

Malignant mesothelioma is a primary tumor of pleura, pericardium, and peritoneum. It is a very aggressive tumor and histopathological diagnosis is difficult. Differential diagnosis between MM, RMH, and MA is a problem for pathologists, especially on the basis of routine histology alone. Immunohistochemistry has an important role in the differential diagnosis of these lesions.^[13,14]

Epithelial membrane antigen is a member of the glycosylated protein group (human milk fat globule).^[1] Although EMA is often expressed by both epithelial mesotheliomas and adenocarcinomas, it has been reported to be a valuable marker in differential diagnosis between MM, MA and RMH.^[5,12,15]

Table 1. Epithelial membrane antigen reactivity in malignant mesothelioma, metastatic adenocarcinoma and reactive mesothelial hyperplasia groups

Group	Negative		Positive		Total	
	n	%	n	%	n	%
Reactive mesothelial hyperplasia	17	94.4	1	5.6	18	100.0
Metastatic adenocarcinoma	0	0.0	33	100.0	33	100.0
Malignant mesothelioma	21	31.3	46	68.7	67	100.0
Total	38	32.2	80	67.8	118	100.0

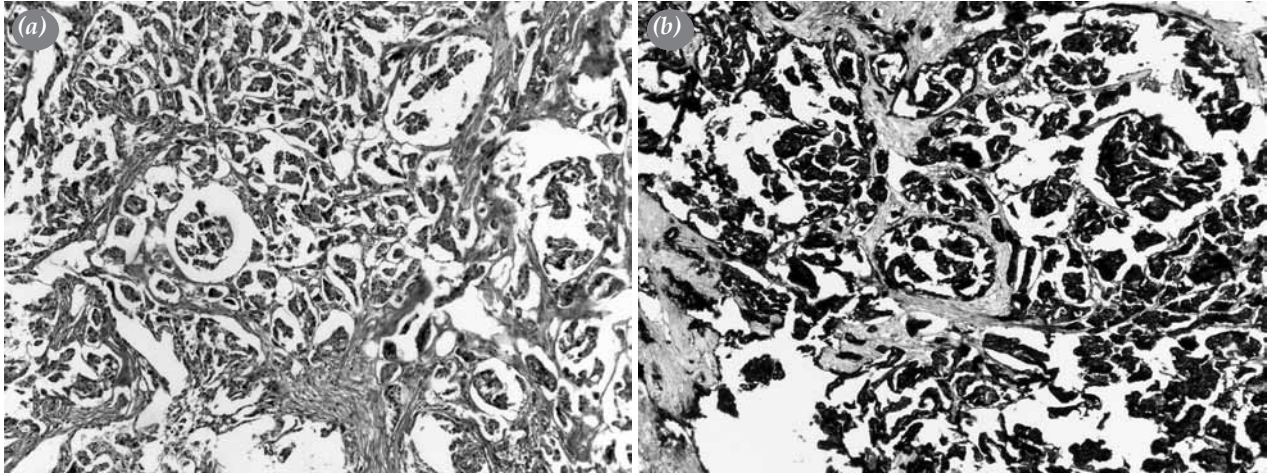


Figure 1. Epithelial malignant mesothelioma. (a) Hematoxylin-eosin stain (H-E x 100); (b) Epithelial membrane antigen immunostain showing a strong cytoplasmic staining (x100).

Saad et al.^[16] used Mc5 and E29 clones of EMA in their study. For the Mc5 clone, there was positive staining in 14/20 cases of MM (70%) and 12/20 (60%) cases of RMH; for the E29 clone, the corresponding results were 15/20 (75%) for MM and 0/20 RMH. They concluded that EMA clone E29 was a reliable marker in differential diagnosis of MM and RMH.

Attanoos et al.^[12] have shown that EMA may be applied as a differential marker for reactive and neoplastic mesothelium, as a positive marker of neoplastic mesothelium.

In several studies, EMA expression has been shown to be between 58 to 100% in MM cases and 0 to 55% in RMH cases.^[5,15,17,18] Walz and Koch.^[19] detected EMA in 33 (76.7%) of 43 mesotheliomas, and Wick et al.^[20] found that 43 (84.3%) of 51 epithelial mesothelioma

expressed EMA. Hammar et al.^[21] detected EMA in 50 (78.1%) of 64 mesotheliomas and in 37 (61.6%) of 60 adenocarcinomas. Gümürdülü et al.^[22] found that EMA stained 50 of 55 MMs and all the adenocarcinoma cases. Similarly, in our series, EMA was expressed in 45 of 67 MMs (68.7%), one of 18 RMH (5.6%), and in all MAs (n=33) (Figure 1, 2 and 3).

Several studies showed that the EMA reactivity in mesotheliomas was often markedly concentrated on the cell membrane, whereas the staining pattern in adenocarcinomas was predominantly cytoplasmic.^[12,22,23] Aydıner and Yerci^[23] detected positive staining in all MM and MA cases (100%); all MM cases were stained in membranous pattern, 75% of MA cases were stained in cytoplasmic pattern, other 25% were stained in both cytoplasmic and

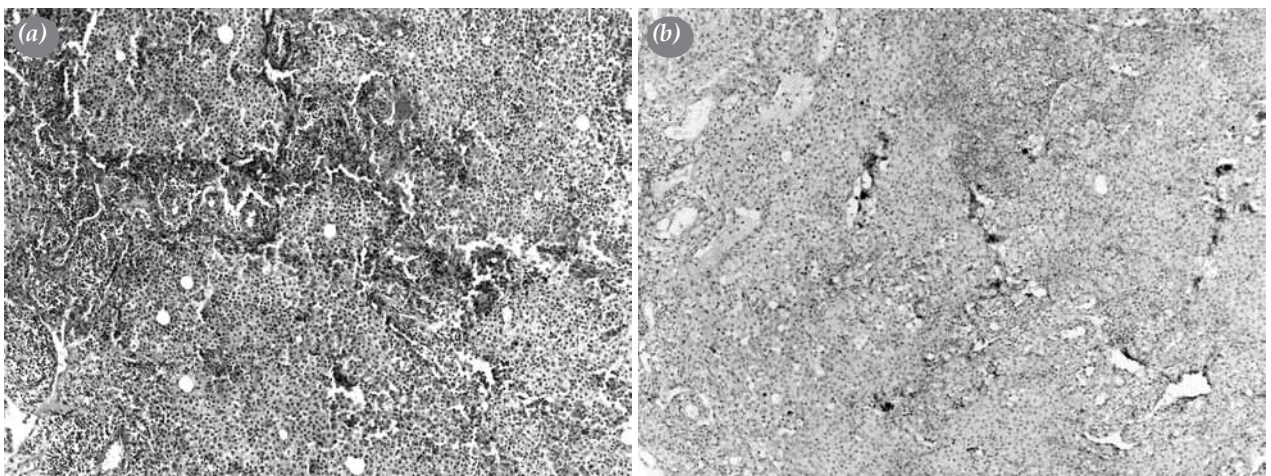


Figure 2. Reactive mesothelial hyperplasia. (a) H-E x 100; (b) Epithelial membrane antigen immunostain is negative (x100).

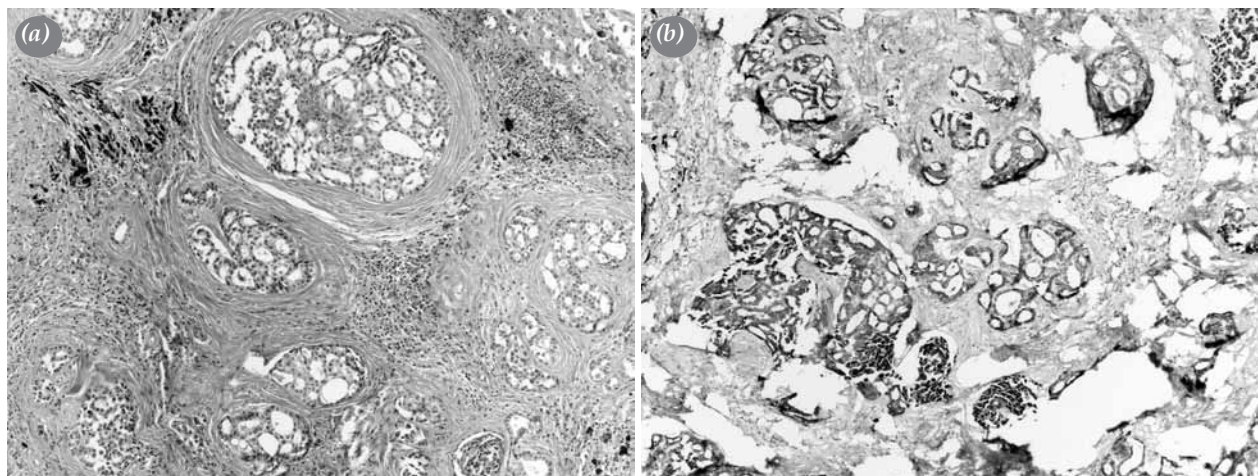


Figure 3. Metastatic adenocarcinoma. (a) H-E x 100); (b) Membranous immunostaining with epithelial membrane antigen (x100).

membranous patterns. However, in our cases, there was no difference between staining patterns and most of the cases stained in cytoplasmic pattern.

Cury et al.^[15] concluded that strong, diffuse, and linear staining for EMA is a good marker of malignancy, although weak focal staining may occur in reactive conditions. Ikeda et al.^[24] showed that, staining intensity of EMA was weak in RMH cases, whereas it was strong in the malignant cells. In our study, EMA staining was weak in one of RMH cases.

King et al.^[13] reviewed 15 papers to evaluate the ability of immunohistochemistry to distinguish between benign and malignant pleural disease, which revealed a sensitivity of 74% and specificity of 89% for EMA. In our study, sensitivity and specificity for malignant and benign cases were 78% and 94%, respectively.

In conclusion, our study suggests that epithelial membrane antigen is a useful positive marker for malignant mesothelioma and metastatic adenocarcinoma. Also, it is a useful marker for distinguishing neoplastic mesothelium from non-neoplastic mesothelium. Epithelial membrane antigen positivity supports malignant mesothelioma; however, epithelial membrane antigen negativity does not eliminate malignant mesothelioma.

Declaration of conflicting interests

The authors declared no conflicts of interest with respect to the authorship and/or publication of this article.

Funding

The authors received no financial support for the research and/or authorship of this article.

REFERENCES

1. Weissferdt A, Kalhor N, Suster S. Malignant mesothelioma with prominent adenomatoid features: a clinicopathologic and immunohistochemical study of 10 cases. *Ann Diagn Pathol* 2011;15:25-9.
2. Allen TC. Recognition of histopathologic patterns of diffuse malignant mesothelioma in differential diagnosis of pleural biopsies. *Arch Pathol Lab Med* 2005;129:1415-20.
3. Ceresoli GL, Locati LD, Ferreri AJ, Cozzarini C, Passoni P, Melloni G, et al. Therapeutic outcome according to histologic subtype in 121 patients with malignant pleural mesothelioma. *Lung Cancer* 2001;34:279-87.
4. Roe OD, Creaney J, Lundgren S, Larsson E, Sandeck H, Boffetta P, et al. Mesothelin-related predictive and prognostic factors in malignant mesothelioma: a nested case-control study. *Lung Cancer* 2008;61:235-43.
5. Wolanski KD, Whitaker D, Shilkin KB, Henderson DW. The use of epithelial membrane antigen and silver-stained nucleolar organizer regions testing in the differential diagnosis of mesothelioma from benign reactive mesothelioses. *Cancer* 1998;82:583-90.
6. Churg A, Colby TV, Cagle P, Corson J, Gibbs AR, Gilks B, et al. The separation of benign and malignant mesothelial proliferations. *Am J Surg Pathol* 2000;24:1183-200.
7. Attanoos RL, Gibbs AR. Pathology of malignant mesothelioma. *Histopathology* 1997;30:403-18.
8. Okada M, Mimura T, Ohbayashi C, Sakuma T, Soejima T, Tsubota N. Radical surgery for malignant pleural mesothelioma: results and prognosis. *Interact Cardiovasc Thorac Surg* 2008;7:102-6.
9. Shebani K, Battifora H, Burke JS. Antigenic phenotype of malignant mesotheliomas and pulmonary adenocarcinomas. An immunohistologic analysis demonstrating the value of Leu M1 antigen. *Am J Pathol* 1986;123:212-9.
10. Husain AN, Colby TV, Ordóñez NG, Krausz T, Borczuk A, Cagle PT, et al. Guidelines for pathologic diagnosis of malignant mesothelioma: a consensus statement from the International Mesothelioma Interest Group. *Arch Pathol Lab Med* 2009;133:1317-31.

11. Borasio P, Berruti A, Billé A, Lausi P, Levra MG, Giardino R, et al. Malignant pleural mesothelioma: clinicopathologic and survival characteristics in a consecutive series of 394 patients. *Eur J Cardiothorac Surg* 2008;33:307-13.
12. Attanoos RL, Griffin A, Gibbs AR. The use of immunohistochemistry in distinguishing reactive from neoplastic mesothelium. A novel use for desmin and comparative evaluation with epithelial membrane antigen, p53, platelet-derived growth factor-receptor, P-glycoprotein and Bcl-2. *Histopathology* 2003;43:231-8.
13. King J, Thatcher N, Pickering C, Hasleton P. Sensitivity and specificity of immunohistochemical antibodies used to distinguish between benign and malignant pleural disease: a systematic review of published reports. *Histopathology* 2006;49:561-8.
14. Addis B, Roche H. Problems in mesothelioma diagnosis. *Histopathology* 2009;54:55-68.
15. Cury PM, Butcher DN, Corrin B, Nicholson AG. The use of histological and immunohistochemical markers to distinguish pleural malignant mesothelioma and in situ mesothelioma from reactive mesothelial hyperplasia and reactive pleural fibrosis. *J Pathol* 1999;189:251-7.
16. Saad RS, Cho P, Liu YL, Silverman JF. The value of epithelial membrane antigen expression in separating benign mesothelial proliferation from malignant mesothelioma: a comparative study. *Diagn Cytopathol* 2005;32:156-9.
17. Dejmek A, Hjerpe A. Reactivity of six antibodies in effusions of mesothelioma, adenocarcinoma and mesotheliosis: stepwise logistic regression analysis. *Cytopathology* 2000;11:8-17.
18. Roberts F, Harper CM, Downie I, Burnett RA. Immunohistochemical analysis still has a limited role in the diagnosis of malignant mesothelioma. A study of thirteen antibodies. *Am J Clin Pathol* 2001;116:253-62.
19. Walz R, Koch HK. Malignant pleural mesothelioma: some aspects of epidemiology, differential diagnosis and prognosis. Histological and immunohistochemical evaluation and follow-up of mesotheliomas diagnosed from 1964 to January 1985. *Pathol Res Pract* 1990;186:124-34.
20. Wick MR, Loy T, Mills SE, Legier JF, Manivel JC. Malignant epithelioid pleural mesothelioma versus peripheral pulmonary adenocarcinoma: a histochemical, ultrastructural, and immunohistologic study of 103 cases. *Hum Pathol* 1990;21:759-66.
21. Hammar SP, Bolen JW, Bockus D, Remington F, Friedman S. Ultrastructural and immunohistochemical features of common lung tumors: an overview. *Ultrastruct Pathol* 1985;9:283-318.
22. Gümürdülü D, Zeren EH, Cagle PT, Kayaseluk F, Alparslan N, Kocabas A, et al. Specificity of MOC-31 and HBME-1 immunohistochemistry in the differential diagnosis of adenocarcinoma and malignant mesothelioma: a study on environmental malignant mesothelioma cases from Turkish villages. *Pathol Oncol Res* 2002;8:188-93.
23. Aydın F, Yerci Ö. Differential diagnosis of malignant mesothelioma versus primary pulmonary adenocarcinoma: an immunohistochemical analysis. *The Turkish Journal of Pathology* 2004;20:60-5.
24. Ikeda K, Tate G, Suzuki T, Kitamura T, Mitsuya T. Diagnostic usefulness of EMA, IMP3, and GLUT-1 for the immunocytochemical distinction of malignant cells from reactive mesothelial cells in effusion cytology using cytopspin preparations. *Diagn Cytopathol* 2011;39:395-401.