

## Late thoracic endovascular stent graft repair after complicated acute type B dissection

*Komplike akut tip B aort diseksiyonundan sonra geç dönem torasik endovasküler stent greft tamiri*

Sedat Özcan,<sup>1</sup> Ayşegül Kunt,<sup>2</sup> Dolunay Odabaşı<sup>3</sup>

*Institution where the research was done:*  
Medical Faculty of Yüzüncü Yıl University, Van, Turkey

*Author Affiliations:*

<sup>1</sup>Department of Cardiovascular Surgery, Medical Faculty of Çanakkale Onsekiz Mart University, Çanakkale, Turkey

<sup>2</sup>Department of Cardiovascular Surgery, Tepecik Training and Research Hospital, İzmir, Turkey

<sup>3</sup>Department of Cardiovascular Surgery, Medical Faculty of Yüzüncü Yıl University, Van, Turkey

### ABSTRACT

Thoracic endovascular stent repair is a life-saving treatment option for patients with complicated type B aortic dissection. In this article, we present a 32-year-old male case referred with ruptured acute type B aortic dissection after injury. Thoracic endovascular stent graft repair was successfully performed 72 hours following the onset of complicated acute type B aortic dissection.

**Keywords:** Acute injury; aorta; endovascular stenting.

The International Registry of Acute Aortic Dissection (IRAD) reported that the mortality rate of patients with acute type B dissection treated medically or surgically was 10.7% and 31.4%, respectively.<sup>[1]</sup> Due to the high mortality rates of surgical treatment and after first described in 1997, the use of thoracic endografting for the treatment of complicated acute type B dissections has gained popularity.<sup>[2]</sup> Of 216 thoracic endovascular aortic aneurysm repairs performed in patients with acute complicated type B dissection, 30-day in-hospital mortality was found to be 21%.<sup>[2]</sup> Steuer et al.<sup>[3]</sup> reported that the long-term outcome varied depending on the severity of the concomitant injuries. Thoracic endovascular aortic repair (TEVAR) is durable during the first 10 years after the surgical procedure; however, still long-term follow-up is needed to show the impact

### ÖZ

Torasik endovasküler stent greft tamiri, komplike tip B aort diseksiyonlu hastalarda hayat kurtarıcı bir tedavi seçeneğidir. Bu yazıda, travma sonucu rüptüre olan akut tip B diseksiyonu ile sevk edilen 32 yaşında bir erkek olgu sunuldu. Torasik endovasküler stent greft tamiri, komplike akut tip B aort diseksiyonu başladıktan 72 saat sonra başarıyla uygulandı.

**Anahtar sözcükler:** Akut travma; aort; endovasküler stent.

of TEVAR on the degenerative changes in the aging aorta in young individuals.

Herein, we present a case who had an aortic injury due to falling from a height and in whom successful TEVAR was performed.

### CASE REPORT

A 32-year-old male patient was admitted to hospital with stable clinical condition 72 hours after falling from a height. The patient was initially transferred to the village state hospital and monitored with the medical treatment for three days. When the clinic status of the patient became worse, he was transferred to the university hospital. The patient was oriented and blood pressure was 130/80 mmHg on admission

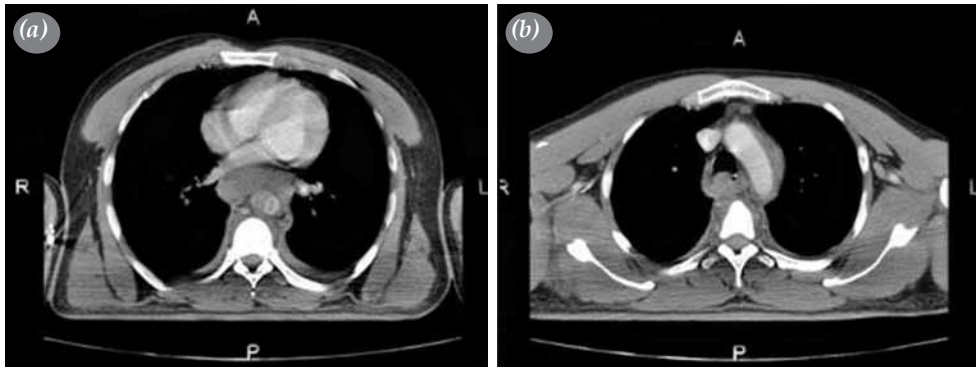


Available online at  
www.tgkdc.dergisi.org  
doi: 10.5606/tgkdc.dergisi.2016.12129  
QR (Quick Response) Code

Received: June 30, 2015 Accepted: August 11, 2015

Correspondence: Sedat Özcan, MD. Çanakkale Onsekiz Mart Üniversitesi Tıp Fakültesi, Kalp ve Damar Cerrahisi Anabilim Dalı, 17020 Çanakkale, Turkey.

Tel: +90 286 - 262 01 05 e-mail: sedatozcan78@hotmail.com

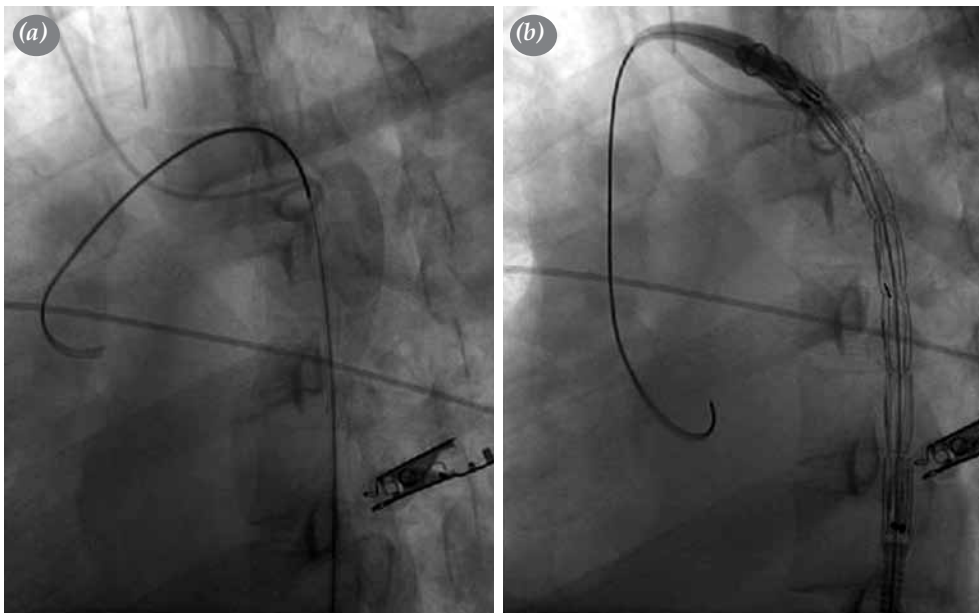


**Figure 1.** (a) A pre-procedural computed tomography image at the level of the arcus aorta showing a periaortic hematoma and (b) at the level of proximal segment of the descending aorta above the superior mesenteric artery showing an acute ruptured type B aortic dissection in which the false lumen was completely thrombosed in the thoracic aorta with a patent true lumen in the abdominal aorta.

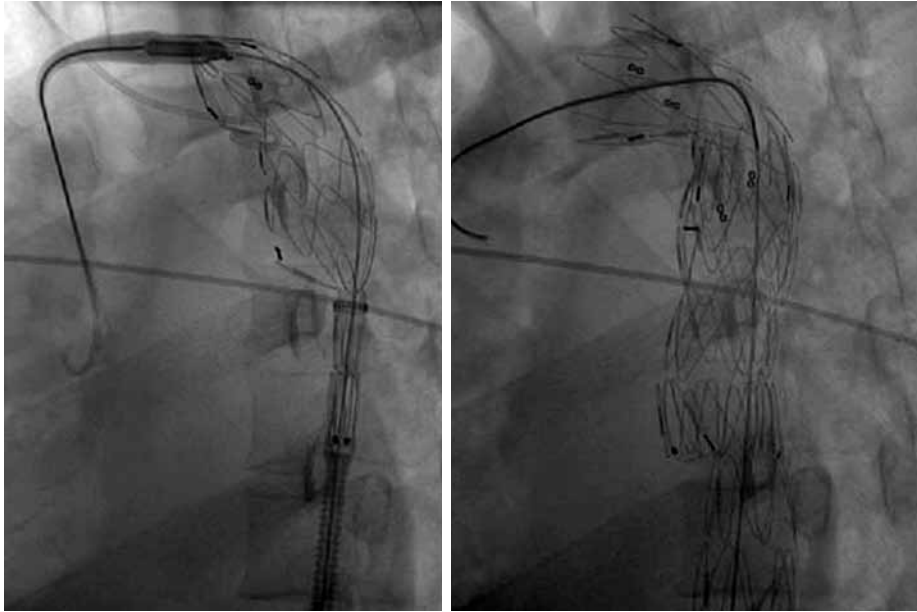
in the emergency service. Physical examination showed palpable femoral pulses. Thoracic computed tomography (CT) demonstrated acute type B aortic dissection in the descending thoracic aorta above the superior mesenteric artery. Dissection was limited only within a part of the thoracic descending aorta. In addition, he had a periaortic hematoma around the arcus aorta and had limited rupture where the dissection originated. The false lumen was totally thrombosed and seen only in the thoracic aorta and discontinued in the abdominal aorta. The true lumen was partially occluded by the false lumen in the thoracic aorta (Figure 1). General anesthesia was

used to maintain hemodynamic stability. He was already monitored with radial artery cannulation to check blood pressure and with internal jugular vein cannulation to give immediately intravenous fluids and blood products in the emergency setting. The right femoral artery was prepared for access. Unfortunately, the right brachial artery was chosen to insert the 5F sheath due to the previous injury to the left arm.

The operation was performed under general anesthesia in the cardiology angiography room. Before endovascular treatment, angiography was performed beyond the left subclavian artery (Figure 2). A 20 mm thoracic stent graft



**Figure 2.** (a) A pre-deployment aortogram showing acute type B aortic dissection. (b) Insertion of the stent graft into the descending thoracic aorta beyond the left subclavian artery.



**Figure 3.** Deployed stent graft in the descending thoracic aorta.

(Talent, Medtronic, Inc., Minneapolis, USA) was successfully deployed beyond the left subclavian artery in the true lumen (Figure 3). After deployment, angiography was performed to confirm the successful stenting and examine possibility of endoleaks. The patient was discharged on the fifth day after the procedure without any complication. Postoperative CT angiography at one month showed a successful procedure without endoleak.

## DISCUSSION

Although optimal surgical management of patients with acute type B aortic dissection remained controversial with respect to both techniques of intervention (i.e., open surgery or endovascular procedure) and the timing of surgical intervention, some authors advocated early operation irrespective of the presence or absence of complications.<sup>[4]</sup> Bortone et al.,<sup>[5]</sup> one of the defender of immediate intervention within two weeks of the initial diagnosis, reported that a stent-graft placement was successful in all the patients referred for intervention within the first two weeks among patients with acute type B aortic dissection. Chen et al.<sup>[6]</sup> reported that the technical success was 100% and the 30-mortality was 4.4% (1/23) in patients with acute type B aortic dissection undergoing TEVAR (23/62 patients) at presentation or within two week. This concept can be supported by the idea of the greater potential for stent-graft induced complete remodelling of the entire aorta in patients with acute aortic dissection.<sup>[7]</sup> On the other hand, some authors

suggest that initially fragile dissecting membrane changing to a more fibrotic and stable membrane in the chronic phase are critical for endovascular repair after a minimum period of four weeks after the onset of aortic dissection. This hypothesis was also confirmed by the improved survival rates following endovascular repair in a more stable clinical status in the chronic phase of aortic dissection.

Furthermore, there is no available data with respect to timing of endovascular treatment to date, due to the lack of prospective randomized studies comparing immediate or delayed intervention in patients with acute type B dissection undergoing TEVAR. In their study, Chou et al.<sup>[8]</sup> divided the patients into two groups: in group A, the patients with an emergent condition of shock and aortic rupture died of a new rupture two days postoperatively, while in group B, the patients defined with rupture died even after the stent graft was successfully deployed. Overall postoperative mortality was reported as high as 60% for the patients with aortic rupture in this study. In our clinical experience, immediate TEVAR should be reserved for complicated cases of acute descending aortic dissection.

On the other hand, there are similar controversies on surgical intervention: should it be preceded or followed by the treatment of associated traumatic lesions? Immediate surgery has a high mortality and morbidity up to 40%.<sup>[7]</sup> In some series, the intraoperative mortality and postoperative mortality were found to be 10.2% and 18.4% with major

postoperative morbidity, respectively.<sup>[9]</sup> Due to a very high risk for surgery, the previous concept of immediate surgery was replaced with a new concept of delayed surgery due to coexisting injuries. In the light of these data, we read the Bologna's strategy<sup>[10]</sup> in case of traumatic aortic ruptures with a great interest. Moreover, we have currently gained a better understanding of the timing of the repair in traumatic aortic ruptures.

In conclusion, we believe that thoracic endovascular treatment is an effective treatment modality even after the hours of the onset of complicated acute type B dissection and endovascular repair of the aortic injury in such cases is a reasonable first-line treatment option.

#### **Declaration of conflicting interests**

The authors declared no conflicts of interest with respect to the authorship and/or publication of this article.

#### **Funding**

The authors received no financial support for the research and/or authorship of this article.

#### **REFERENCES**

1. Hagan PG, Nienaber CA, Isselbacher EM, Bruckman D, Karavite DJ, Russman PL, et al. The International Registry of Acute Aortic Dissection (IRAD): new insights into an old disease. *JAMA* 2000;283:897-903.
2. Parsa CJ, Schroder JN, Daneshmand MA, McCann RL, Hughes GC. Midterm results for endovascular repair of complicated acute and chronic type B aortic dissection. *Ann Thorac Surg* 2010;89:97-102.
3. Steuer J, Björck M, Sonesson B, Resch T, Dias N, Hultgren R, et al. Editor's choice - durability of endovascular repair in blunt traumatic thoracic aortic injury: long-term outcome from four tertiary referral centers. *Eur J Vasc Endovasc Surg* 2015;50:460-5.
4. Şahin S, Parıldar M, Okbay AM, Bilgin ŞN, Çınar B, Tuygun AK, et al. Endovascular therapeutic approaches and short term results in traumatic vascular injuries. *Türk Gogus Kalp Dama* 2006;14:141-5.
5. Bortone AS, de Cillis E, d'Agostino D, Paradiso V, de Luca Tuppiti Schinosa L. Post-traumatic blunt rupture of the aorta: endo-aortic stenting therapy. *Multimed Man Cardiothorac Surg* 2007 Jan 1;2007(329):mmcts.2006.001966.
6. Chen CK, Liang IP, Chang HT, Chen WY, Chen IM, Wu MH, et al. Impact on outcomes by measuring tortuosity with reporting standards for thoracic endovascular aortic repair. *J Vasc Surg* 2014;60:937-44.
7. Ruan ZB, Zhu L, Chen GC, Yin YG. Early and long-term effect of thoracic endovascular aortic repair for Stanford B aortic dissection. *Thorac Cardiovasc Surg* 2015;63:120-5.
8. Chou HP, Chang HT, Chen CK, Shih CC, Sung SH, Chen TJ, et al. Outcome comparison between thoracic endovascular and open repair for type B aortic dissection: A population-based longitudinal study. *J Chin Med Assoc* 2015;78:241-8.
9. Dong Z, Fu W, Wang Y, Wang C, Yan Z, Guo D, et al. Stent graft-induced new entry after endovascular repair for Stanford type B aortic dissection. *J Vasc Surg* 2010;52:1450-7.
10. Freyrie A, Gargiulo M, Fargion A, Gallitto E, Pratesi C, Stella A. Anaconda™: the Italian Registry. Study protocol and preliminary perioperative results. *J Cardiovasc Surg (Torino)* 2011;52:629-35.