

Synchronous bilateral thoracoscopic lobectomy in a patient with bronchiectasis

Bronşektazili bir hastada senkron iki taraflı torakoskopik lobektomi

Kutsal Turhan, Ali Özdil, Yeliz Erol, Alpaslan Çakan, Ufuk Çağırıcı

Department of Thoracic Surgery, Medical Faculty of Ege University, İzmir, Turkey

ABSTRACT

Thoracoscopic lobectomy for focal bronchiectasis is a safe and effective surgical method. Operations for bilateral focal bronchiectasis are conventionally performed in two stages. In this article, we present a 19-year-old female patient with respiratory symptoms for 10 years which had not resolved despite several times of antibiotic therapy and who admitted to our clinic with the complaint of hemoptysis. Thorax computed tomography revealed right middle and left lower lobe bronchiectasis. Bilateral video-assisted thoracoscopic lobectomy was performed in one stage. The postoperative course was uneventful and the patient was discharged on postoperative day three. Now at the postoperative sixth month, patient is without any symptom and under our follow-up.

Keywords: Bilateral thoracoscopic lobectomy; bronchiectasis; hemoptysis.

Patients with bilateral focal bronchiectasis are candidates for surgical treatment if the patient has adequate cardiopulmonary functions and if all the diseased parts of the lungs can be resected safely.^[1] Despite several technical challenges when compared with a similar procedure for thoracic malignancy, video-assisted thoracoscopic (VATS) lobectomy for focal bronchiectasis is considered as a safe and effective method offering the advantages of a thoracoscopic procedure such as shorter hospital stay, better functional status, and less morbidity.^[1-4] The conventional surgical approach to a patient with bilateral focal bronchiectasis is a two-stage operation.^[5] In this report, we present a

ÖZ

Fokal bronşektazi için torakoskopik lobektomi güvenli ve etkili bir cerrahi yöntemdir. İki taraflı fokal bronşektaziler için ameliyatlar konvansiyonel olarak iki aşamada uygulanmaktadır. Bu yazıda, birkaç defa antibiyotik tedavisine rağmen 10 yıldır düzelmeyen respiratuar semptomları olan ve hemoptizi yakınması ile kliniğimize başvuran 19 yaşında bir kadın hasta sunuldu. Toraks bilgisayarlı tomografisinde sağ orta ve sol alt loblarda bronşektazi izlendi. Tek aşamada iki taraflı video yardımlı torakoskopik lobektomi uygulandı. Ameliyat sonrası dönem sorunsuzdu ve hasta ameliyat sonrası üçüncü gün taburcu edildi. Şu an ameliyat sonrası altıncı ayda hasta semptomsuzdur ve izlemimiz altındadır.

Anahtar sözcükler: İki taraflı torakoskopik lobektomi; bronşektazi; hemoptizi.

case with bilateral bronchiectasis of the right middle and left lower lobes. Both diseased lobes were resected simultaneously in one stage, both with VATS approach.

CASE REPORT

A 19-year-old female patient admitted to our clinic with complaints of 250 mL hemoptysis, right sided chest pain, and cough with expectoration. Her first respiratory symptoms appeared 10 years ago and presented as recurrent respiratory infections and recurrent episodes of hemoptysis. She was diagnosed as bilateral bronchiectasis and repeatedly treated with antibiotics. After her admission to our clinic,



Available online at
www.tgkdc.dergisi.org
doi: 10.5606/tgkdc.dergisi.2016.10837
QR (Quick Response) Code

Received: September 04, 2014 Accepted: February 04, 2015

Correspondence: Ali Özdil, MD, Ege Üniversitesi Tıp Fakültesi Göğüs Cerrahisi Anabilim Dalı, 35100 Bornova, İzmir, Turkey.

Tel: +90 232 - 390 46 80 e-mail: dr_aliozdil@yahoo.com

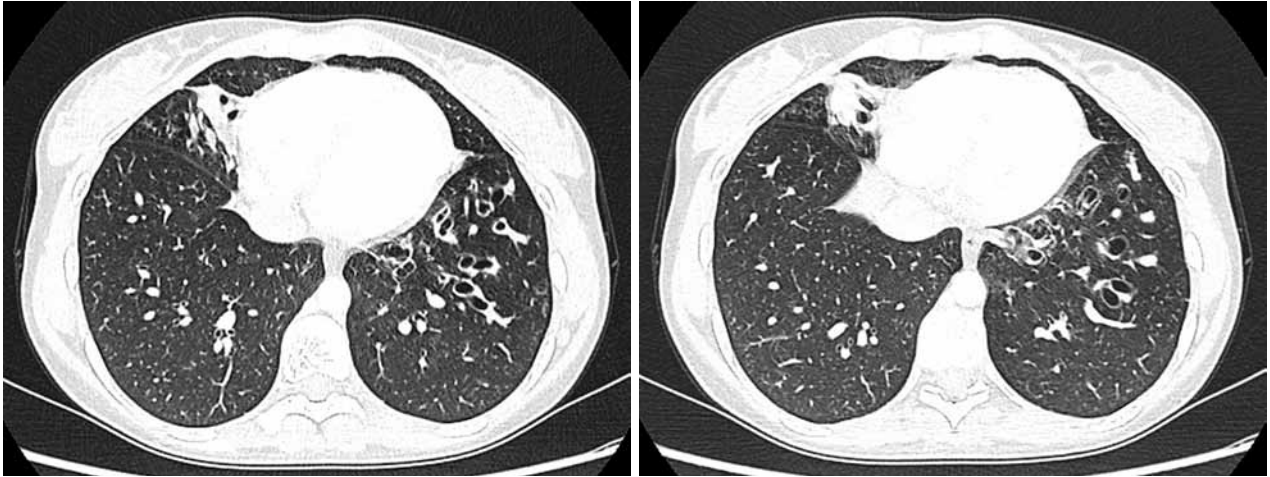


Figure 1. High resolution computed tomography image showing right middle lobe and left lower lobe bronchiectasis.

a high resolution computed tomography identified bronchiectasis on right middle and left lower lobes (Figure 1). Bronchoscopy was performed to locate the site of bleeding and to rule out benign or malignant causes of obstruction. On bronchoscopic examination, there was no active bleeding or any other pathologic finding, and the site of bleeding could not be identified. Because of major hemoptysis (250 mL) with unknown origin and bilateral disease, and considering her good cardiopulmonary functions and young age, we decided to perform bilateral VATS lobectomy simultaneously. After the induction of general anesthesia with a double lumen endotracheal tube, the patient was first placed in a full left lateral decubitus position. After performing the VATS right middle lobectomy, the patient was turned to a right lateral decubitus position, and VATS left lower lobectomy was performed. In both lobectomies, we used two 1 cm trocar sites and a 5 cm “utility” incision. There were dense adhesions on both sides, particularly involving the diseased lobes. These adhesions were divided with cautery and blunt dissection, taking care not to damage vital structures. No rib spreading was used and one chest tube for each side was placed. The total “skin to skin” operation time was 220 minutes. The postoperative course was uneventful and the right and left thorax drains were removed on first and second postoperative days, respectively. The patient was discharged on postoperative day three.

DISCUSSION

Bilateral bronchiectasis does not present a contraindication to surgical therapy in selected patients.^[1,5] Complete and anatomical resection should be conducted with preservation of as much lung function as possible to avoid cardiorespiratory

restriction. However, a minimum of two lobes or six pulmonary segments must be spared to ensure adequate pulmonary function.^[1,5] A staged open or thoracoscopic procedure is the conventional approach for patients with bilateral focal bronchiectasis.^[5]

To the best of our knowledge, this is the first presented synchronous single stage bilateral VATS lobectomy case for bronchiectasis in the English literature. We decided to perform a synchronous bilateral VATS lobectomy for the following reasons: The patient had bilateral focal and totally resectable bronchiectasis, she was young and had very good cardiopulmonary functions to tolerate a bilateral VATS approach, she suffered from recurrent hemoptysis for ten years and had a recent severe hemoptysis attack, the bleeding site could not be identified with bronchoscopy, and the right middle lobe and left lower lobes were similarly affected with bronchiectasis.

In conclusion, a simultaneous single stage bilateral video-assisted thoracoscopic lobectomy can be performed safely in selected patients with bilateral and totally resectable bronchiectasis. Thus, a second hospitalization and second operation might be prevented. Because all affected bronchiectatic segments are resected, bilateral video-assisted thoracoscopic lobectomy might be a one stage definitive therapy in patients with severe hemoptysis and avoid the possibility of persistent or recurrent hemoptysis after operation.

Declaration of conflicting interests

The authors declared no conflicts of interest with respect to the authorship and/or publication of this article.

Funding

The authors received no financial support for the research and/or authorship of this article.

REFERENCES

1. Fujimoto T, Hillejan L, Stamatis G. Current strategy for surgical management of bronchiectasis. *Ann Thorac Surg* 2001;72:1711-5.
2. Zhang P, Zhang F, Jiang S, Jiang G, Zhou X, Ding J, et al. Video-assisted thoracic surgery for bronchiectasis. *Ann Thorac Surg* 2011;91:239-43.
3. Mitchell JD, Yu JA, Bishop A, Weyant MJ, Pomerantz M. Thoracoscopic lobectomy and segmentectomy for infectious lung disease. *Ann Thorac Surg* 2012;93:1033-9.
4. Weber A, Stammberger U, Inci I, Schmid RA, Dutly A, Weder W. Thoracoscopic lobectomy for benign disease--a single centre study on 64 cases. *Eur J Cardiothorac Surg* 2001;20:443-8.
5. Al-Refaie RE, Amer S, El-Shabrawy M. Surgical treatment of bronchiectasis: a retrospective observational study of 138 patients. *J Thorac Dis* 2013;5:228-33.