

Can heart transplantation be postponed or avoided by pulmonary artery banding in an infant with dilated cardiomyopathy? First experience from Turkey

Dilate kardiyomyopatili bir süt çocuğunda pulmoner arter bandı ile kalp nakli geciktirilebilir veya önlenbilir mi? Türkiye'den ilk deneyim

Pelin Ayyıldız,¹ Erkut Öztürk,¹ Okan Yıldız,² İbrahim Cansaran Tanıdır,¹ Alper Güzeltaş,¹ Sertaç Haydin²

Departments of ¹Pediatric Cardiology, ²Pediatric Cardiovascular Surgery,
Mehmet Akif Ersoy Thoracic and Cardiovascular Surgery Training and Research Hospital, İstanbul, Turkey

ABSTRACT

Herein, a six-month-old infant with dilated cardiomyopathy with an unknown etiology was presented. Cardiac transplantation was indicated for the case with intractable cardiac failure despite medical treatment. Pulmonary artery banding is an old surgical technique which was used to restrict pulmonary artery blood flow in cases of complex ventricular shunts or in patients with a morphologic right ventricle in the systemic circulation who are candidates for an anatomic biventricular repair such as congenitally corrected transposition of great arteries. Due to the rarity of the donor number in Turkey and worldwide with a long waiting list, pulmonary artery banding was performed in our case. The heart failure symptoms regressed dramatically and she was discharged in a short period of time with improved clinical symptoms. The out-patient follow-up results biannually are normal.

Keywords: Dilated cardiomyopathy; infant; pulmonary artery banding.

Dilated cardiomyopathy is characterized by systolic-diastolic dysfunction and dilatation of ventricles. It is a major cause of cardiac failure in children. Also, it is a common diagnosis in patients undergoing cardiac transplantation.^[1,2] Left ventricle dilated cardiomyopathy (LVDCM) describes the dilatation of left ventricle with preserved right ventricular function.^[1,2]

Pulmonary artery banding (PAB) is a well-known surgical technique to reduce pulmonary

ÖZ

Bu yazıda etyolojisi bilinmeyen dilate kardiyomyopatili altı aylık bir süt çocuğu sunuldu. Medikal tedaviye rağmen kalp yetersizliği gerilemeyen olguda kalp nakli endikasyonu vardı. Pulmoner arter bantı, kompleks şanlı olgularda veya sistemik dolaşımda morfolojik sağ ventrikülü olan ve doğuştan düzeltilmiş büyük arterlerin transpozisyonu gibi anatomik biventrikül tamirine uygun olan adaylarda, pulmoner arterdeki kan akımını kısıtlamak için kullanılan eski bir cerrahi tekniktir. Türkiye'de ve dünyada donör sayısındaki azlık ile birlikte çok uzun bekleme süresi nedeniyle, olgumuza pulmoner arter bantı uygulandı. Kalp yetmezliği semptomları büyük ölçüde geriledi ve hasta klinik semptomlarda iyileşme ile kısa bir sürede taburcu edildi. Altı ayda bir yapılan poliklinik takiplerinde sonuçlar normaldi.

Anahtar sözcükler: Dilate kardiyomyopati; yenidoğan; pulmoner arter bandı.

circulation in congenital heart diseases. The role of PAB is to reduce pulmonary blood overflow to prevent or reverse cardiac failure and to provide long-term protection against irreversible pulmonary hypertension, as well as to maintain an optimal systemic output in cases of a large left-to-right shunt or univentricular heart defects. Recently, PAB operation has been increasingly used for the management of dilated cardiomyopathy.^[3] Its use for the treatment of idiopathic dilated cardiomyopathy was first described



Available online at
www.tgkdc.dergisi.org
doi: 10.5606/tgkdc.dergisi.2016.12119
QR (Quick Response) Code

Received: June 29, 2015 Accepted: October 19, 2015

Correspondence: Erkut Öztürk, MD. Mehmet Akif Ersoy Göğüs Kalp ve Damar Cerrahisi Eğitim ve Araştırma Hastanesi Pediatrik Kardiyoloji Kliniği, 34303 Küçükçekmece, İstanbul, Turkey.

Tel: +90 212 - 692 20 00 e-mail: erkut_ozturk@yahoo.com

by Schranz et al.^[4] in 2007. Herein, we report an infant with dilated cardiomyopathy whose systolic function improved following PAB.

CASE REPORT

A six-month-old girl with dilated cardiomyopathy referred to our clinic for further evaluation. Etiological screening for dilated cardiomyopathy did not reveal any disease. Her body weight and height were 6 kg (25th to 50th percentile) and 65 cm (50th to 75th percentile), respectively. Her heart rate was 164 bpm and there was a 2/6 systolic murmur over the left sternal border. Her blood pressure was 90/60 mmHg with a respiratory rate of 50 bpm. The liver was 5 cm palpable and oxygen saturation was 98% at room air. Electrocardiography (ECG) showed sinus tachycardia. The chest X-ray revealed cardiomegaly with a cardiothoracic index of 0.70. Echocardiography showed an extremely dilated, non-compacted left ventricle (LV) with normal coronary anatomy, a shortening fraction (SF) of 16%, left ventricle end-diastolic diameter (LVEDd) of 44 mm (z score: +7.8), left ventricle end-systolic diameter (LVESd) of 37 mm (z score: +8.3) along with moderate mitral regurgitation (MR) (Figure 1). Right ventricular (RV) function was normal. Therefore, she was diagnosed with LVDCM. Intravenous milrinone (0.5 µg/kg/min) and furosemide (2 mg/kg/day) were initiated. However, no change in the patient’s overall condition was observed. Then, all

therapy choices were explicitly provided to the family and the decision of PAB was made at the discretion of the parents. A written informed consent was obtained from the parents.

The patient was taken to the operation room with milrinone support. After intubation, femoral artery catheter and central venous catheter were placed. Cerebral perfusion monitorization with cerebral near infrared spectroscopy (NIRS) was performed during the operation. Transesophageal echocardiography (TEE) probe was placed. Thymus was displaced without resection after sternotomy. Pericardium was opened superiorly and hanged up with stay sutures. The main pulmonary artery (MPA) was, then, relieved from the peripheral tissues. A band of 3 mm in width and 0.4 mm in thickness was prepared from a serum pack. Pulmonary artery band tightened under the guidance of TEE evaluation during direct arterial, right atrial and right ventricular pressure monitorization and inotropic support was continued. The hematocrit was 40% and the heart rate was 138 bpm during the procedure. The band tightness was set to keep the ratio of RV/aorta pressure around 0.7. A 40 mmHg gradient was measured at the pulmonary artery. To provide a possible dilatation with balloon angioplasty in the future, the band was cut and put back together with 6-0 polypropylene intermittent sutures and also fixed with 6-0 polypropylene sutures to prevent migration. Interventricular septum was deviated slightly to the left and mitral regurgitation decreased, as soon as the band was applied (Figure 2). The patient was

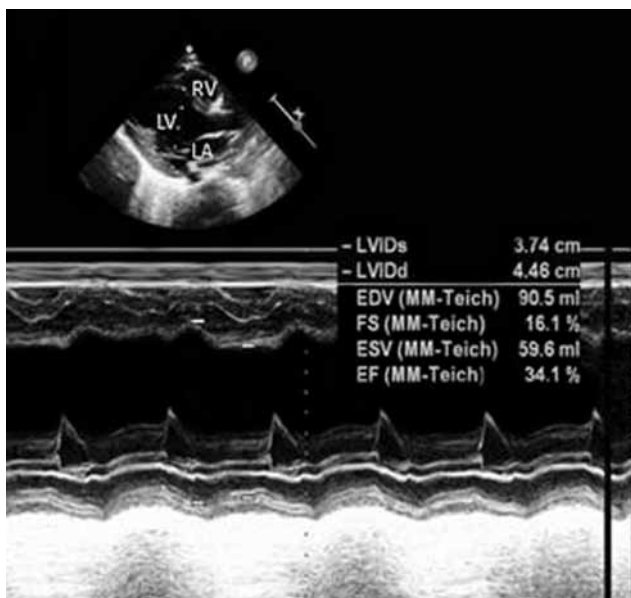


Figure 1. Preoperative transthoracic echocardiographic M-mode evaluation of the left ventricle.

RV: Right ventricle; LV: Left ventricle; LA: Left atrium; LVIDs: Left ventricular end systolic dimension; LVIDd: Left ventricular end diastolic dimension; FS: Short fraction; EF: Ejection fraction.

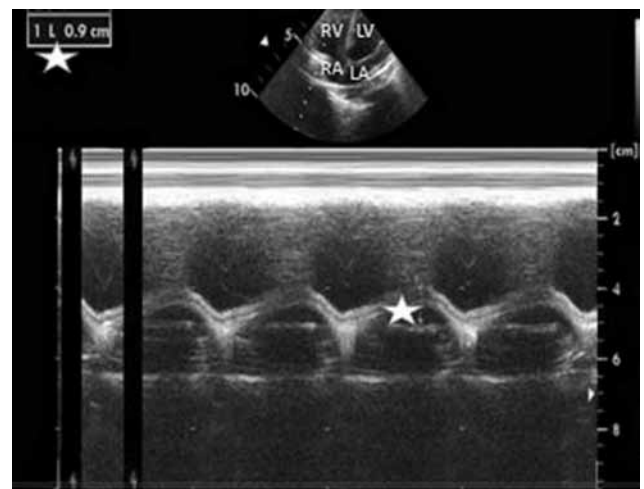


Figure 2. Postoperative transthoracic echocardiographic tricuspid annular plane systolic excursion measurement star sign showed tricuspid annular plane systolic excursion measurement.

RV: Right ventricle; LV: Left ventricle; RA: Right atrium; LA: Left atrium.

transferred to the intensive care unit with milrinone (0.5 µg/kg/minute) and adrenaline (0.05 µg/kg/minute) inotropic support.

She was mechanically ventilated for two days. The adrenalin infusion was ceased in the third postoperative day. She was discharged from the intensive care unit to the ward in the sixth postoperative day. Milrinone infusion was discontinued in the 10th postoperative day. The patient was discharged from the hospital in the 20th postoperative day. Interventricular septum was deviated towards left, septal movement was paradoxical, the LVEDd was 37 mm, and the LVESd 28 mm with a shortening fraction (SF) of 25%. Echocardiography showed mild mitral regurgitation and the gradient on band was 50 mmHg.

The baseline level of the brain natriuretic peptide of 4288 pg/mL decreased gradually to 80 pg/mL in the 20th postoperative day. Functional capacity according to the Ross classification improved from class 4 to 2 before discharge. She was discharged with the prescription of captopril, furosemide, and acetylsalicylic acid. The out-patient follow-up results biannually are normal.

DISCUSSION

Dilated cardiomyopathy is an important health problem, as it is one of the leading causes of cardiac failure and cardiac transplantation.^[1,2] Cardiac transplantation should be performed in patients with dilated cardiomyopathy who are unresponsive to the medical treatment; however, transplantation is limited in childhood both in our country and throughout the world.^[3] Therefore, many patients die due to congestive heart failure or arrhythmias, unless transplantation is performed.^[1-3]

According to the Freedom analysis, 72% of the patients with dilated cardiomyopathy die in the first year, where 68% need cardiac transplantation. These were 63% and 54%, respectively at five years;^[2] therefore, alternative treatment modalities are needed in children with dilated cardiomyopathy and intractable heart failure.

Pulmonary artery banding is an operation described 60 years ago to decrease pulmonary blood flow or to adjust the balance between systemic-pulmonary circulation in patients with complex ventricular shunts. The idea of PAB in dilated cardiomyopathy depends on the idea of preparation of the systemic ventricle for anatomic correction by remodeling with band application in front of the LV in infants with congenitally corrected transposition of great arteries (ccTGA).^[4] Functional improvement of the morphologic

RV, which is the systemic ventricle and decrease in tricuspid regurgitation were reported after PAB in ccTGA patients.^[5] Altogether, it was clinically shown that the shift of ventricular septum towards the left by PAB resulted in decreased LV end-diastolic volume and leftward shift of the LV Frank-Starling curve in selected cases. Also, there was increased LV ejection fraction by reverse remodeling in LV, reduced filling dynamics of LV, and end-diastolic pressure.^[4,5] In addition, ventricular electromechanical synchronization can be provided with cardiac re-synchronization treatment (CRT), if needed.

The normal structural and functional RV, LVEDd z score > + 4, LV EF < 30% despite medical therapy, patients younger than 3 years of age, and informed consent from the parents were stated as the indication for PAB. The mainstays of a successful PAB procedure include a preoperative hematocrit level of >40, right atrial pressure more than 5 mmHg but less than 15 mmHg, a heart rate of <150 bpm, tightening of the band with echocardiography guidance, the adjustment of band tightening according to the amount of deviation of septum towards left, reduced mitral regurgitation and a RV/aorta pressure ratio of 0.6-0.7, initiation of milrinone infusion preoperatively and continuation after the operation, initiation of adrenaline infusion immediately after band tightening and cessation in the third postoperative day, noradrenalin initiation in case of an unstable myocardial perfusion pressure [age-dependent, and systemic diastolic pressure-RA pressure (<30-35 mmHg)].^[3]

Schranz et al.^[3] performed PAB on 12 patients with LVDCM and reported that cardiac transplantation need might be delayed or even disappeared in some patients.

Besides, lisinopril, an angiotensin converting enzyme inhibitor (ACEI), and bisoprolol, a beta-blocker, in case of tachycardia can be used in the first-line treatment or digoxin can be used in the second-line treatment in patients with dilated cardiomyopathy after PAB. The loop diuretic furosemide can be also added to the treatment, if the patient suffers from pulmonary edema.^[6]

In our case, we followed the same strategy for PAB procedure. Captopril as an ACEI and digoxin for tachycardia were used after PAB. Mitral regurgitation, then, decreased and inotropes was able to be discontinued within the expected period. The patient was discharged, as it was planned. The next plan probably would be transcatheter balloon dilatation of the band, according to the clinic of the patient at the mid-term follow-up.

In conclusion, in infants with left ventricle dilated cardiomyopathy and preserved right ventricle function, pulmonary artery banding may result in improved left ventricle function by ventricular interaction. The need for cardiac transplantation may be postponed or cancelled. However, further large-scale studies are needed to prove the efficacy of pulmonary artery banding in dilated cardiomyopathy.

Declaration of conflicting interests

The authors declared no conflicts of interest with respect to the authorship and/or publication of this article.

Funding

The authors received no financial support for the research and/or authorship of this article.

REFERENCES

1. Towbin JA, Lowe AM, Colan SD, Sleeper LA, Orav EJ, Clunie S, et al. Incidence, causes, and outcomes of dilated cardiomyopathy in children. *JAMA* 2006;296:1867-76.
2. Alvarez JA, Orav EJ, Wilkinson JD, Fleming LE, Lee DJ, Sleeper LA, et al. Competing risks for death and cardiac transplantation in children with dilated cardiomyopathy: results from the pediatric cardiomyopathy registry. *Circulation* 2011;124:814-23.
3. Schranz D, Rupp S, Müller M, Schmidt D, Bauer A, Valeske K, et al. Pulmonary artery banding in infants and young children with left ventricular dilated cardiomyopathy: a novel therapeutic strategy before heart transplantation. *J Heart Lung Transplant* 2013;32:475-81.
4. Schranz D, Veldman A, Bartram U, Michel-Behnke I, Bauer J, Akintürk H. Pulmonary artery banding for idiopathic dilative cardiomyopathy: a novel therapeutic strategy using an old surgical procedure. *J Thorac Cardiovasc Surg* 2007;134:796-7.
5. Winlaw DS, McGuiirk SP, Balmer C, Langley SM, Griselli M, Stümper O, et al. Intention-to-treat analysis of pulmonary artery banding in conditions with a morphological right ventricle in the systemic circulation with a view to anatomic biventricular repair. *Circulation* 2005;111:405-11.
6. Recla S, Steinbrenner B, Schranz D. Medical therapy in dilated cardiomyopathy and pulmonary arterial banding in children. *J Heart Lung Transplant* 2013;32:1045-6.