

Migrating bullet from thorax to retroperitoneum

Torakstan retroperitona göç eden mermi

Mehmet Oğuzhan Özyurtkan,¹ Mustafa Necati Dağlı²

Institution where the research was done:
Medical Faculty of Fırat University, Elazığ, Turkey

Author Affiliations:

¹Department of Thoracic Surgery, Medical Faculty of İstanbul Bilim University, İstanbul, Turkey

²Department of Cardiology, Medical Faculty of Fırat University, Elazığ, Turkey

ABSTRACT

Bullet injuries to the thorax are observed frequently. When the radiographic location of the bullet does not correlate with the expected trajectory, a possible bullet embolism should be considered. In this article, we present a 39-year-old male patient who suffered a gunshot to his back. Patient's hemopneumothorax was treated with tube thoracostomy; however, the bullet was found to have migrated to the retroperitoneum without an overt mediastinal, diaphragmatic, or abdominal visceral organ injury. Angiography demonstrated no vascular embolism. The exact mechanism for the bullet to reach to the retroperitoneum was unknown, but a possible presence of a Bochdalek's triangle was suspected.

Keywords: Foreign body migration; penetrating injury; retroperitoneal space.

Bullet injuries to the chest are a frequent problem, but the majority can be managed nonoperatively. The bullet trajectory is important to speculate on possible organ injuries, and determine the treatment strategy. When the radiographic location of the bullet does not correlate with the expected trajectory, a possible migration to a distant part of the body must be considered.^[1] In this article, we report a bullet migration to the retroperitoneum in a patient who suffered a gunshot injury to his chest.

CASE REPORT

An alert and hemodynamically stable 39-year-old male patient presented with a gunshot to the back. Patient's

ÖZ

Toraksta kurşun yaralanmaları sık görülür. Kurşunun radyolojik konumu izlemesi beklenen yol ile uyuşmadığında, kurşun embolisi olasılığı dikkate alınmalıdır. Bu yazıda sırtından vurulan 39 yaşında bir erkek hasta sunuldu. Hastanın hemopnömotoraksı tüp torakostomi ile tedavi edildi, ancak kurşunun hiçbir belirgin mediyasten, diyafram veya batin iç organ hasarı yaratmadan retroperitona göç ettiği saptandı. Anjiyografide damarsal emboli görülmedi. Kurşunun retroperitona ne şekilde ulaştığı kesin olarak bilinmemekle birlikte, olası bir Bochdalek üçgeni varlığından şüphelenildi.

Anahtar sözcükler: Yabancı cisim göçü; penetran yaralanma; retroperitoneal boşluk.

vital signs were normal. He mentioned that he ran after the attacker for fifty meters, and then fell down since he became breathless. Physical examination revealed an entrance wound over the right scapula, and no exit wound was evident. The chest radiography was unremarkable, but a computed tomography (CT) of the chest with contrast demonstrated a right hemopneumothorax, a fractured right scapula and third rib, and a possible bullet trajectory at the right upper lobe (Figure 1). There was no sign or suspicion for a vascular, mediastinal, or diaphragmatic injury, but the bullet was not visible. The patient had chest tube which revealed a minimal air leak and a hemorrhagic drainage of less than 600 mL.



Available online at
www.tgkdc.dergisi.org
doi: 10.5606/tgkdc.dergisi.2016.11545
QR (Quick Response) Code

Received: January 27, 2015 Accepted: May 27, 2015

Correspondence: Mehmet Oğuzhan Özyurtkan, MD. İstanbul Bilim Üniversitesi Tıp Fakültesi, Göğüs Cerrahisi Anabilim Dalı, 34394 Şişli, İstanbul, Turkey.

Tel: +90 212 - 224 49 54 e-mail: moozyurtkan@hotmail.com

To detect the bullet, radiography of whole body was obtained. Since there was a bullet-like opacity in the pelvic radiography, an abdominopelvic CT with contrast was taken which demonstrated the bullet next to the bladder, close to the internal iliac vascular bundle (Figure 2). There was no evidence of diaphragmatic, or intraabdominal/pelvic organ injury, and no fluid or free-air in either abdomen or pelvis. Venography and arteriography revealed that the bullet was not located inside any vascular structure (Figure 3). Written informed consent was obtained from the patient.

Since the bullet did not cause any pain, motor function defect of leg, or infection, and there was no injury to the organs neighboring the bullet, no attempt was made to take it out. The recovery of the patient was uneventful. The chest tube was taken and the patient was discharged on the third day. However, the patient was lost to follow-up after a month.

DISCUSSION

Embolism is the migration of a solid, liquid, or gaseous substance from its point of origin to a distant site. First reported by Thomas Davis in 1834, bullet emboli are rare phenomena with an incidence of 0.3%.^[2] In case of penetrating injury, the bullet loses its kinetic energy

while travelling along its trajectory, and remains within the domains of the body cavity. An embolism occurs when a bullet penetrates the body, its movement is stalled, and then it is carried away from its initial site of lodgement to a distant location. The flow of blood, air pressure, or active or passive body movements may create an embolism.^[2]

In our case, we firstly considered a vascular embolism since the bullet was located nearby internal iliac vessels; however, arteriography and venography ruled out this possibility. It is unclear how the bullet reached the retroperitoneal space. Several theories may give a possible explanation for such a migration. First, the bullet may reach the retroperitoneum by directly penetrating the diaphragm. But the chest and abdominopelvic CT demonstrated no evidence of diaphragmatic, intraabdominal or pelvic injury. Another theory is based on a study which demonstrated that there existed several pathways between the mediastinum and the retroperitoneal space across the esophageal hiatus, and via the inferior vena caval hiatus.^[3] But the CT of the patient demonstrated neither mediastinal injury nor suspicion for the bullet to travel within the mediastinum. A final theory is based on a cadaver study which identified a diaphragm-free

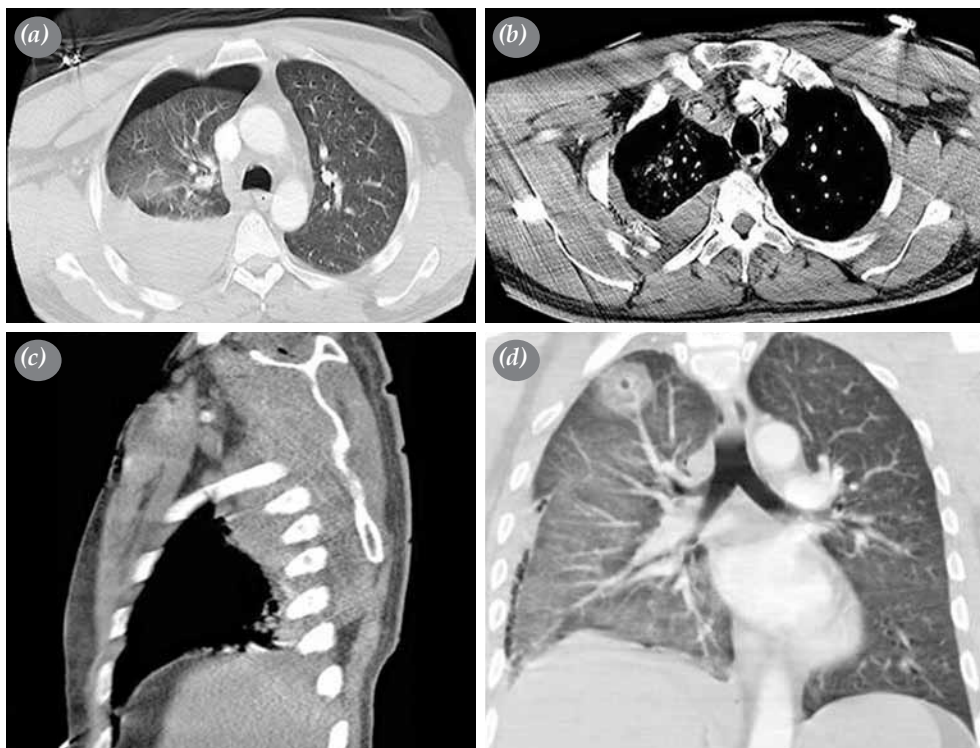


Figure 1. Computed tomography of chest. (a) Right hemopneumothorax, (b) fracture at third rib, (c) scapular fracture, (d) possible trajectory of bullet at upper lobe.

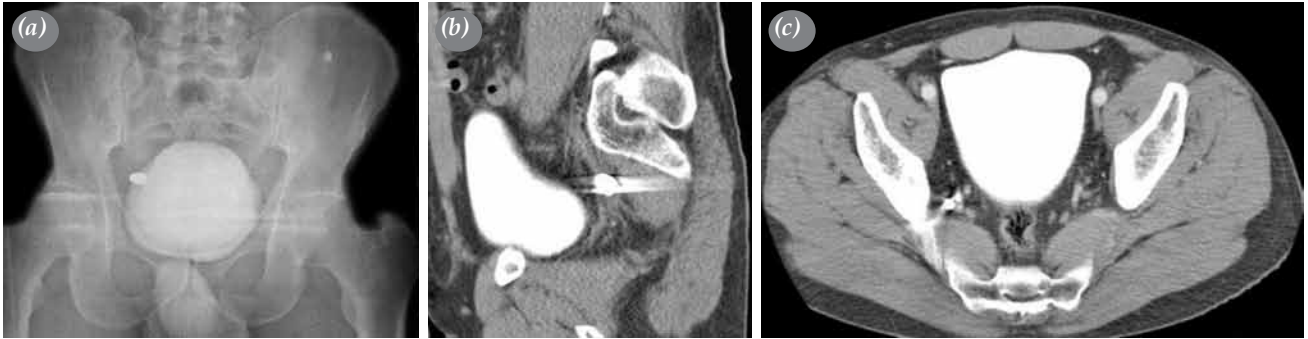


Figure 2. (a) Bullet-like opacity in pelvic radiography, (b, c) coronal and sagittal section of pelvic computed tomography demonstrating bullet close to internal iliac vascular bundle.

triangular area named Bochdalek's triangle in 90.1% of the cadavers, and proposed that this triangle comprising of 622.8 mm² may allow communication between the pleural cavity and the retroperitoneal space.^[4] Habal et al.^[5] reported a case in which a titanium rod, used for stabilization of fracture of the first lumbar vertebrae, migrated into the left pleural space. In the thoracoscopy, the authors found the rod lying in posterior costophrenic angle without any evidence of diaphragmatic injury. It is possible that the rod migrated using the pathway described above.^[4]

We think that the bullet migration to the retroperitoneum in our case may be explained by the third mechanism. Possibly, the scapula and third rib caused the bullet to lose its kinetic energy and slow down. Then, after penetrating the upper lobe, the bullet stayed in the right hemithorax, and then went deeper close to the diaphragmatic crura with the gravity effect. Finally, the physical effort the

patient made while running after the attacker pushed the bullet to the retroperitoneum via a possible Bochdalek's triangle.

There are controversies about bullet removal indications. Based on a systematic review conducted by Riehl et al.,^[6] in case of asymptomatic patients, it is common to accept bullets as inert harmless metallic bodies and avoid bullet removal. Meanwhile, an asymptomatic bullet should be followed for a while, because as reported by Yenigün et al.,^[7] a retained bullet in the lung may cause bronchiectasis even after more than 20 years. The bullet in our patient caused no vascular or intrapelvic/abdominal organ injury, no infection or pain, thus we did not attempt to remove it.

Bullet embolization after penetrating trauma is rare. If the number of entry wounds does not equal to that of exit wounds, or the clinical signs or symptoms and radiologic imaging do not correlate with the injury. For this reason, the possibility of

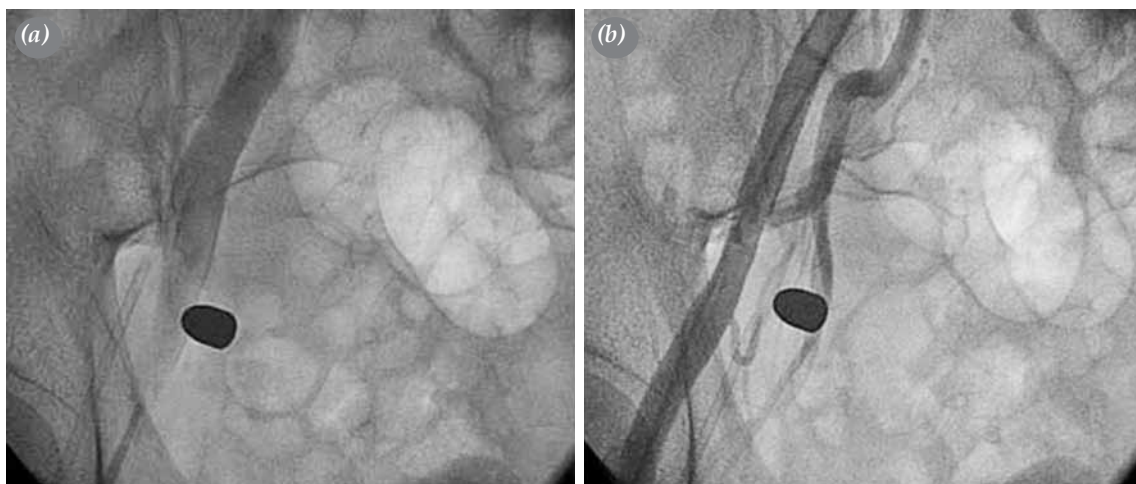


Figure 3. (a) Venography and (b) arteriography of right pelvic region demonstrating that bullet is close to, but not inside the internal iliac vessels.

bullet embolism should be considered. The removal of the bullet should be avoided in asymptomatic cases, in cases with no suspicion of visceral injury or infection, and if the bullet causes no pain or difficulty in body motion.

Declaration of conflicting interests

The authors declared no conflicts of interest with respect to the authorship and/or publication of this article.

Funding

The authors received no financial support for the research and/or authorship of this article.

REFERENCES

1. Biswas S, Price C, Abrol S. An elusive bullet in the gastrointestinal tract: a rare case of bullet embolism in the gastrointestinal tract and a review of relevant literature. *Case Rep Crit Care* 2014;2014:689539.
2. Krispin A, Zaitsev K, Hiss J. The elusive slug: bullet intestinal “embolism”. *Forensic Sci Med pathol* 2010;6:288-92.
3. Xu H, Zhang X, Christie A, Ebner L, Zhang S, Luo Z, et al. Anatomic pathways of peripancreatic fluid draining to mediastinum in recurrent acute pancreatitis: visible human project and CT study. *PLoS One* 2013;8:62025.
4. Kawada M, Murakami G, Yajima T, Sato TJ, Mizobuchi S, Sasaguri S. Potential foramen to allow communication between the pleural cavity and retroperitoneal space during laparoscopic surgery: a cadaver study of Bochdalek's triangle. *Surg Radiol Anat* 2007;29:105-13.
5. Habal P, Málek V, Novotný J. Case: unusual migration of osteosynthetic material. *Acta Medica (Hradec Kralove)* 2005;48:49-52.
6. Riehl JT, Sassoon A, Connolly K, Haidukewych GJ, Koval KJ. Retained bullet removal in civilian pelvis and extremity gunshot injuries: a systematic review. *Clin Orthop Relat Res* 2013;471:3956-60.
7. Yenigün BM, Şahin M, Enön S, Yılmaz AA, Güngör A. Bronchiectatic lung abscess caused by an endobronchial migrating bullet core. *Türk Gogus Kalp Dama* 2013;21:527-30.