

Bronchoscopic management of endobronchial lipoma: A case report

Endobronşiyal lipomun bronkoskopik tedavisi: Olgu sunumu

Ekrem Cengiz Seyhan,¹ Mehmet Akif Özgül,² Erdoğan Çetinkaya,² Zeki Günlüoğlu,¹
Güler Özgül,³ Gökhan Cebeci¹

Institution where the research was done:
Medical Faculty of Medipol University, İstanbul, Turkey

Author Affiliations:

¹Department of Chest Disease, Medical Faculty of Medipol University, İstanbul, Turkey

²Department of Chest Disease, Yedikule Chest Diseases and Thoracic Surgery, Training and Research Hospital, İstanbul, Turkey

³Department of Chest Disease, Bağcılar Training and Research Hospital, İstanbul, Turkey

ABSTRACT

Endobronchial lipomas are very rare tumors. Although surgery may be required in some cases, bronchoscopic removal is the preferred treatment modality. In this article, we present a case of endobronchial lipoma incidentally found after excision of a giant esophagus diverticulum. During follow-up of the patient, a tumor, located in the right lower lobe bronchus, was seen at thorax computed tomography. The tumor was excised via rigid bronchoscopy. This case highlights the effectiveness of rigid bronchoscopy in the management of endobronchial tumors.

Keywords: Bronchoscopic management; endobronchial lipoma; lung tumors.

Endobronchial lipomas (EL) account for only 0.1% to 0.5% of all benign tumors.^[1] They are thought to originate from the fatty tissue normally present in the bronchial wall. These tumors are characterized by a slow growth rate. The patients generally present with dry cough and wheezing. Some patients may present with infection symptoms due to obstructive pneumonia and subsequent irreversible lung damage secondary to bronchial obstruction.^[2] Computed tomography (CT) and magnetic resonance imaging (MRI) have emerged as useful non-invasive diagnostic tools especially in detection of fat contain of the tumor.^[3] Bronchoscopic resection can be diagnostic and also curative because

ÖZ

Endobronşiyal lipomlar çok nadir tümörlerdir. Bazı olgularda cerrahi gereksinimi olabilsede bronkoskopik çıkarma tercih edilen tedavi yöntemidir. Bu yazıda, dev bir özofagus divertikülünün eksizyonu sonrası tesadüfen saptanan bir endobronşiyal lipom olgusu sunuldu. Hastanın takibinde, toraks bilgisayarlı tomografide sağ alt lob bronşunda yerleşik bir tümör görüldü. Tümör, rijit bronkoskopi yoluyla eksize edildi. Bu olgu endobronşiyal tümörlerin tedavisinde rijit bronkoskopinin etkinliğini vurgulamaktadır.

Anahtar sözcükler: Bronkoskopik tedavi; endobronşiyal lipom; akciğer tümörleri.

of the benign nature of the tumor.^[4] In this article, we report a patient with endobronchial lipoma treated via bronchoscopy.

CASE REPORT

A 55-year-old male patient was admitted to our clinic with complaint of chest pain. He was a smoker (30 pack years) and diagnosed with chronic obstructive pulmonary disease 10 years ago. He had undergone operation four months ago and a giant esophageal diverticula had been resected via right thoracotomy (Figure 1). The patient was obese. In his physical examination, right posterolateral thoracotomy incision



Available online at
www.tgkdc.dergisi.org
doi: 10.5606/tgkdc.dergisi.2016.10199
QR (Quick Response) Code

Received: April 10, 2014 Accepted: March 10, 2015

Correspondence: Ekrem Cengiz Seyhan, MD, Medipol Üniversitesi Tıp Fakültesi
Göğüs Hastalıkları Anabilim Dalı, 34214 Bağcılar, İstanbul, Turkey.

Tel: +90 505 - 265 44 17 e-mail: drekremcs@yahoo.com

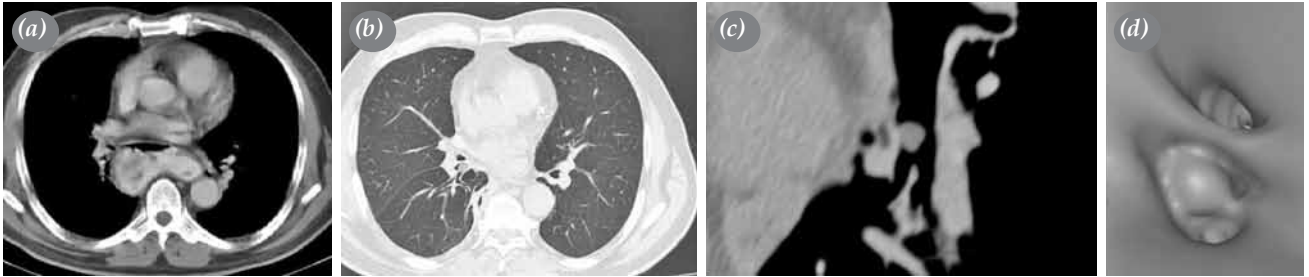

Figure 1. (a) Computed tomography section showing esophageal diverticulum hiding endobronchial mass. (b) After excision of diverticulum, a well-demarcated polypoid mass is seen in right pulmonary lower lobe bronchus, in axial images and (c) oblique coronal reformatted images and (d) virtual bronchoscopic images in thorax computed tomography.

scar was seen. Expiratory phase was prolonged. There were no pathological findings in examinations of other systems. Lung function test showed moderate airway obstruction. All the others laboratory values were within the normal ranges. A written informed consent was obtained from the patient.

There were no abnormal findings on the chest X-ray. Computed tomography of the thorax showed well-demarcated fat density (-100 to -120 HU) polypoid mass located in the entrance of right lung lower bronchus (Figure 1). Fiberoptic bronchoscopy (FOB) showed a polypoid, adipose, yellow mass with a smooth surface occluding the right lower lobe bronchus. The tumor was mobile during respiration (Figure 2). Histopathologic examination of the biopsy revealed non-specific inflammation. For final diagnosis, the patient underwent a rigid bronchoscopy. Using electrocautery snare, the polypoid lesion was enucleated. Then, argon plasma coagulation and

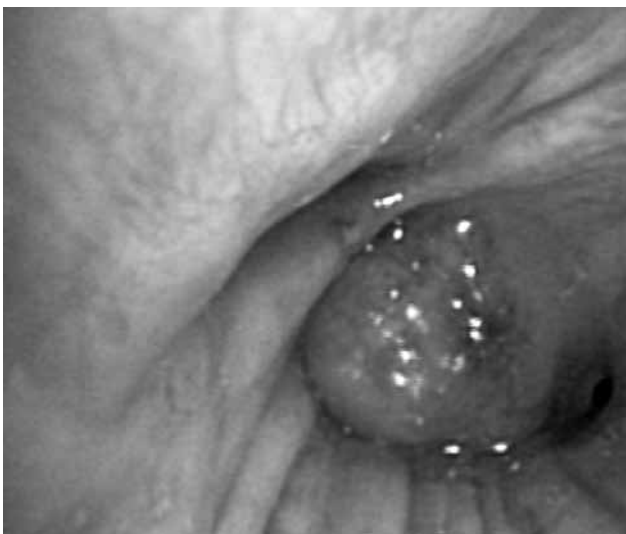

Figure 2. Fiberoptic bronchoscopy showed a well-circumscribed polypoid mass occluding right lower lobe bronchus.

cryotherapy were applied to remaining residual tissue. At the end of the procedure, lumen of the bronchus was fully opened. Histopathological examination revealed a well encapsulated tumor composed of lobules of mature adipose tissue without any cytological atypia, lined by respiratory epithelium with squamous metaplasia, confirming the diagnosis of endobronchial lipoma (Figure 3). Results of control bronchoscopy at sixth month were normal.

DISCUSSION

The incidence of EL among all pulmonary tumors is 0.1% and it constitutes 13% of all benign tumors of the lungs.^[5] Endobronchial lipomas occur more commonly in males in their fifth or sixth decades. Smoking and obesity are significant risk factors for EL in most reports.^[1] Our case was an obese, smoker male in his fifth decade similar to the literature. In our opinion, chronic inflammation of the bronchial mucosa may be another risk factor to develop an EL. In our case, chronic inflammation secondary to compression of the giant thoracic esophageal diverticulum might be the reason for the EL to originate in the lower lobe bronchus.

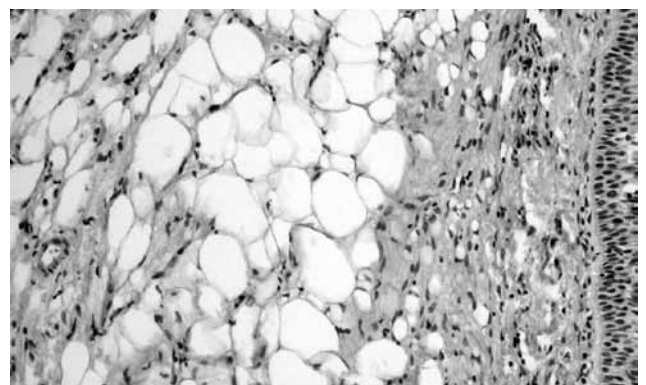


Figure 3. Mature fat cells are seen following mixed type cell infiltration in bronchus wall which is covered with pseudostratified respiratory epithelium (H-E x 100).

The symptoms may include coughing, wheezing and dyspnea secondary to bronchial obstruction, and purulent sputum and hemoptysis secondary to postobstructive pneumonia and bronchiectasis.^[2,5] In our case, chest pain was also present but we think that it was related to thoracotomy that the patient had undergone. Radiologic findings of EL are not specific. Chest X-ray is abnormal in 80% of cases; however, the findings are generally non-diagnostic.^[3,6] Computed tomography and MRI can show fat contain of the tumor.^[3] The CT findings of fat attenuation (-100 HU) of the tumor and absence of enhancement following contrast administration are usually diagnostic of lipoma.^[3] In our case, thorax CT has shown fat contain of the tumor.

Endoscopic examination of EL typically reveals a soft lesion with a smooth surface. They are mostly pedunculated, occasionally sessile and rarely dumbbell-shaped.^[7] In our case, the tumor was yellow and the surface was extremely smooth. Endobronchial lipomas are usually covered with normal bronchial mucosa. Foci of squamous metaplasia may be found. Biopsy with FOB has a low diagnostic yield in many benign tumors because of the intact bronchial mucosa. So, deeper tissue biopsy should be taken.^[4] Histologically, tumors are composed of mature adipocytes, with a stroma containing lymphocytes and histiocytes and lined by respiratory epithelium. In pathological examination of the tumor of our case, many mature fat cells besides mixed type inflammatory cell infiltration was seen, and diagnosis of EL was confirmed.

The treatment choices of EL include bronchoscopic excision, bronchial resection, lobectomy or pneumonectomy.^[8] Currently, bronchoscopic resection has been proposed as the first line of management of EL as removal is both diagnostic and curative, and both flexible and rigid bronchoscopy have been used successfully.^[1,4] Treatment modalities include bronchoscopic removal techniques such as neodymium-doped yttrium aluminium garnet laser, or

snare electrocautery, cryotherapy, and argon plasma coagulation.^[1,4] In our case, we removed the lesions with bronchoscopic resection, using electrocautery and a polypectomy snare.

In conclusion, clinicians should be aware of this rare entity and that endobronchial lipoma may be treated endoscopically in early stages of noncomplicated cases thanks to its benign nature.

Declaration of conflicting interests

The authors declared no conflicts of interest with respect to the authorship and/or publication of this article.

Funding

The authors received no financial support for the research and/or authorship of this article.

REFERENCES

1. Muraoka M, Oka T, Akamine S, Nagayasu T, Iseki M, Suyama N, et al. Endobronchial lipoma: review of 64 cases reported in Japan. *Chest* 2003;123:293-6.
2. Akar E, Candan T, Mutlu N. Orta lob bronşunu tıkayan endobronşiyal lipom. *Türk Gogus Kalp Dama* 2014;22:665-7.
3. Rodríguez E, Pombo F, Gallego C, Otero I. Endobronchial lipoma. *Computed tomography and magnetic resonance. Chest* 1994;105:1628.
4. Madan K, Agarwal R, Bal A, Gupta D. Bronchoscopic management of a rare benign endobronchial tumor. *Rev Port Pneumol* 2012;18:251-4.
5. Huisman C, van Kralingen KW, Postmus PE, Sutedja TG. Endobronchial lipoma: a series of three cases and the role of electrocautery. *Respiration* 2000;67:689-92.
6. Basoglu A, Celik B, Akdag AO, Sengul AT. Endobronchial lipoma: a rare cause of bronchial occlusion. *Interact Cardiovasc Thorac Surg* 2004;3:263-4.
7. Iannicello CM, Shoenuit JP, Sharma GP, McGoey JS. Endobronchial lipoma: report of three cases. *Can J Surg* 1987;30:430-1.
8. Alazemi S, Majid A, Ruiz AI, Litmanovich D, Feller-Kopman D, Ernst A. An elderly woman with chronic dyspnea and endobronchial lesion. *Chest* 2010;137:460-6.