

## Aorto-right atrial communication after tricuspid annuloplasty

*Triküspid anuloplasti sonrası aort ve sağ atriyum arasındaki ilişki*

Kazım Başer,<sup>1</sup> Adnan Yalçinkaya,<sup>2</sup> Hatice Duygu Bas,<sup>3</sup> Saranapoom Klomjit,<sup>3</sup>  
Kerim Çağlı,<sup>2</sup> Kenneth Nugent<sup>3</sup>

*Institution where the research was done:*

Türkiye Yüksek İhtisas Training and Research Hospital, Ankara, Turkey

*Author Affiliations:*

Departments of <sup>1</sup>Cardiology, <sup>2</sup>Cardiovascular Surgery, Türkiye Yüksek İhtisas Training and Research Hospital, Ankara, Turkey

<sup>3</sup>Department of Internal Medicine, Texas Tech University Health Sciences Center at Lubbock, Lubbock, USA

### ABSTRACT

A 45-year-old male patient was admitted to our department for the management of a symptomatic atrial septal defect. A septal defect repair together with tricuspid annuloplasty was performed. After surgery, a continuous murmur was heard on auscultation. Transthoracic echocardiography showed an aorto-right atrial fistula below the annuloplasty suture. This is the first reported case of a fistula between the aorta and right atrium after tricuspid annuloplasty.

**Keywords:** Atrial fistula; atrial septal defect repair; tricuspid annuloplasty.

Atrial septal defect (ASD) is the most common congenital heart disease in adulthood after a bicuspid aortic valve. Patients with secundum atrial septal defect cannot be recognized, until when they present with dyspnea which may appear in the late adulthood. Symptoms or echocardiographic signs of the right ventricular volume overload in the atrial septal defect are specific indications for intervention with either surgery or percutaneous closure.<sup>[1]</sup> If feasible, percutaneous closure is recommended over surgery; however, surgery is preferred in case of a need for any additional repair.

Herein, we report a male case with secundum atrial septal defect and moderate tricuspid regurgitation, in whom an aorto-right atrial communication was detected on transthoracic echocardiography below the tricuspid annuloplasty suture following surgery.

### ÖZ

Kırk beş yaşında erkek hasta, semptomatik atriyal septal defekt tedavisi için kliniğimize başvurdu. Septal defekt tamiri ile birlikte triküspid anuloplasti uygulandı. Cerrahi sonrası oskültasyonda devam eden üfürüm duyuldu. Transtorasik ekokardiyografide anuloplasti dikişinin altında aort-sağ atriyum fistülü izlendi. Bu olgu, triküspid anuloplasti sonrası aort ve sağ atriyum arasında fistül bildirilen ilk olgudur.

**Anahtar sözcükler:** Atriyal fistül; atriyal septal defekt tamiri; triküspid anuloplasti.

### CASE REPORT

A 45-year-old man suffering from dyspnea for the past one year was admitted to our department for further evaluation. His medical history was unremarkable, except hypertension treated with perindopril/hydrochlorothiazide. On physical examination, he had fixed splitting of the second heart sound and a systolic murmur in the pulmonic valve area. Surface electrocardiogram (ECG) revealed sinus rhythm and incomplete right bundle branch block. Chest X-ray showed enlargement of the right atrium. On transthoracic echocardiography, a left to right shunt was observed through a secundum atrial septal defect. There was right atrial and right ventricular enlargement simultaneously and moderate tricuspid regurgitation. Systolic pulmonary arterial pressure was estimated 50 mmHg. Shunt fraction (Qp/Qs) was 2.2. The rims



Available online at  
www.tgkdc.dergisi.org  
doi: 10.5606/tgkdc.dergisi.2016.12346  
QR (Quick Response) Code

Received: September 02, 2015 Accepted: November 30, 2015

Correspondence: Kazım Başer, MD. Türkiye Yüksek İhtisas Eğitim ve Araştırma Hastanesi Kardiyoloji Kliniği, 06230 Altındağ, Ankara, Turkey.

Tel: 00 173 454 686 29 e-mail: kazim.baser@ttuhsc.edu

were not adequate for percutaneous closure; therefore, the patient was scheduled for atrial septal defect repair together with tricuspid annuloplasty.

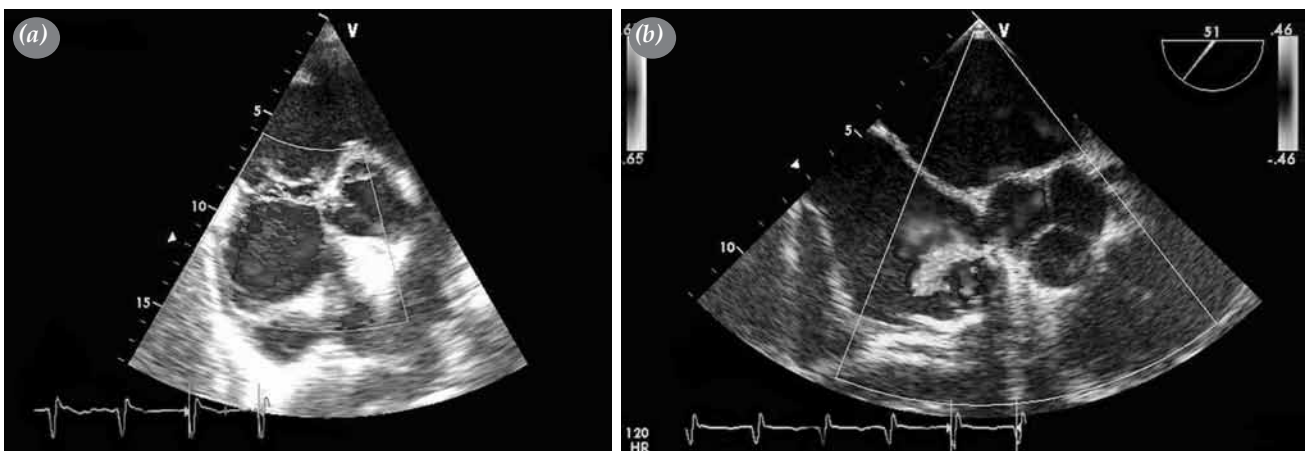
After standard anesthesia and median sternotomy, the patient was placed on cardiopulmonary bypass with an ascending aortic arterial cannula and two venous cannulas. A cross-clamp was introduced and cardioplegia was administered. The right atrium was explored and the ASD was repaired with a primary suture. A tricuspid annuloplasty was performed with a non-elastic strip of Teflon using double needle sutures. Sutures were started from the posteroseptal commissure towards the anteroseptal commissure with a Teflon strip of 5 cm in length. After hemodynamic stabilization, cannulas were removed and protamine was given. The patient had an uneventful postoperative period. Repeated echocardiography showed no residual defect on the interatrial septum and minimal regurgitation was observed in tricuspid valve. After the operation, his overall clinical status improved and he was scheduled for a follow-up visit. One month after the operation, the patient was asymptomatic; however, he had a continuous murmur over the lower left sternal area. On transthoracic echocardiography, a moderate pericardial effusion was noted; no defect was observed in the interatrial septum with color Doppler interrogation. From the apical four-chamber-view, a continuous flow was detected in the right atrium. From the parasternal short axis view, immediately below the tricuspid annuloplasty suture, color Doppler interrogation demonstrated that this continuous flow originated from the non-coronary sinus of the aorta to the right atrium (Figure 1a). There was no aortic regurgitation. Transesophageal

echocardiography confirmed an iatrogenic aorto-right atrial fistula (Figure 1b). The patient underwent surgery for fistula repair and the presence of aorto-right atrial communication was confirmed (Figure 2). The surgical diagnosis correlated with echocardiographic diagnosis. Communication with the right atrium and the aorta occurred, when a suture was deeply threaded into the adjacent aortic wall during tricuspid annuloplasty. A postoperative transthoracic echocardiography showed no residual fistula.

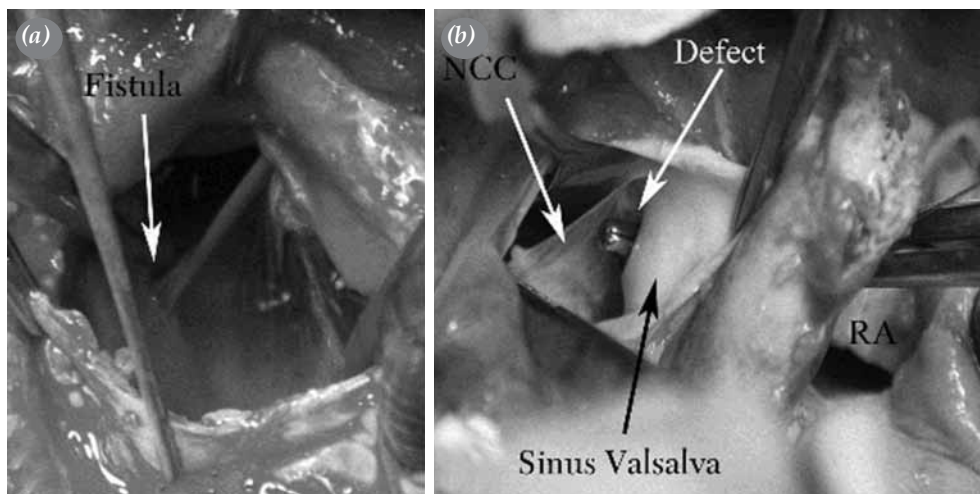
## DISCUSSION

Regardless of the symptoms, if the shunt is significant, ASD closure is recommended with a preference given to the closure devices, when applicable.<sup>[1]</sup> A secundum ASD which is not suitable for percutaneous closure requires surgical intervention.

Functional tricuspid regurgitation usually accompanies mitral valve disease. However, congenital heart disease may be also complicated by functional tricuspid regurgitation.<sup>[2]</sup> Historically, a conservative approach to functional tricuspid regurgitation is usually followed, since it is considered that secondary tricuspid regurgitation would diminish after corrective surgeries to other cardiac lesions. Some degree of functional tricuspid regurgitation accompanies ASDs due to volume overload to the right ventricle and the resultant right ventricular enlargement. In patients with an ASD, corrective surgery to the tricuspid valve with moderate to severe regurgitation in the presence of high pulmonary pressure may ameliorate postoperative persistent tricuspid regurgitation.<sup>[3]</sup> Currently, most surgeons prefer tricuspid repair at the



**Figure 1.** (a) Transthoracic echocardiography, parasternal short axis view, a high velocity jet showing from the aorta to the right atrium. (b) Transesophageal echocardiography confirming an iatrogenic aorto-right atrial fistula. The flow originating from the non-coronary cusp of aorta in this short axis view.



**Figure 2.** (a) An intraoperative image of the fistula between aorta and right atrium. (b) The defect above the NCC.

NCC: Non-coronary cusp; RA: Right atrium.

time of corrective surgery to other cardiac lesions.<sup>[4]</sup> Of note, tricuspid valve repair in patients undergoing mitral valve surgery is a Class I indication according to the guidelines.<sup>[5,6]</sup>

Suture and ring annuloplasty are the two approaches used in functional tricuspid regurgitation surgery. The hallmark of surgical approach is to reduce the annulus size and to increase the coaptation zone. The mortality rate added with tricuspid annuloplasty to concomitant cardiac operations is negligible.<sup>[7]</sup> Reported tricuspid annuloplasty complications include limited durability of suture annuloplasty, an acquired Gerbode defect, ruptured DeVega annuloplasty, and right coronary artery ischemia or atrioventricular block.<sup>[8,9]</sup> Sutures are put in the anteroseptal commissure in each approach to stabilize the annular geometry with either a suture or ring annuloplasty.<sup>[7]</sup>

In our case, the atrial septal defect was repaired with a primary suture. Tricuspid regurgitation was repaired with a non-elastic strip of Teflon using double needle sutures. We believe that the formation of a fistula between the right atrium and the aorta was the result of a suture which was deeply threaded below the anteroseptal commissure of the tricuspid valve into the adjacent aorta, where the two anatomic landmarks are in close proximity. This type of complication may be encountered in the other surgical approaches currently used to repair tricuspid regurgitation. To the best of our knowledge, aorto-right atrial communication after tricuspid annuloplasty has not been reported in the literature and this is the first case of a fistula between

the aorta and right atrium after tricuspid annuloplasty reported.

In conclusion, surgeons should be alert to a continuous flow in the right atrium after tricuspid annuloplasty with the suspicion of an aorto-right atrial communication.

#### Declaration of conflicting interests

The authors declared no conflicts of interest with respect to the authorship and/or publication of this article.

#### Funding

The authors received no financial support for the research and/or authorship of this article.

#### REFERENCES

1. Baumgartner H, Bonhoeffer P, De Groot NM, de Haan F, Deanfield JE, Galie N, et al. ESC Guidelines for the management of grown-up congenital heart disease (new version 2010). *Eur Heart J* 2010;31:2915-57.
2. Song H, Kim MJ, Chung CH, Choo SJ, Song MG, Song JM, et al. Factors associated with development of late significant tricuspid regurgitation after successful left-sided valve surgery. *Heart* 2009;95:931-6.
3. Toyono M, Krasuski RA, Pettersson GB, Matsumura Y, Yamano T, Shiota T. Persistent tricuspid regurgitation and its predictor in adults after percutaneous and isolated surgical closure of secundum atrial septal defect. *Am J Cardiol* 2009;104:856-61.
4. Chikwe J, Anyanwu AC. Surgical strategies for functional tricuspid regurgitation. *Semin Thorac Cardiovasc Surg* 2010;22:90-6.
5. Bonow RO, Carabello BA, Kanu C, de Leon AC Jr, Faxon DP, Freed MD, et al. ACC/AHA 2006 guidelines for the

- management of patients with valvular heart disease: a report of the American College of Cardiology/American Heart Association Task Force on Practice Guidelines (writing committee to revise the 1998 Guidelines for the Management of Patients With Valvular Heart Disease): developed in collaboration with the Society of Cardiovascular Anesthesiologists: endorsed by the Society for Cardiovascular Angiography and Interventions and the Society of Thoracic Surgeons. *Circulation* 2006;114:84-231.
6. Vahanian A, Baumgartner H, Bax J, Butchart E, Dion R, Filippatos G, et al. Guidelines on the management of valvular heart disease: The Task Force on the Management of Valvular Heart Disease of the European Society of Cardiology. *Eur Heart J* 2007;28:230-68.
  7. Chan V, Burwash IG, Lam BK, Auyeung T, Tran A, Mesana TG, et al. Clinical and echocardiographic impact of functional tricuspid regurgitation repair at the time of mitral valve replacement. *Ann Thorac Surg* 2009;88:1209-15.
  8. Dadkhah R, Friart A, Leclerc JL, Moreels M, Haberman D, Lienart F. Uncommon acquired Gerbode defect (left ventricular to right atrial communication) following a tricuspid annuloplasty without concomitant mitral surgery. *Eur J Echocardiogr* 2009;10:579-81.
  9. Barbetseas J, Pitsavos C, Aggeli C, Xynopoulos G, Toutouzas P. Clinical and echocardiographic features of a ruptured DeVega tricuspid annuloplasty. *J Clin Ultrasound* 1998;26:46-8.