

A useful cannulation strategy to facilitate re-warming during total arch replacement

Total arkus replasmanında yeniden ısınmayı kolaylaştıran yararlı bir kanülasyon stratejisi

Ozan Onur Balkanay, Deniz Göksedef, Suat Nail Ömeroğlu, Gökhan İpek

Department of Cardiovascular Surgery, İstanbul University, Cerrahpaşa Medical Faculty, İstanbul, Turkey

ABSTRACT

“Distal-first” surgical technique with antegrade cerebral perfusion and early re-warming is a secure and comfortable method for aortic arch replacement. By using this technique, we can minimize total circulatory arrest and hypothermic periods. Cerebral morbidities can be reduced by antegrade cerebral perfusion which is achieved via both axillary cannulation and balloon-catheters. Distal organ, cerebral, and renal morbidities can be minimized by early femoral arterial perfusion and early re-warming that is re-started immediately after distal anastomosis is performed.

Keywords: Anastomosis; aortic arch; circulatory arrest; deep hypothermia induced; surgery.

Total aortic arch replacement requires a hypothermic total-circulatory-arrest period. The outcomes of this procedure mostly related with a total length of circulatory arrest and hypothermic periods.^[1] Cerebral adverse effects are not infrequent after the aortic arch surgery.^[2] To avoid neurocognitive dysfunction, it is recommended to minimize the deep hypothermic arrest (particularly lower than 25 minutes) and total perfusion times.^[3] Selective antegrade cerebral perfusion is the preferred method to decrease these cerebral morbidities. We prefer to cannulate both axillary and femoral arteries, perform distal anastomosis at the first step, and early re-warming is achieved to minimize the hypothermic period. Distal malperfusion of cannulated extremity is another concern of the cardiovascular surgeon. In our practice, we cannulated both axillary and femoral arterial sides using separate grafts. These challenging points are major pitfalls of aortic arch surgery.^[4] Therefore, we combined these surgical steps

ÖZ

Antegrad serebral perfüzyon ve erken yeniden ısınma ile “önce distal” cerrahi tekniği, arkus aort replasmanı için güvenli ve konforlu bir yöntemdir. Bu tekniği kullanarak, total sirkulatuvar arrest ve hipotermik dönemler en aza indirgenebilir. Serebral morbiditeler, hem aksiller kanülasyon ile hem de balon kateterler aracılığıyla sağlanan antegrad serebral perfüzyon ile azaltılabilir. Distal organ, beyin ve böbrek morbiditeleri, distal anastomozun hemen sonrasında erken başlatılan femoral arter perfüzyonu ve erken yeniden ısınma ile en aza indirgenebilir.

Anahtar sözcükler: Anastomoz; aort arkı; sirkulatuvar arrest; indüklenmiş derin hipotermi; cerrahi.

in our clinical practice. Herein, we describe our surgical method of aortic arch replacement which achieved early re-warming as “distal-first” technique.

SURGICAL TECHNIQUE

Both right axillary and femoral arterial cannulation sites are prepared. Separate perfusion grafts are anastomosed and used for both right axillary and femoral artery cannulations (Figure 1a). Perfusion is initiated using both axillary and femoral arterial lines. We prefer this graft-using-cannulation technique because of advantage of supplying distal perfusions of cannulated side extremities. Hypothermia of 18 °C is achieved. During the hypothermic total-circulatory arrest, femoral arterial perfusion is paused, while antegrade cerebral perfusion (8-10 mL/kg/min) is achieved via both right axillary and two separate Pruitt® balloon catheters (LeMaitre Vascular, Inc., MA, USA) (Figure 1b). Left arm arterial pressure



Available online at
www.tgkdc.dergisi.org
doi: 10.5606/tgkdc.dergisi.2016.12073
QR (Quick Response) Code

Received: June 16, 2015 Accepted: October 22, 2016

Correspondence: Ozan Onur Balkanay, MD. İstanbul Üniversitesi Cerrahpaşa Tıp Fakültesi Kalp ve Damar Cerrahisi Kliniği. 34098 Cerrahpaşa, Fatih, İstanbul, Turkey.

Tel: +90 212 - 414 30 00 / 23129 e-mail: balkanay@doctor.com

above 40 mmHg (but not more than 70 mmHg) is the key for adequate cerebral perfusion pressure. Balloon catheters are pre-connected to the arterial line using connectors and are occluding proximal parts of left common carotid and left subclavian arteries. Diseased aortic arch is totally resected and distal part of main graft is anastomosed to distal aortic side during circulatory arrest (distal-first) (Figure 1b). After the

distal anastomosis is performed in approximately 15 minutes; cross-clamp is applied on the proximal side of the main graft and by femoral arterial perfusion is restarting, early re-warming period begins. During this period, a trifurcated graft is made by two end-to-side anastomoses. Two separate minor clamps are placed on both left carotid and left subclavian arteries after removing two antegrade perfusion Pruitt balloon

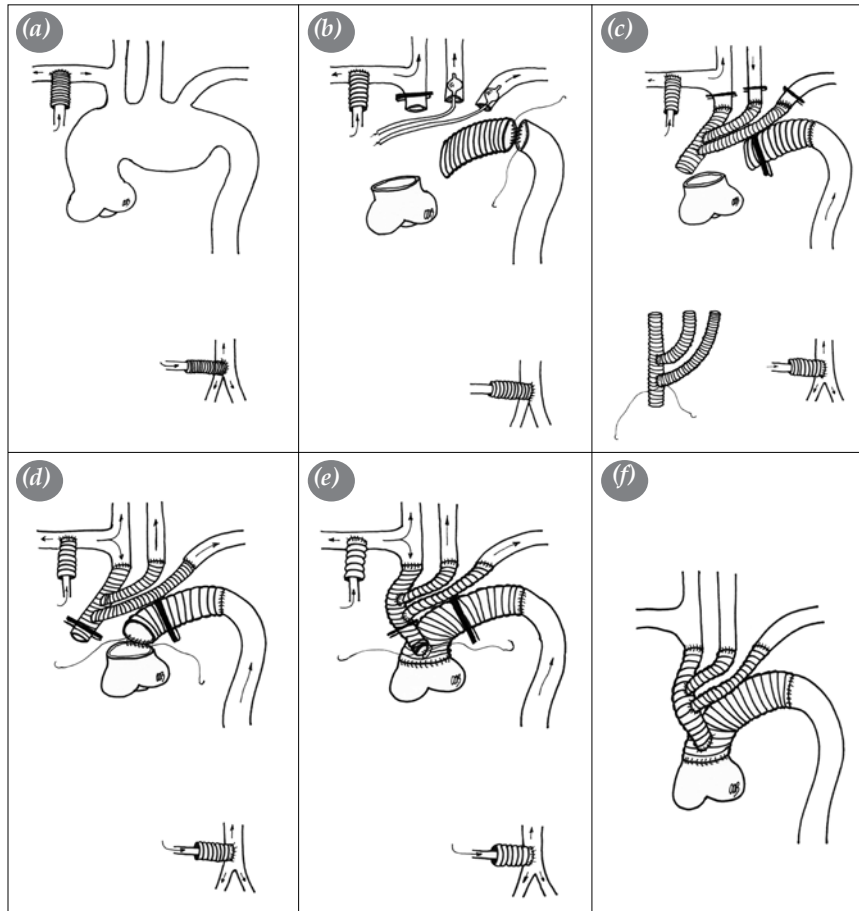


Figure 1. (a) Right axillary and femoral artery cannulations via using separate perfusion grafts. (b) Femoral arterial perfusion is paused. Antegrade cerebral perfusion is achieved via both right axillary and two separate balloon catheters placed in the left common carotid and left subclavian arteries. One separate minor clamp is put on the innominate artery. Hypothermic total-circulatory arrest is used during the resection of diseased aortic arch and distal anastomosis (Distal-first technique). (c) Cross-clamp is put on the proximal side of the main graft. Femoral arterial perfusion is re-started and warming period begins. A trifurcated graft is made by two end-to-side anastomoses. Total body circulation is supplied by femoral arterial perfusion. Cerebral and right upper extremity circulations are supplied by right axillary arterial perfusion. Balloon catheters are removed. Two separate minor clamps are placed on both left carotid and left subclavian arteries. Innominate, left carotid, and left subclavian arterial anastomoses are made by using self-made trifurcated graft. (d) Three separate minor clamps on innominate, left carotid and left subclavian arteries are removed. One separate clamp is placed on the proximal part of trifurcated graft. Proximal anastomosis of the main graft is performed. (e) Proximal part of trifurcated graft is end-to-side anastomosed on the main graft. (f) After completion of all anastomoses and de-airing, remaining clamps are removed.

catheters. The self-made trifurcated graft is end-to-side anastomosed to proximal parts of innominate, left common carotid, and left subclavian arteries. During this step, total body circulation is supplied by femoral arterial perfusion, while the cerebral and right upper extremity circulations are supplied by the right axillary arterial perfusion (Figure 1c). Three separate minor clamps on innominate, left carotid and left subclavian arteries are removed, and one separate clamp is placed on the proximal part of trifurcated graft. Proximal anastomosis of the main graft is performed (Figure 1d). Proximal part of trifurcated graft is end-to-side anastomosed on the main graft (Figure 1e). After completion of all anastomoses and de-airing process, remaining clamps are removed (Figure 1f). During the reconstruction of the arch vessels, re-warming of the patient continues, unless a major problem is detected by the surgeon.

DISCUSSION

Using a four-branched graft and “distal-first” technique has several advantages during total arch replacement eliminating the number of anastomosis and establishing distal body perfusion earlier.^[4] However, in our opinion, there are several drawbacks of using dedicated branched arch graft, such as inability of such grafts, unsuitable anatomy of the arch, and finally, any surgical decision, surgeon has to tailor a custom graft to fix the pathology for the arch disease. Our method describes a strategy for a custom made graft; however, it can be used with the branched arch grafts with three or four arms.

There are several methods to perform total arch replacement. One of them is to perform under hypothermic circulatory arrest. No specific method has been described as a gold standard to perform these cases. One of the major disadvantages of deep hypothermic arrest is the prolonged perfusion time.^[3] Nonetheless, distal-first surgical technique with

antegrade cerebral perfusion and early re-warming is a secure and comfortable method for total aortic arch replacement to handle with this disadvantage. By using our technique, lower perfusion times can be achieved. Cerebral morbidities can be minimized by antegrade cerebral perfusion that is achieved via both axillary cannulation and balloon-catheters. Distal organ, cerebral, and renal morbidities can be minimized by early femoral arterial perfusion and early re-warming which is re-started immediately after the distal anastomosis to achieve a shorter perfusion time. In addition, control of the possible bleeding from the distal anastomosis can be easily managed prior to implantation of the arch branches in very satisfactory circumstances, since the complex anatomy of the newly anastomosed arch vessels makes the distal anastomosis management almost impossible.

Declaration of conflicting interests

The authors declared no conflicts of interest with respect to the authorship and/or publication of this article.

Funding

The authors received no financial support for the research and/or authorship of this article.

REFERENCES

1. Preventza O, Garcia A, Cooley DA, Tuluca A, Simpson KH, Bakaeen FG, et al. Reoperations on the total aortic arch in 119 patients: short- and mid-term outcomes, focusing on composite adverse outcomes and survival analysis. *J Thorac Cardiovasc Surg* 2014;148:2967-72.
2. Emreçan B, Yılık L, Gürbüz A. Aortik ark tamirinde beyin korumasına güncel bir bakış. *Türk Gogus Kalp Dama* 2007;2:176-80.
3. Shiiya N. Aortic arch replacement for degenerative aneurysms: advances during the last decade. *Gen Thorac Cardiovasc Surg* 2013;61:191-6.
4. Kazui T, Washiyama N, Muhammad BAH, Terada H, Yamashita K, Takinami M, et al. Total arch replacement using aortic arch branched grafts with the aid of antegrade selective cerebral perfusion. *Ann Thorac Surg* 2000;70:3-9.