

## From diagnosis to treatment of persistent sciatic artery: a revised review of the literature

*Tanıdan tedaviye persistan siyatik arter: Güncellenmiş literatür taraması*

Kadir Çeviker,<sup>1</sup> Kerim Yetiş Baş,<sup>2</sup> Dinçer Uysal,<sup>1</sup> Hakan Demirtaş,<sup>3</sup> Turhan Yavuz<sup>1</sup>

Departments of <sup>1</sup>Cardiovascular Surgery, <sup>2</sup>Student, <sup>3</sup>Radiology,  
Medical Faculty of Süleyman Demirel University, Isparta, Turkey

### ABSTRACT

Persistent sciatic artery is a very rare congenital vascular malformation. Sciatic artery is the persistence of the axial artery in fetal life and connects the internal iliac arteries to the popliteotibial arteries. Femoral arterial hypoplasia causes the sciatic artery to persist and, therefore, becomes the dominant inflow to the lower extremity leading to the condition termed persistent sciatic artery. Persistent sciatic artery is a vascular structure which is prone to develop aneurysms and atherosclerotic stenosis. It is often characterized by aneurysm formation or thromboembolic complications causing lower extremity ischemia and neurological symptoms caused by compression of the aneurysm mass to the sciatic nerve. Angiography techniques can be used for the diagnosis and classification, while Doppler ultrasonography can be used for the diagnosis and follow-up. The decision on the treatment options depends on the overall condition of each patient, presenting symptoms, and classification of the disease. Endovascular interventions, which are the current treatment options, may be initially preferred with safe and effective results; however, careful follow-up is necessary.

**Keywords:** Classification; diagnosis; persistent sciatic artery; review; treatment.

Persistent sciatic artery (PSA) is a very rare congenital vascular malformation with an incidence of ranging between 0.025 to 0.04% based on angiographic and dissection study results.<sup>[1,2]</sup> Between 1964 and 2007, 159 PSAs in 122 patients have been reported in the literature and from 2007 up until now, 90 PSAs in 71 patients have been reported.<sup>[2]</sup>

### ÖZ

Persistan siyatik arter çok nadir görülen bir doğuştan damar malformasyonudur. Siyatik arter, fetal yaşamdaki aksiyal arterin devamıdır ve internal iliyak arterleri popliteotibial damarlara bağlar. Femoral arter hipoplazisi, siyatik arterin devamlılık göstermesine neden olur ve böylece alt ekstremitenin baskın damarı haline gelerek, persistan siyatik arter adı verilen duruma yol açar. Persistan siyatik arter, anevrizma ve aterosklerotik darlık gelişmesine meyilli bir damarsal yapıdır. Genellikle anevrizma oluşumu veya alt ekstremitte iskemisine veya anevrizma kitlesinin siyatik sinire basısı nedeni ile nörolojik semptomlara yol açan tromboembolik komplikasyonlar ile karakterizedir. Tanı ve sınıflama için anjiyografi teknikleri kullanılabilir. Tanı ve takip için Doppler ultrasonografi kullanılabilir. Tedavi seçimi kararı, her hastanın genel durumuna, eşlik eden semptomlara ve hastalığın sınıflandırmasına bağlıdır. Başlangıçta, güvenli ve etkili sonuçlar ile günümüzde tedavi seçeneği olan endovasküler girişimler tercih edilebilir; ancak, dikkatli takip gereklidir.

**Anahtar sözcükler:** Sınıflama; tanı; persistan siyatik arter; derleme; tedavi.

The sciatic artery is the persistence of the axial artery in embryological life and connects the internal iliac artery (IIA) to the popliteotibial arteries.<sup>[3]</sup> As early as the 6 mm embryo stage, the sciatic artery appears as a branch of the umbilical artery and essentially provides the blood supply to the lower extremity buds.<sup>[3]</sup> After the 22 mm embryo stage,



Available online at  
www.tgkdc.dergisi.org  
doi: 10.5606/tgkdc.dergisi.2016.11872  
QR (Quick Response) Code

Received: April 20, 2015 Accepted: June 18, 2015

Correspondence: Kadir Çeviker, MD. Süleyman Demirel Üniversitesi Tıp Fakültesi Kalp ve Damar Cerrahisi Anabilim Dalı, 32260 Isparta, Turkey.

Tel: +90 212 - 459 20 00 e-mail: drkadirce@yahoo.com

the axial artery regresses and generates the common and superficial femoral artery (SFA), which is the main blood supply of the lower extremity.<sup>[2,4,5]</sup> After the SFA descends to the knee level, it branches to the descending medial geniculate and superficial communicating arteries. The sciatic artery joins the superficial communicating artery just above the knee. In the third month of the embryonic development, the sciatic artery regresses completely and SFA continues to provide all the blood supply to the lower extremity. Meanwhile, the umbilical artery is converted to the IIA. While the majority of the sciatic artery is regressed, some parts are involved in the formation of other arteries (inferior and superior gluteal arteries, peroneal artery, popliteal artery).<sup>[2]</sup> If there is a failure in the development of the femoral vascular system, the axial artery may remain as the sciatic artery.<sup>[2,4,5]</sup>

Persistent sciatic artery is usually presented as tortuous and highly enlarged.<sup>[6]</sup> The internal iliac artery which provides blood to PSA may become larger than the external iliac artery (EIA). The anatomical routing of PSA is as follows: starting from the IIA, it passes through the greater sciatic foramen and continues adjacent to the sciatic nerve (it may be inside the sciatic nerve sheath in some patients). Persistent sciatic artery goes down under gluteus maximus muscle along the edge of the adductor magnus muscle and reaches the popliteal fossa at the distal portion of lower extremities and conjugates with the popliteal artery (PA).<sup>[4]</sup>

The first classification of PSA was made by Pillet et al.<sup>[7]</sup> and was updated by Gauffre et al.<sup>[8]</sup> (Figure 1). Accordingly, PSA can be classified as follows:

Type 1: Complete PSA and normal FA

Type 2: Complete PSA and incomplete FA (2a: SFA are available, but cannot reach the PA. 2b: All parts of the SFA are rudimentary)

Type 3: Incomplete PSA (it is developed only in the proximal region of lower extremities and FA is normally developed).

Type 4: Incomplete PSA is only developed in the distal region of lower extremities and FA is normally developed

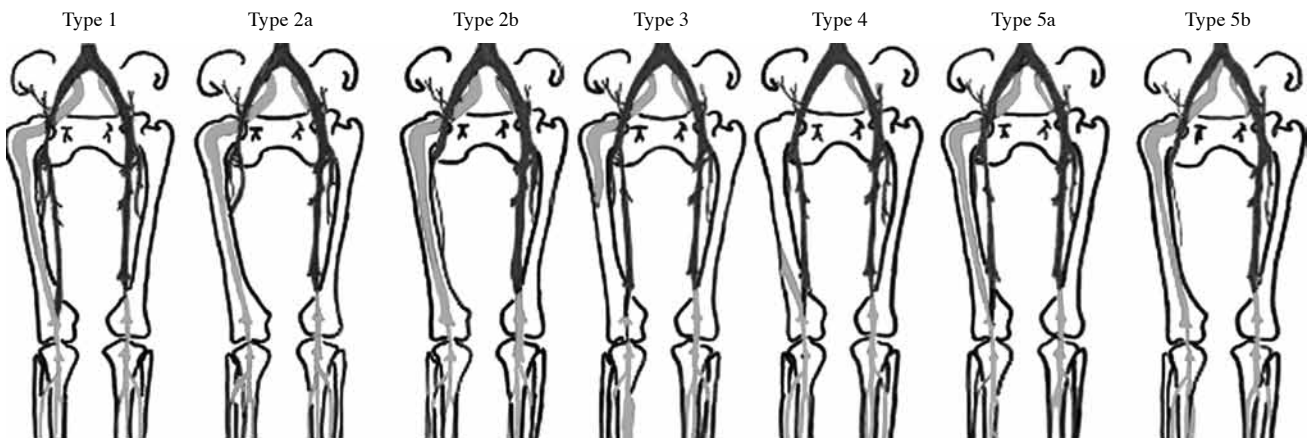
Type 5: PSA originates from the median sacral artery (5a: SFA is normally developed, 5b: SFA is rudimentary.)

Bower et al.<sup>[9]</sup> defined complete PSA as the artery which provides the main blood supply to the lower extremities. In this situation, SFA is usually hypoplastic and ends at the hip region. In incomplete PSA, SFA is the main artery that supplies to the lower extremities, whereas the sciatic artery is usually hypoplastic and ends at the hip.

**Clinical presentation**

Review of the literature revealed that the patients diagnosed with PSA were between 32 weeks and 84 years old.<sup>[2]</sup> The distribution of PSA among men and women was not statistically significantly different (i.e., not sex-dependent). The rate of unilateral PSA was reported to be 70% (the right or left PSA rates were similar) and bilateral PSA was reported to be 22 to 30%.

The incidence of PSA-specific symptoms was reported to be 80% in the literature.<sup>[2]</sup> The remaining 20%



**Figure 1.** The classification of persistent sciatic artery by Pillet et al.<sup>[12]</sup> (updated by Gauffre et al.<sup>[13]</sup>) (The gray color represents the persistent sciatic artery and the black represents the native superficial femoral artery in the femoral region. After the popliteal artery and its branches, only the gray color has been used).

of the patients in the literature were asymptomatic and PSA was detected incidentally during the examination for other illnesses.<sup>[2]</sup> Most of the patients with PSA were admitted to the hospital with single or double leg pain or a mass formation in the hip.<sup>[2]</sup> Around 46% of the patients with PSA had a mass formation and pain which increased in the hip in the sitting position.<sup>[9,10]</sup> Mandell et al.<sup>[10]</sup> reported that the patients with PSA had ischemic pain in the leg on the same side, as well as swelling and tenderness in the hip. Additionally, the neurological complaints, necrosis, and claudication may be as a consequence of the mass.<sup>[5]</sup> It was also reported that PSA in more than half of the patients was of slow-onset and chronic.<sup>[2]</sup> Arterial insufficiency in most patients was classified as Fontaine II and III.<sup>[2]</sup> The mass associated with arteries seen in trace of PSA and located in the gluteal region was usually painful and pulsatile.<sup>[4,9]</sup> The ischemic symptoms of the lower extremity may be due to the distal embolization or stenosis of PSA. Leg pain is reported in 31.3% of the patients and it is often related to thromboembolism which may arise from the aneurysm.<sup>[11]</sup> The emboli, which arise from an aneurysm or are associated with PSA has been reported in 20% patients, while the leg pain caused by an arterial stenosis was reported in 10% of patients.<sup>[2]</sup> Moreover, neurological symptoms such as radicular pain and drop foot may occur in patients with PSA, due to the location of PSA adjacent to the sciatic and L5-S1 radicular nerve.<sup>[12-14]</sup> In one case, the symptoms were found to be one-sided in a patient with bilateral PSA, specifically in the leg where the thrombosed aneurysm existed.<sup>[10]</sup> This case shows that PSA can be silent, until the development of complications such as aneurysm, thrombosis or embolism.<sup>[10]</sup> Persistent sciatic artery is an arterial vessel which is prone to develop atherosclerosis, aneurysms, vasculopathy, and tortuosity.<sup>[6,15,16]</sup> The reasons for the predisposition to the development of aneurysms may be the hypoplastic tissue of PSA, programmed to be degenerated during the progression and recurrent injuries in the region where PSA exists.<sup>[9,17,18]</sup> In addition, PSA is associated with aneurysm formation in 48% of patients in the literature.<sup>[2]</sup> The development of an aneurysmal segment may be the source of recurrent thromboembolism in the distal lower extremity;<sup>[19,20]</sup> moreover, the rupture of aneurysms has even been associated with the mortality.<sup>[10,21-23]</sup> Furthermore, a patient with complaints of hemihypertrophy was reported to be diagnosed with a rare combination of hemangioma associated with PSA in the literature.<sup>[10]</sup>

### Diagnosis

The Cowie sign, considered to be the pathognomonic sign for the diagnosis of PSA, is described as a palpating weak or absent pulse in the FA, while the

popliteal artery has a strong pulse.<sup>[24,25]</sup> Van Hooft et al.<sup>[2]</sup> reported that the Cowie sign was seen less than 5% of the patients. The diagnosis of PSA with conventional angiography [Digital subtraction angiography (DSA)] is shown to be most effective method.<sup>[26,27]</sup> Although DSA is successful in showing the anatomy and dynamic flow patterns of PSA, it may fail to display a completely occluded PSA.<sup>[28]</sup> In this case, computed tomography (CT), magnetic resonance imaging (MRI) or Doppler ultrasonography (USG), which enables cross-sectional imaging yield effective results.<sup>[26,27]</sup> Also, MRI and CT angiography imaging may help in the planning of the treatment, revealing the relationship between the structures around PSA. The images in the sagittal and coronal planes can be obtained with multi-planes reformatted from MRI and CT angiographic images. In addition, three-dimensional (3D) angiographic images can be obtained by the 3D volume rendering technique (Figure 2a, b). In general, the definite diagnosis is made by two or more diagnostic tools (Doppler USG + CT angiography, Doppler USG + MRI, DSA + Doppler USG, CT + Conventional angiography), as reported in the literature.<sup>[15,19,20,29]</sup>

The MRI two-dimensional (2D) time of flight (TOF) and 3D gadolinium-enhanced magnetic resonance angiography may also offer invaluable data in PSA patients with renal failure, in particular.<sup>[13]</sup> Also, 2D-TOF may provide diagnosis of false-positive stenosis or occlusion in areas with slow flow or turbulence.<sup>[13]</sup> On the other hand, the length of display time and the inability to detect retrograde flow and AV fistulas are the main limitations of these techniques.<sup>[13]</sup>

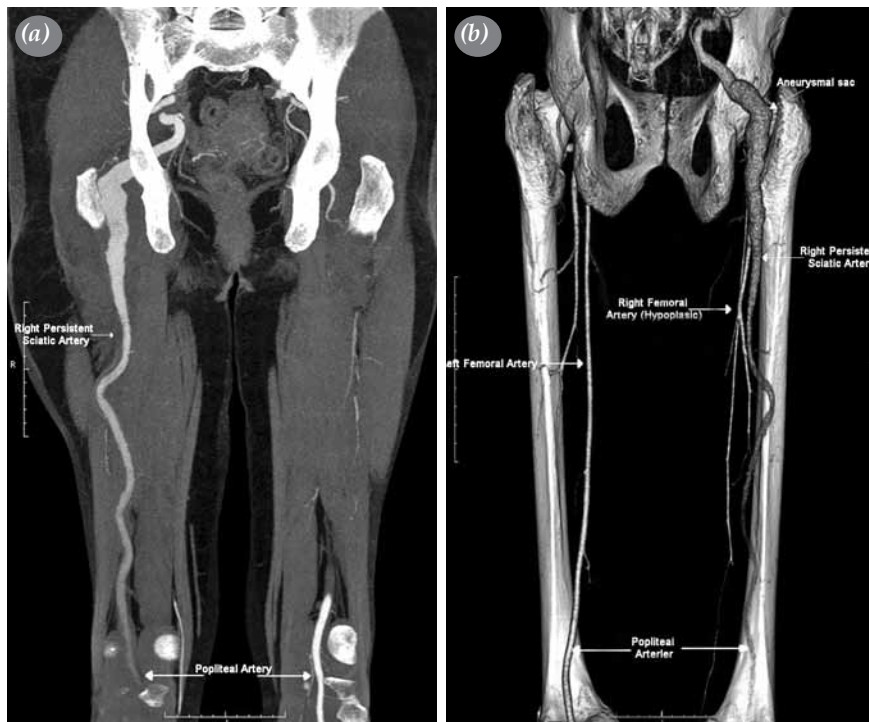### Treatment

The treatment protocol of PSA depends on symptoms, anatomy, the presence of occlusive vascular disease, aneurysms, and the type of PSA.<sup>[20,26]</sup> Published case reports indicate that the treatment is often guided by the specific complications of PSA.<sup>[21-27]</sup> The main goals of all therapeutic interventions are to resolve ischemia in the lower extremity and to prevent embolisms and aneurysmal ruptures. The cases without any additional pathology except PSA may left untreated and be followed by scheduled visits on a regular basis.<sup>[2]</sup> Ilio- or femoro-popliteal bypass and ligation of PSA has been performed independently in the absence of any symptoms, foreseeing a possible complication in certain patients.<sup>[2,11,25]</sup> Those patients with stenosis in PSA can be treated with angioplasty.<sup>[2,11]</sup> Also, bypass was performed in patients with total occlusion in PSA, while PSA was ligated in patients having a risk for distal embolization.<sup>[27]</sup> A chemical anticoagulant therapy may be appropriate to save distal

embolization in some patients with PSA.<sup>[17,23,26]</sup> as a conservative treatment.<sup>[23,26]</sup> Mechanical thrombectomy may be necessary in those patients who also have scheduled surgical vascular bypass procedures. In patients without a distal occlusion, treatment may be completed by performing a distal bypass after ligation of PSA associated with aneurysm.<sup>[27]</sup> On the other hand, endovascular therapy with wall-coated stents has been reported; however, long-term results are currently unknown.<sup>[28]</sup>

There are two widely adopted initiative techniques in patients for whom surgery for an aneurysm associated with PSA is planned: posterior or retroperitoneal approach. The posterior approach, which has a high success rate, entails an aneurysm resection and interposition of the graft by end-to-end or intraluminal aneurysmorrhaphy. In this approach, the aneurysm can be completely managed and a short bypass graft can be easily placed. Apart from these advantages, however, the high risk of sciatic nerve injury is substantially increased.<sup>[30]</sup> Using the retroperitoneal approach, the aneurysm can be easily ligated at the distal and the proximal ends and femorodistal bypass

can be performed in certain conditions. However, the aneurysm sac, due to the collateral vessels, has a risk which is present without a thrombosed painful mass.<sup>[30]</sup> The graft interposition, femoropopliteal or transobturator iliopopliteal bypass (ringed polytetrafluoroethylene grafts or reversed saphenous vein) are the most suitable options for selected patients in whom aneurysmectomy has been performed. Percutaneous techniques have been developed and diversified in the treatment of patients. Endovascular therapy is recommended as a priority in the first-line treatment of symptomatic femoropopliteal lesions.<sup>[16,31]</sup> The closure of the aneurysm on PSA with stent graft or embolization with coils and balloon angioplasty or stent application in patients with stenosis of PSA has been applied successfully in many patients to date.<sup>[32]</sup> One-year patency of wall-covered stents used for the treatment of femoral aneurysms is 100%, while it has been reported to be 69% for the popliteal artery. This ratio rises to 80% with nitinol-covered stents.<sup>[33]</sup> In patients undergoing angioplasty or stent procedure, contralateral femoral or retrograde approach from the same side of the popliteal artery can be applied.<sup>[16]</sup>



**Figure 2.** Magnetic resonance imaging (a) and computed tomography angiography (b) images of a 64-year-old woman presenting with right leg weakness, swelling, and pain in the upper right hip who was diagnosed with persistent sciatic artery in our clinic. Hypoplasia of the right femoral artery, right popliteal artery originating from the persistent sciatic artery, and aneurysmal segments behind the trochanter major of the femur are shown.

Data on the follow-up after treatment of patients with PSA in the literature is scarce. Van Hooft et al.<sup>[2]</sup> reported a success rate of 45 to 50% in the treatment of PSA patients during a follow-up of 12 months after treatment and the follow-up findings were asymptomatic. However, neurological complications such as drop foot may be irreversible and sciatic and radicular nerve pain may remain as chronic pain.<sup>[29,30]</sup> Asymptomatic PSA patients during follow-up should be made aware that they may be open to complications. In a report, one such asymptomatic patient died in the follow-up period due to massive bleeding from the sciatic artery, while another patient exhibited PSA thrombosis as a complication after an accident.<sup>[2]</sup> In another case, the fracture of the femur led to bleeding from PSA which was abandoned, but could have been stopped by embolization of the bleeding PSA.<sup>[34]</sup>

## DISCUSSION

Persistent sciatic artery is a rare anomaly with a high incidence of complications such as ischemia and vascular aneurysm.<sup>[2]</sup> The number of case reports published is limited to identify the monitoring and treatment strategies. Complications of PSA can be severe, leading to loss of limb, or even death. Van Hooft et al.<sup>[2]</sup> reported that 9% of PSA cases resulted in amputation.

Currently, a variety of diagnostic tests exist which are able to confirm the diagnosis of PSA. Of these, CT or MRI angiography are the most widely used diagnostic tools in the diagnosis of PSA. Computed tomography angiography which offers the visualization of the origin of PSA can also detect its relations with other vascular structures and enable accurate classification.<sup>[5]</sup> Both CT and MRI are able to display the relationship of PSA (or PSA-related aneurysms) with the surrounding tissue, such as the sciatic nerve. Surgeons should be careful due to the close proximity of PSA with the sciatic nerve and care should be taken in planning the incision during surgery.<sup>[5]</sup> In a study, Jung et al.<sup>[11]</sup> reported that CT angiography alone was sufficient for the diagnosis of PSA. In addition, CT angiography may show a completely occluded PSA which cannot be imaged by conventional angiography.<sup>[11]</sup> On the other hand, Doppler USG, which is a non-invasive diagnostic and follow-up tool, is relatively limited to provide data which can help in the treatment planning.<sup>[16]</sup>

Aneurysms are the most common complications of PSA with an incidence rate of 48%.<sup>[23]</sup> The reported incidences of stenosis and occlusion are 7% and 9%, respectively.<sup>[23]</sup> In general, aneurysms develop between the piriform muscle

and posterior margin of the trochanter major of the femur (Figure 2b).<sup>[34]</sup> Persistent sciatic artery-related complications usually increase after the formation of aneurysms.<sup>[29]</sup> Aneurysm-induced thrombosis, thromboembolism, radicular and sciatic nerve pain due to the compression of the aneurysm may also occur.<sup>[29,35]</sup>

The treatment of PSA essentially depends on the presenting symptoms of each patient. Close follow-up at intervals of three to six months by Duplex USG to preempt the development of complications should be ideally considered in asymptomatic patients.<sup>[33]</sup> Although there is a lack of proven data from evidence-based medicine, other strategies in asymptomatic patients include regular complete physical examination and ankle-brachial index measurement.<sup>[2,33]</sup>

In their study, Van Hooft et al.<sup>[2]</sup> concluded that no intervention was required for asymptomatic patients. Furthermore, in patients with a PSA-related aneurysm, the aneurysm can be closed from the distal end, if SFA provides sufficient circulation to the lower extremities.<sup>[10,31]</sup> This method is a valid option in an incomplete type PSA, in particular. If the SFA is hypoplastic, which has an incidence rate of 67 to 85%, the circulation to the lower extremity should be provided with femoropopliteal bypass.<sup>[30]</sup> Sciatic artery aneurysm resection and graft interposition are also invaluable techniques; however, the graft is compressed at the position where the patient sits; therefore, the patency of the graft may be compromised.<sup>[36]</sup> On the other hand, during the surgical removal of sciatic artery aneurysm, the sciatic nerve may be damaged due to its proximity to PSA. In such a case, it may be an optimal option to retain the side wall of the aneurysm adjacent to the sciatic nerve.<sup>[25]</sup> Despite increased risks for several complications, the results of an open surgical technique are quite satisfactory. Of note, it was reported that the graft was still patent in a patient who underwent in situ bypass graft 18 years ago.<sup>[37]</sup>

Today, technologically evolving invasive endovascular interventions with a wide range of applications have become important alternatives in patients with complicated PSA. Coil embolization, cover or repair of the aneurysm by a stent graft, and treatment of the stenosed sections with balloon and stent are methods which should be considered prior to opting for major vascular surgery. The repair of the aneurysmal wall of PSA with coated stents was first described by Gabelmann et al.<sup>[31]</sup> and has been used with success in many other patients since then. Shibutani et al.<sup>[32]</sup> also reported a 74-year-old female patient with

right leg ischemia symptoms and a diagnosis of total occlusion of PSA lumen by a 13-cm atherosclerotic lesion which was treated by a balloon and 7x120 mm stent. The authors further reported an aneurysm in PSA three months later in the same patient and the treatment was completed applying a 10x80 mm wall-coated stent. In another case report, Nuño-Escobar et al.<sup>[38]</sup> described the treatment of an aneurysm sac in PSA of a 53-year-old male patient with recurrent peripheral embolism applying a 10x50 mm coated stent. In addition, Yamamoto et al.<sup>[39]</sup> reported that endovascular treatment is effective and can be safely used. Wijeyaratne et al.<sup>[40]</sup> implemented a successful treatment of aneurysm of PSA with retrograde popliteal artery puncture with 6x150 mm wall-coated stents in a 55-year-old female patient and reported a four-year patency. Endovascular interventions for femoropopliteal arteries are applicable, particularly in high-risk patients with low risk and low complication rates.<sup>[41,42]</sup> However, only one case of endovascular aneurysm intervention which was associated with a negative outcome was reported by Girsowicz et al.<sup>[43]</sup> In this case, an 11x110 mm wall-coated stent was broken, leading to the complete occlusion of the aneurysm and distal segments of PSA. Girsowicz et al.<sup>[43]</sup> reported that the mechanical stress caused by the load and the motion in a region of the aneurysm caused the breakage of the stent, indicating an inadequacy of the stent itself.

In conclusion, persistent sciatic artery is a rare vascular anomaly which has a high risk of complications such as aneurysm, ischemia, and limb amputation. Treatment options depend on symptoms and classification of the persistent sciatic artery. The choice of treatment should be decided according to the status of each patient. Among the current treatment options, endovascular intervention, which is a safe first-line treatment with effective results, may be beneficial; however, it careful follow-up is necessary.

#### Declaration of conflicting interests

The authors declared no conflicts of interest with respect to the authorship and/or publication of this article.

#### Funding

The authors received no financial support for the research and/or authorship of this article.

## REFERENCES

- Jung AY, Lee W, Chung JW, Song SY, Kim SJ, Ha J, et al. Role of computed tomographic angiography in the detection and comprehensive evaluation of persistent sciatic artery. *J Vasc Surg* 2005;42:678-83.
- van Hooft IM, Zeebregts CJ, van Sterkenburg SM, de Vries WR, Reijnen MM. The persistent sciatic artery. *Eur J Vasc Endovasc Surg* 2009;37:585-91.
- Soner Albay, Yadigar Kastamoni, Esra Koyuncu. Embriyonal kalıntı arterler. *SDÜ Tıp Fak Derg* 2012;19:62-7.
- Brantley SK, Rigdon EE, Raju S. Persistent sciatic artery: embryology, pathology, and treatment. *J Vasc Surg* 1993;18:242-8.
- Osanai T, Tsuchiya T, Sugawara M. Persistent sciatic artery aneurysm associated with the development of angiosarcoma: a case report. *Arch Orthop Trauma Surg* 2008;128:937-40.
- Lin CW, Lee RC, Cheng HC, Soong TC, Ko JS, Teng MM. MR angiography of persistent sciatic artery. *J Vasc Interv Radiol* 1999;10:1119-21.
- Pillet J, Albaret P, Toulemonde JL, Cronier P, Raimbeau G, Chevalier JM. Ischio-popliteal artery trunk, persistence of the axial artery. *Bull Assoc Anat (Nancy)* 1980;64:97-110. [Abstract]
- Gauffre S, Lasjaunias P, Zerah M. Sciatic artery: a case, review of literature and attempt of systemization. *Surg Radiol Anat* 1994;16:105-9.
- Bower EB, Smullens SN, Parke WW. Clinical aspects of persistent sciatic artery: report of two cases and review of the literature. *Surgery* 1977;81:588-95.
- Mandell VS, Jaques PF, Delany DJ, Oberheu V. Persistent sciatic artery: clinical, embryologic, and angiographic features. *AJR Am J Roentgenol* 1985;144:245-9.
- Unosawa S, Ishii Y, Niino T. A persistent sciatic artery aneurysm containing a free-floating thrombus: report of a case. *Surg Today* 2015;45:1067-70.
- Mazet N, Soulier-Guerin K, Ruivard M, Garcier JM, Boyer L. Bilateral persistent sciatic artery aneurysm discovered by atypical sciatica: a case report. *Cardiovasc Intervent Radiol* 2006;29:1107-10.
- Shimono T, Nishimura K, Hayakawa K, Fukushima H, Matsuo H. Persistent sciatic artery: three-dimensional reconstructed CT (3D CT) image. *J Comput Assist Tomogr* 1995;19:669-71.
- Gasecki AP, Ebers GC, Vellet AD, Buchan A. Sciatic neuropathy associated with persistent sciatic artery. *Arch Neurol* 1992;49:967-8.
- Joffe N. Aneurysm of a persistent primitive sciatic artery. *Clin Radiol* 1964;15:286-90.
- Littler P, Blair SD, Lea S. Angioplasty via retrograde popliteal approach in a stenosed persistent sciatic artery. *Eur J Vasc Endovasc Surg* 2007;34:719-22.
- Wilson JS, Bowser AN, Miranda A, Johnson BL, Cannella X, Back MR, et al. Limb ischemia associated with persistent sciatic artery aneurysms—a report of 2 cases. *Vasc Endovascular Surg* 2005;39:97-101.
- Erturk SM, Tatli S. Persistent sciatic artery aneurysm. *J Vasc Interv Radiol* 2005;16:1407-8.
- Wu HY, Yang YJ, Lai CH, Roan JN, Luo CY, Kan CD. Bilateral persistent sciatic arteries complicated with acute left lower limb ischemia. *J Formos Med Assoc* 2007;106:1038-42.
- Hutchinson JE, Cordice JW Jr, McAllister FF. The surgical management of an aneurysm of a primitive persistent sciatic artery. *Ann Surg* 1968;167:277-81.

21. Ishida K, Imamaki M, Ishida A, Shimura H, Miyazaki M. A ruptured aneurysm in persistent sciatic artery: a case report. *J Vasc Surg* 2005;42:556-8.
22. Freeman MP, Tisnado J, Cho SR. Persistent sciatic artery. Report of three cases and literature review. *Br J Radiol* 1986;59:217-23.
23. Rezayat C, Sambol E, Goldstein L, Broderick SR, Karwowski JK, McKinsey JF, et al. Ruptured persistent sciatic artery aneurysm managed by endovascular embolization. *Ann Vasc Surg* 2010;24:115.
24. Brancaccio G, Falco E, Pera M, Celoria G, Stefanini T, Puccianti F. Symptomatic persistent sciatic artery. *J Am Coll Surg* 2004;198:158.
25. Ikezawa T, Naiki K, Moriura S, Ikeda S, Hirai M. Aneurysm of bilateral persistent sciatic arteries with ischemic complications: case report and review of the world literature. *J Vasc Surg* 1994;20:96-103.
26. Mayschak DT, Flye MW. Treatment of the persistent sciatic artery. *Ann Surg* 1984;199:69-74.
27. Samson RH, Showalter DP. Persistent sciatic artery as collateral for an occluded iliofemoral system. *J Vasc Surg* 2004;40:183.
28. Aschwanden M, Heidecker HG, Thalhammer C, Jaeger KA, Bilecen D. Acute Onset of Intermittent Claudication Caused by Complete Occlusion of a Persistent Sciatic Artery. *EJVES Extra* 2004;7:61-3.
29. Kim HJ, Cho YS, Lim H. Persistent sciatic artery with monoplegia in right lower leg without vascular complication symptoms in an obese woman. *J Emerg Med* 2008;34:291-4.
30. Yamaguchi M, Mii S, Kai T, Sakata H, Mori A. Intermittent claudication associated with persistent sciatic artery: report of two cases. *Surg Today* 1997;27:863-7.
31. Gabelmann A, Krämer SC, Wisianowski C, Tomczak R, Pamler R, Görlich J. Endovascular interventions on persistent sciatic arteries. *J Endovasc Ther* 2001;8:622-8.
32. Shibusaki S, Hayashi E, Obara H, Narimatsu Y, Sato H, Ono S, et al. Rapid development of aneurysmal formation after successful endovascular treatment of chronic total occlusion of a persistent sciatic artery. *Ann Vasc Surg* 2013;27:499.
33. Howell M, Krajcer Z, Diethrich EB, Motarjeme A, Bacharach M, Dolmatch B, et al. Waligraft endoprosthesis for the percutaneous treatment of femoral and popliteal artery aneurysms. *J Endovasc Ther* 2002;9:76-81.
34. Paraskevas G, Papaziogas B, Gigis J, Mylonas A, Gigis P. The persistence of the sciatic artery. *Folia Morphol (Warsz)* 2004;63:515-8.
35. Batchelor TJ, Vowden P. A persistent sciatic artery aneurysm with an associated internal iliac artery aneurysm. *Eur J Vasc Endovasc Surg* 2000;20:400-2.
36. Santaolalla V, Bernabe MH, Hipola Ulecia JM, De Loyola Agundez Gomez I, Hoyos YG, Otero FJ, et al. Persistent sciatic artery. *Ann Vasc Surg* 2010;24:691.
37. Drozd W, Urbanik A, Budzynski P. A case of bilateral persistent sciatic artery with unilateral aneurysm: an 18-year period of graft patency after excision of aneurysm. *Med Sci Moni* 2012;18:12-5.
38. Nuño-Escobar C, Pérez-Durán MA, Ramos-López R, Hernández Chávez G, Llamas-Macías F, Baltazar-Flores M, et al. Persistent sciatic artery aneurysm. *Ann Vasc Surg* 2013;27:1182.
39. Yamamoto H, Yamamoto F, Ishibashi K, Yamaura G, Shiroto K, Motokawa M, et al. Intermediate and long-term outcomes after treating symptomatic persistent sciatic artery using different techniques. *Ann Vasc Surg* 2011;25:837.
40. Wijeyaratne SM, Wijewardene N. Endovascular stenting of a persistent sciatic artery aneurysm via retrograde popliteal approach: a durable option. *Eur J Vasc Endovasc Surg* 2009;38:91-2.
41. Mousa A, Rapp Parker A, Emmett MK, AbuRahma A. Endovascular treatment of symptomatic persistent sciatic artery aneurysm: a case report and review of literature. *Vasc Endovascular Surg* 2010;44:312-4.
42. Uğur M, Alp İ, Arslan G, Şenay Ş, Selçuk İ, Selçuk A et al. Vasküler hastalıkların yönetiminde endovasküler ve hibrid uygulamalar: Kardiyovasküler cerrahi kliniği deneyimleri. *Türk Gogus Kalp Dama* 2012;20:230-42.
43. Girsowicz E, Georg Y, Lejay A, Ohana M, Delay C, Bouamaied N, et al. Midterm failure after endovascular treatment of a persistent sciatic artery aneurysm. *Ann Vasc Surg* 2014;28:1323.