

A rare internal jugular vein phlebectasia: Review of the literature

Nadir bir internal juguler ven flebektazisi: Literatür derlemesi

Hamit Serdar Başbuğ,¹ Hakan Göçer,¹ Yalçın Günerhan,¹ Ahmet Erdem,² Kanat Özışık¹

Departments of ¹Cardiovascular Surgery, ²Radiology, Medical Faculty of Kafkas University, Kars, Turkey

ABSTRACT

Internal jugular vein phlebectasia is a rare condition that presents with neck swelling. It can be either unilateral or bilateral, and becomes apparent with Valsalva. It is a congenital malformation and usually encountered in childhood. The term phlebectasia differs from aneurysm. While the former has a homogenous fusiform dilatation of the whole length of the vein, a localized ectasia is observed in the latter. Phlebectasia also differs from the varices due to the lack of tortuosity. It is usually asymptomatic and diagnosed incidentally. Although its etiology is unknown, it has become more detectable thanks to the availability of superior imaging techniques. In this article, we present an adult patient with unilateral left-sided internal jugular vein phlebectasia with radiological images. To our knowledge, there are only about 50 cases in the recent literature most of which are children.

Keywords: Aneurysm; internal jugular vein; phlebectasia.

Internal jugular vein (IJV) phlebectasia is a rare condition that presents with neck swelling. It is also known as the congenital venous cyst, essential venous dilatation or venous ectasia.^[1] This pathology refers to a congenital saccular or fusiform dilatation of the jugular vein that appears as a soft and compressible mass in the neck. It becomes visible on strain like crying, coughing and sneezing or may be triggered by the Valsalva maneuver.^[2] It is a congenital malformation and is usually encountered in childhood. Although it is often asymptomatic and diagnosed incidentally, it is often misdiagnosed as a laryngocele which is the most common cause of neck swelling that increases in size with Valsalva in children.^[3]

ÖZ

İnternal juguler ven flebektazisi boyunda şişlik ile baş gösteren nadir bir durumdur. Tek taraflı ya da iki taraflı olabilir ve Valsalva ile belirgin hale gelir. Doğuştan bir oluşum bozukluğudur ve genellikle çocukluk çağında karşılaşılr. Flebektazi tabiri anevrizmadan farklıdır. İlkinde veni boydan tutan homojen fuziform bir genişleme varken, ikincisinde lokalize bir ektazi görülür. Flebektazi ayrıca tortiyozitesi olmaması nedeniyle varislerden de farklıdır. Genellikle asemptomatiktir ve tanı tesadüfen konulur. Etyolojisi bilinmemekle beraber daha iyi görüntüleme tekniklerinin ortaya çıkmasıyla daha fazla tespit edilir hale gelmiştir. Bu yazıda, tek taraflı sol internal juguler ven flebektazisi olan erişkin bir hasta radyolojik görüntüler eşliğinde sunuldu. Bildiğimiz kadarıyla, yakın tarihli literatürde çoğunluğu çocuk olan sadece 50 kadar olgu vardır.

Anahtar sözcükler: Anevrizma; internal juguler ven; flebektazi.

In this article, we present an adult male patient with a unilateral left-sided IJV phlebectasia, which was detected incidentally during physical examination on outpatient clinic admission. This case demonstrates that this rare entity which is known as a childhood pathology may also be encountered in adults. Furthermore, to our knowledge, there are only about 50 cases of IJV phlebectasia in the recent literature most of which are children.^[4]

CASE REPORT

A 56-year-old male patient was admitted to the outpatient clinic with a complaint of neck swelling during strain. He had no previous history of any



Available online at
www.tgkdc.dergisi.org
doi: 10.5606/tgkdc.dergisi.2016.12800
QR (Quick Response) Code

Received: December 13, 2015 Accepted: February 08, 2016

Correspondence: Hamit Serdar Başbuğ, MD. Kafkas Üniversitesi Tıp Fakültesi Kalp ve Damar Cerrahisi Anabilim Dalı, 36040 Kars, Turkey.

Tel: +90 474 - 225 11 92 e-mail: s_basbug@hotmail.com

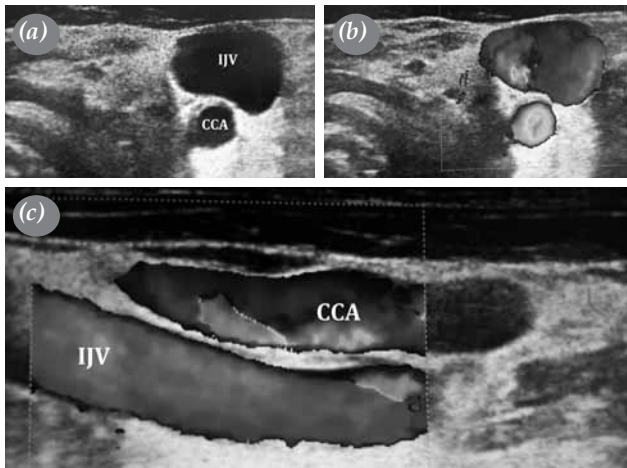


Figure 1. (a) Ultrasound image is showing internal jugular vein phlebectasia. (b) Color Doppler ultrasound is showing internal jugular vein phlebectasia. (c) Color Doppler ultrasound is showing common carotid artery and internal jugular vein alignments in longitudinal axis.

CCA: Common carotid artery; IJV: Internal jugular vein.

complaint, detected pathology or constituted diagnosis related to his symptoms. He also had no operation or prior prescription. Although he had been aware of his symptoms, he had neglected them until admittance. On inspection, there was no abnormality or asymmetry until he strained. A mass was visible as it bulged on the left side of his neck during Valsalva maneuver. On physical examination, the mass was not solid and could easily be compressed. An aneurysm-like pathology was suspected, and a color Doppler ultrasound (DUS) was performed. The DUS examination revealed an engorged left IJV, becoming more prominent

during Valsalva maneuver (Figures 1 and 2). A computed tomography (CT) angiography was performed to confirm the exact diagnosis. The CT angiography scans demonstrated a left IJV phlebectasia (Figure 3). Three-dimensional reconstruction of the CT angiography images revealed the anatomical relationships between vascular and the skeletal structures (Figure 4).

DISCUSSION

The term phlebectasia was initially described by Harris in 1928 and further delineated by Gerwig in 1952 as a saccular or fusiform dilatation of a vein.^[3,5] The term phlebectasia differs from an aneurysm that the former has a homogenous fusiform dilatation of the whole length of the vein rather than a localized ectasia seen in the latter.^[6] Phlebectasia also differs from the varices with the lack of tortuosity.^[1] Venous phlebectasia of the neck mostly occur in IJV, but some cases were reported in anterior jugular vein, external jugular vein, jugular bulb, and the posterior facial vein.^[3,7]

Internal jugular vein phlebectasia usually presents on the right side with a right to left ratio of 5.2:1.0.^[8] The IJV phlebectasia is seen more commonly on the right side because the vein valves are almost never observed in the right brachiocephalic vein.^[9] Also, LaMonte et al.^[2] hypothesized that phlebectasia mostly has a right-sided tendency because the right innominate vein lies in contact with the right apical pleura. Therefore, any increase in the intrathoracic pressure could be directly conducted to the right IJV.^[1] In our case, in contrary to the usual localization, phlebectasia was on the left side. Although the left IJV valves were clearly visible on the DUS scan (Figure 2), a functional

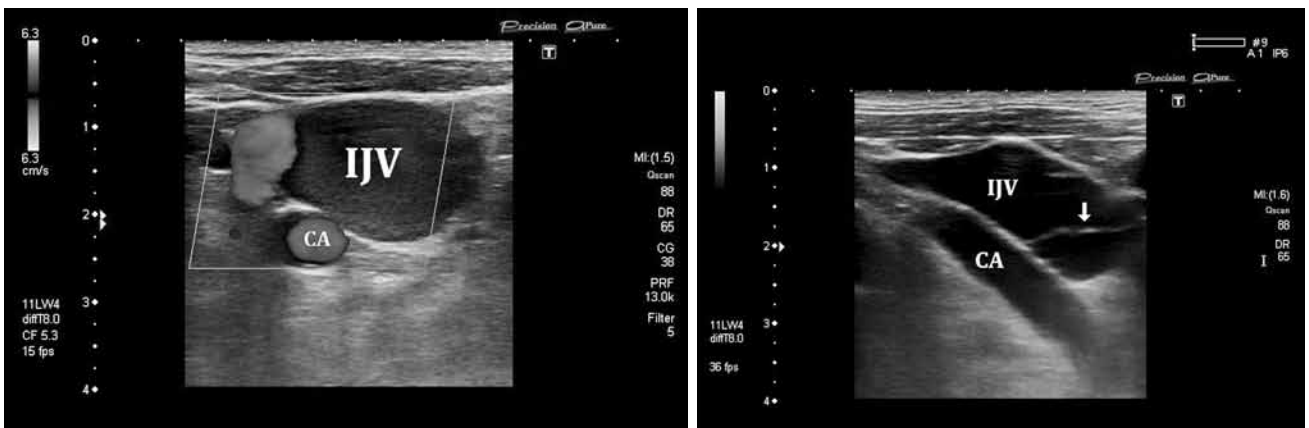


Figure 2. Transverse (upper) and longitudinal (bottom) color Doppler ultrasound images are showing internal jugular vein phlebectasia. Arrow at bottom image shows presence of vein valve at bulbous level.

CA: Carotid artery; IJV: Internal jugular vein.

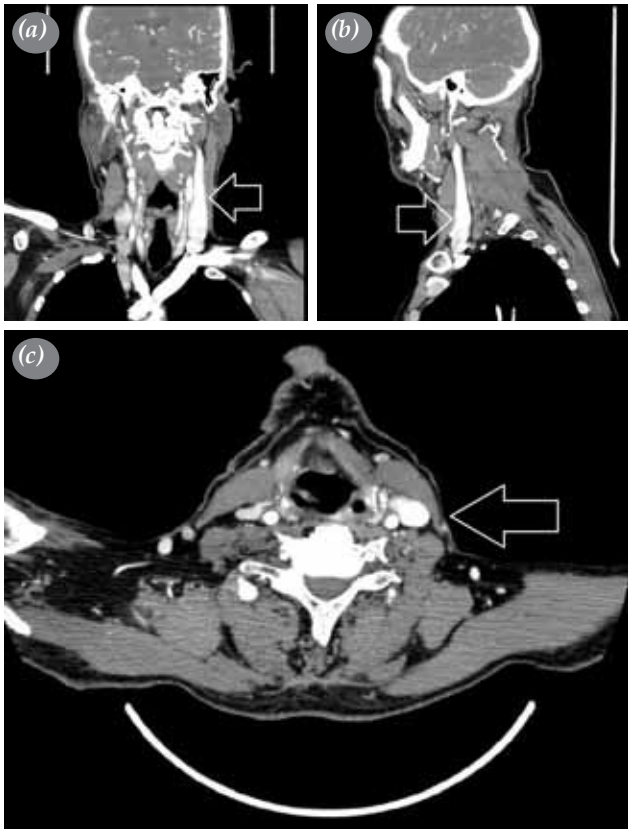

Figure 3. Computed tomography angiography images are revealing left internal jugular vein phlebectasia. (a) Coronal, (b) sagittal, and (c) transverse slices.

undetectable valvular deterioration or incompetence of the left IJV valves might be the reason for possible pathophysiology. In addition, agenesis of the left brachiocephalic vein might contribute to the etiology. Bilateral involvement of the IJV is rarely seen, and males are more often affected than females with a ratio of 1.4:1.0.^[10]

Internal jugular vein phlebectasia is a benign condition and usually asymptomatic.^[11] To our knowledge, there are only 50 cases reported in the English literature, 44 of whom were children since 1928.^[4] Although there have been additional cases documented in different languages, it still reserves its exceptional nature. The constant finding of physical examination is the increasing size during coughing, sneezing, crying and Valsalva maneuver, which was also observed in our case. Differential diagnosis of the non-pulsatile compressible soft neck masses which are enhanced by the maneuvers increasing the intrathoracic pressure should include the laryngocele, external laryngeal diverticulum, cupular inflation, tumors or cysts of the upper

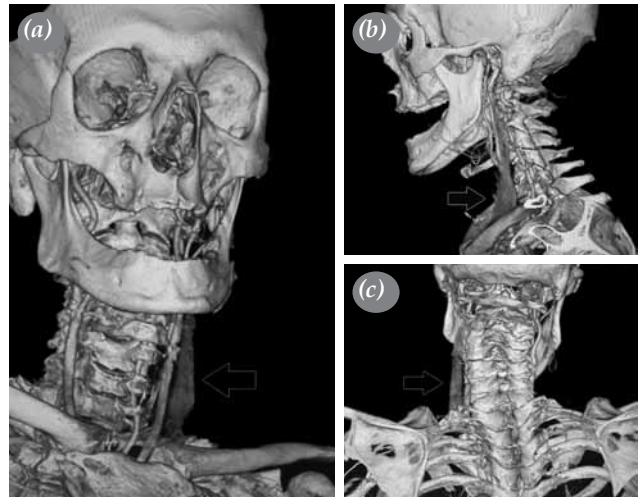


Figure 4. Three-dimensional reconstruction of computed tomography angiography scan. (a) Anterior view (arrow indicates the left internal jugular vein phlebectasia), (b) left lateral view, (c) posterior view.

mediastinum.^[12] Although the most common cause of a neck mass, which increases in size with Valsalva maneuver, is laryngocele, the possibility of IJV phlebectasia should always be considered, particularly in children.^[3]

Although the etiology is still unclear, its detection increased due to the availability of superior imaging techniques.^[13] Diagnosis of the IJV phlebectasia is usually best established by ultrasonography and a color flow imaging. The DUS is often useful and sufficient for the diagnosis and also recommended for the confirmation of the vascular flow. However, other radiological modalities such as the CT scan, venography, arteriography, magnetic resonance imaging, magnetic resonance angiography, digital subtraction angiography, CT angiography, and nuclear scintigraphy may be needed for further investigation.^[4] In the presented case, we initially examined the patient with a DUS and then performed CT scan and CT angiography (three-dimensional reconstruction) for detailed imaging and demonstration of the pathology (Figures 1-4).

Internal jugular vein phlebectasia has a benign course, except for some uncommon conditions.^[4] A case of a Horner's syndrome has been reported in the literature in which the compression of the sympathetic nerve fibers was related to the IJV phlebectasia in a child.^[14] Apart from the Horner's syndrome, some cases of thrombosis, congestive cardiac failure and massive hemorrhage secondary to traumatic rupture were reported.^[7,14,15] The spontaneous rupture has

never been reported.^[4] The association between IJV phlebectasia and Menkes disease has also been suggested.^[16] Menkes disease, known as the kinky hair disease, is a rare genetic neurodegenerative disorder of copper metabolism caused by mutations.^[17] In Menkes disease, deficiencies in copper-dependent enzyme lysyl oxidase is most likely responsible for the phlebectasia found in these patients.^[16] Neither such a clinic and complication nor a progression was observed in our patient within 12 months of follow-up.

Surgical treatment is recommended in patients who have phlebitis, thrombus formation, Horner's syndrome, intractable cough or for cosmetic reasons.^[1,2,4] Various surgical treatment options exist such as ligation of the affected vein or complete resection of this ectatic segment.^[11] The surgical procedure of the IJV phlebectasia mainly involves the ligation or excision of the involved jugular vein. It is safe, simple, and effective for most patients. However, in cases of lesions of the right and bilateral IJVs, longitudinal constriction suture venoplasty plus encapsulation might be preferable and safer, and should be recommended.^[18]

In conclusion, internal jugular vein phlebectasia is a rare condition that appears during exertion. Unless a complication occurs or the lesions become cosmetically disturbing, conservative treatment is recommended by most authors in asymptomatic cases because of a self-limiting nature of the pathology. Surgery is considered for cosmetic and psychological reasons and in symptomatic patients only. As phlebectasias are relatively uncommon among neck masses, this benign condition should initially be considered to avoid unnecessary investigations and perilous surgical procedures.

Declaration of conflicting interests

The authors declared no conflicts of interest with respect to the authorship and/or publication of this article.

Funding

The authors received no financial support for the research and/or authorship of this article.

REFERENCES

1. Chakraborty S, Dey PK, Roy A, Bagchi NR, Sarkar D, Pal S. Internal jugular vein phlebectasia presenting with hoarseness of voice. *Case Rep Vasc Med* 2013;2013:386961.
2. LaMonte SJ, Walker EA, Moran WB. Internal jugular phlebectasis. A clinicoroentgenographic diagnosis. *Arch Otolaryngol* 1976;102:706-8.
3. Bowdler DA, Singh SD. Internal jugular phlebectasia. *Int J Pediatr Otorhinolaryngol* 1986;12:165-71.
4. Erdem CZ, Erdem LO, Camuzcuoğlu I. Internal jugular phlebectasia: usefulness of color Doppler ultrasonography in the diagnosis. *J Trop Pediatr* 2002;48:306-10.
5. Gerwig WH Jr. Internal jugular phlebectasia. *Ann Surg* 1952;135:130-3.
6. Walsh RM, Murty GE, Bradley PJ. Bilateral internal jugular phlebectasia. *J Laryngol Otol* 1992;106:753-4.
7. Mickelson SA, Spickler E, Roberts K. Management of internal jugular vein phlebectasia. *Otolaryngol Head Neck Surg* 1995;112:473-5.
8. Kuo WR, Chien CC, Chai CY, Huang HR, Jan YS, Huang YC, et al. Internal jugular phlebectasia. *Gaoxiong Yi Xue Ke Xue Za Zhi* 1992;8:503-9.
9. Paleri V, Gopalakrishnan S. Jugular phlebectasia: theory of pathogenesis and review of literature. *Int J Pediatr Otorhinolaryngol* 2001;57:155-9.
10. Gendeh BS, Dhillon MK, Hamzah M. Bilateral internal jugular vein ectasia: a report of two cases. *J Laryngol Otol* 1994;108:256-60.
11. Abdulla AS, Aldabagh MH. Congenital phlebectasia of internal jugular vein. *Dohuk Med J* 2008;2:155-60.
12. Zohar Y, Ben-Tovim R, Talmi YP. Phlebectasia of the jugular system. *J Craniomaxillofac Surg* 1989;17:96-8.
13. Rossi A, Tortori-Donati P. Internal jugular vein phlebectasia and duplication: case report with magnetic resonance angiography features. *Pediatr Radiol* 2001;31:134.
14. Inci S, Bertan V, Kansu T, Cila A. Horner's syndrome due to jugular venous ectasia. *Childs Nerv Syst* 1995;11:533-5.
15. Balik E, Erdener A, Taneli C, Mevsim A, Sayan A, Yüce G. Jugular phlebectasia in children. *Eur J Pediatr Surg* 1993;3:46-7.
16. Price DJ, Ravindranath T, Kaler SG. Internal jugular phlebectasia in Menkes disease. *Int J Pediatr Otorhinolaryngol* 2007;71:1145-8.
17. Menkes JH, Alter M, Steigleder GK, Weakley DR, Sung JH. A sex-linked recessive disorder with retardation of growth, peculiar hair, and focal cerebral and cerebellar degeneration. *Pediatrics* 1962;29:764-79.
18. Jianhong L, Xuewu J, Tingze H. Surgical treatment of jugular vein phlebectasia in children. *Am J Surg* 2006;192:286-90.