

A rare case of *Hafnia alvei* pneumonia presenting with chronic obstructive pulmonary disease

Kronik obstrüktif akciğer hastalığı eşliğinde nadir bir Hafnia alvei pnömonisi olgusu

Harun Karamanlı,¹ Türkan Toka Özer²

Institution where the research was done:

Atatürk Chest and Chest Surgery Training and Research Hospital, Ankara, Turkey

Author Affiliations:

¹Department of Pulmonology, Atatürk Chest Diseases and Thoracic Surgery Training and Research Hospital, Ankara, Turkey

²Department of Microbiology, Medical Faculty of Mevlana University, Konya, Turkey

ABSTRACT

Hafnia alvei is a rarely seen pathogen in humans. In this article, we present a 58-year-old male case of *Hafnia alvei* with respiratory impairment due to a severe lower respiratory tract infection. Chest X-ray and computed tomography showed consolidation and significant infiltration in the right lung. Cultures of sputum were positive for Gram-negative rods, which were identified as *Hafnia alvei*. The patient was prescribed meropenem therapy for the eradication of the infection. This report presents a unique case of respiratory tract infection caused by *Hafnia alvei*.

Keywords: Chronic obstructive pulmonary disease; *Hafnia alvei*; pneumonia.

Hafnia alvei (*H. alvei*) is a Gram-negative, facultative anaerobic, rod-shaped bacterium of the Enterobacteriaceae family.^[1] It is typically defined as a gastrointestinal organism^[1] and is infrequently considered as a pathogen.^[2] It only expresses one virulence factor found in enteropathogenic *Escherichia*.^[3] In 1991, this organism was first described as an gastrointestinal pathogen.^[3]

Although, *H. alvei* is typically considered as a commensal organism of the enteric tract, recent reports have suggested that it has the potential to be a serious human pathogen.^[2] Herein, we report a 58-year-old male case with respiratory impairment due to a severe lower respiratory tract infection caused by *H. alvei*.

ÖZ

Hafnia alvei, insanlarda nadir rastlanan bir patojendir. Bu yazıda, şiddetli alt solunum yolu enfeksiyonu olan 58 yaşında bir erkek *Hafnia alvei* olgusu sunuldu. Göğüs röntgeni ve bilgisayarlı tomografisinde sağ akciğerde belirgin konsolidasyon ve anlamlı infiltrasyon izlendi. Balgam kültürü, *Hafnia alvei* olarak tespit edilen Gram negatif basiller açısından pozitif idi. Hastaya enfeksiyon eradikasyonu için meropenem tedavisi verildi. Bu yazıda *Hafnia alvei*'nin neden olduğu nadir bir solunum yolu enfeksiyonu olgusu sunuldu.

Anahtar sözcükler: Kronik obstrüktif akciğer hastalığı; *Hafnia alvei*; pnömoni.

CASE REPORT

A 58-year-old man with severe chronic obstructive pulmonary disease (COPD) who had a history of smoking 40 packs/day over the course of several years was admitted to the emergency department due to progressive dyspnea, fever, cough, and increasing sputum for three days. On admission, the patient was pale, dyspneic, febrile, and in a poor condition. Physical examination revealed a body weight of 65 kg, a height of 168 cm, a pulse rate of 104 beats/min, a blood pressure of 108/65 mmHg, a body temperature of 39.4 °C, and a respiration rate of 24 breaths/min. Abdominal examination findings were unremarkable. On auscultation of the lungs,



Available online at
www.tgkdc.dergisi.org
doi: 10.5606/tgkdc.dergisi.2017.12905
QR (Quick Response) Code

Received: January 06, 2016 Accepted: August 15, 2016

Correspondence: Harun Karamanlı, MD. Atatürk Göğüs Hastalıkları ve Göğüs Cerrahisi Eğitim ve Araştırma Hastanesi, Göğüs Hastalıkları Kliniği, 06280 Keçioren, Ankara, Turkey. Tel: +90 505 - 767 15 33 e-mail: drharun@hotmail.com

©2017 All right reserved by the Turkish Society of Cardiovascular Surgery.

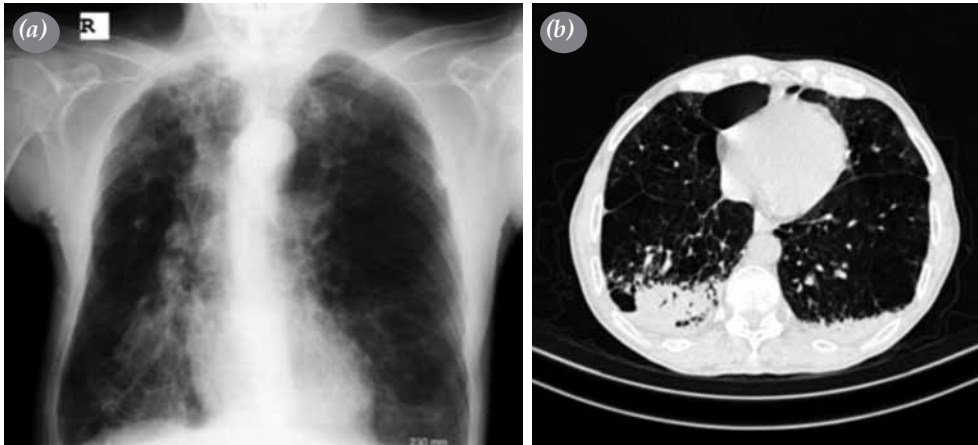

Figure 1. A chest X-ray and computed tomography scan showing (a) consolidation and (b) significant infiltrations in the right lung.

crackles in the right lung base were heard. His level of consciousness was alert.

Chest X-ray and computed tomography (CT) showed consolidation and significant infiltration in the right lung (Figure 1a, b).

Laboratory test results were as follows: white blood cell count $23,000/\text{mm}^3$, neutrophils 87%, hemoglobin 15.9 g/dL, platelet count $323,000/\text{mm}^3$, and C-reactive protein 97 mg/dL. Arterial blood gas analysis showed increased carbon dioxide retention (PCO_2 : 59.6 mmHg) and a reduced ratio of partial pressure of oxygen in arterial blood

(PaO_2 : 52.1 mmHg). Therapy for progressive respiratory failure consisted of inhaled [beta]-adrenergic agonists, oxygen administration, empirical antibiotherapy, and intensive chest care. Initially, ampicillin/sulbactam 1.5 g q6h and clarithromycin 1000 mg/day were prescribed for the treatment of pneumonia.

The cultures of sputum specimens yielded Gram-negative rods identified as *H. alvei* using the Nuve N120 System[®] (Nuve Laboratory and Sterilization Technology, Ankara, Turkey) (Figures 2, 3). Laboratory contamination was ruled out. Based on the culture findings, as *H. alvei* was susceptible

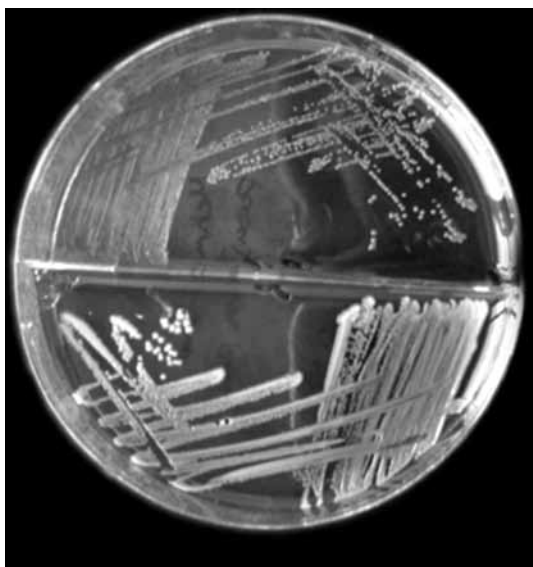


Figure 2. Cultures of sputum specimen yielding Gram-negative rods, which were then identified as *H. alvei*.

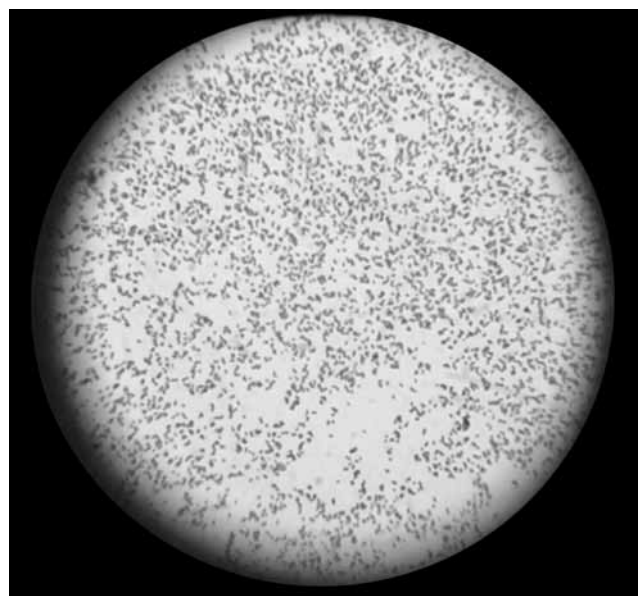


Figure 3. Gram-negative rods in the microscopy image.

Table 1. Antibiotic susceptibility of *Hafnia alvei*

Antibiotics	Sensitive	Moderate sensitive	Resistant
Trimethoprim/sulfamethoxazole	+		
Cefuroxime		+	
Cefixime	+		
Cefazolin			+
Nitrofurantoin		+	
Amoxicillin/clavulanic acid			+
Gentamicin	+		
Fosfomicin	+		
Ampicillin + sulbactam			+
Meropenem	+		

to aminoglycosides, meropenem, trimethoprim/sulfamethoxazole, and cefixime, antibiotic regimen was replaced with intravenous meropenem 3 g/day. The patient completed his treatment, and repeated sputum culture yielded negative for *H. alvei*.

DISCUSSION

Extraintestinal invasive infections caused by *H. alvei* usually occur in patients with chronic debilitating diseases.^[2] This species is rarely isolated in human specimens and it is very rarely thought to be pathogenic. In humans, however, it can cause a range of infections, including urinary tract infections, bacteremia, pneumonia, and extraintestinal infections.^[4,5]

To the best of our knowledge, only three *H. alvei* cases have been reported as the main cause of pulmonary infections in the literature.^[6] In one study, *H. alvei* was isolated in the respiratory tracts of five individuals, from whom 760 enterobacter isolates were obtained over the course of a three-year study.^[7] Three of these individuals presented with chronic respiratory disease. Four of the isolates were derived in sputum specimens, and one was in the trachea. Two isolates were the predominant microorganisms in two individuals with bronchopneumonia. Frick et al.^[6] also reported that a bronchoscopic sample obtained from a patient with pneumonia on mechanical ventilation for 12 days was positive for *H. alvei*.

Although *H. alvei* is thought to originate from the gastrointestinal tract, little is known about its opportunistic nature.^[8] However, several studies have demonstrated that it causes infection by entering the bloodstream through the gastrointestinal tract. On the other hand, it is still unknown whether its weak pathogenicity with respect to extraintestinal infections is due to the level of expression of virulence factors.^[9] The intra-abdominal area and urinary tract

are common sites of *H. alvei* infections. In addition, it is important to note that this microorganism is associated with biliary tree infections^[2] and subsequent abscess formation.^[10]

There are numerous extraintestinal infections caused by *H. alvei* in patients with chronic underlying diseases, such as immunodeficiency and cancer, in particular, hematological malignancies.^[5] Our case had severe underlying disease, COPD, which may have promoted the occurrence of this uncommon infection. In addition, although *H. alvei* is an unusual etiological factor for pulmonary infections, several cases have been reported. Therefore, patients with respiratory and chronic diseases should be given information on this microorganism.^[11] In the literature, most reports on invasive infection have been based on individual patients.^[12,13]

Furthermore, this rare organism can occur in patients with surgical wound infections or abscesses, organ transplant patients,^[7] and patients with a postoperative indwelling catheter.^[10] Standard surgical treatments can be performed in these patients, when necessary. Respiratory isolates can be isolated in patients undergoing thoracic surgery or inpatients due to trauma. The prevalence of so-called rare bacterial infections increases, contributing considerably to morbidity and mortality following thoracic surgery.^[14]

In our case, we prescribed the most appropriate treatment based on the results of sensitivity testing. Antibiotic susceptibility to *Hafnia alvei* was evaluated using a disk diffusion method according to the guidelines published by the National Committee for Clinical Laboratory Standards. Strains were evaluated as susceptible, moderately susceptible, or resistant. *Hafnia alvei* is typically resistant to the first-generation cephalosporin and amoxicillin and is able to rapidly become resistant to the second- or third-generation

cephalosporins.^[13,15] Antimicrobials which are known to be effective against the isolated strain of *H. alvei* include ciprofloxacin, aminoglycosides, ceftriaxone, cefotaxime, imipenem, ticarcillin, piperacillin, and co-trimoxazole.^[13,15] In our case, the results were consistent with those reported in previously published studies (Table 1). However, in our case, no susceptibility to amoxicillin/clavulanic acid or first-generation cephalosporin was detected. Considering these results, we treated our patient with meropenem, which eradicate the infection successfully.

In conclusion, this report presents a rare causative agent of pneumonia, *H. alvei*. We believe that further researches would be useful to elucidate the pathogenesis of *H. alvei* in detail, as this is one of very few studies of this pathogen.

Declaration of conflicting interests

The authors declared no conflicts of interest with respect to the authorship and/or publication of this article.

Funding

The authors received no financial support for the research and/or authorship of this article.

REFERENCES

1. Gelev I, Gelev E, Steigerwalt AG, Carter GP, Brenner DJ. Identification of the bacterium associated with haemorrhagic septicaemia in rainbow trout as *Hafnia alvei*. *Res Microbiol* 1990;141:573-6.
2. Günthard H, Pennekamp A. Clinical significance of extraintestinal *Hafnia alvei* isolates from 61 patients and review of the literature. *Clin Infect Dis* 1996;22:1040-5.
3. Albert MJ, Alam K, Islam M, Montanaro J, Rahaman AS, Haider K, et al. *Hafnia alvei*, a probable cause of diarrhea in humans. *Infect Immun* 1991;59:1507-13.
4. Crandall C, Abbott SL, Zhao YQ, Probert W, Janda JM. Isolation of toxigenic *Hafnia alvei* from a probable case of hemolytic uremic syndrome. *Infection* 2006;34:227-9.
5. Ramos A, Dámaso D. Extraintestinal infection due to *Hafnia alvei*. *Eur J Clin Microbiol Infect Dis* 2000;19:708-10.
6. Frick T, Kunz M, Vogt M, Turina M. Typical nosocomial infection with an unusual cause: *Hafnia alvei*. Report of 2 cases and literature review]. *Schweiz Rundsch Med Prax* 1990;79:1092-4. [Abstract]
7. Washington JA 2nd, Birk RJ, Ritts RE Jr. Bacteriologic and epidemiologic characteristics of *Enterobacter hafniae* and *Enterobacter liquefaciens*. *J Infect Dis* 1971;124:379-86.
8. Conte M, Castagnola E, Venzano P, Tasso L, Giacchino R. Bacteremia caused by *Hafnia alvei* in a human immunodeficiency virus-infected child. *Pediatr Infect Dis J* 1996;15:182-3.
9. Podschun R, Fischer A, Ullmann U. Characterisation of *Hafnia alvei* isolates from human clinical extra-intestinal specimens: haemagglutinins, serum resistance and siderophore synthesis. *J Med Microbiol* 2001;50:208-14.
10. Agustin ET, Cunha BA. Buttock abscess due to *Hafnia alvei*. *Clin Infect Dis* 1995;20:1426.
11. Klapholz A, Lessnau KD, Huang B, Talavera W, Boyle JF. *Hafnia alvei*. Respiratory tract isolates in a community hospital over a three-year period and a literature review. *Chest* 1994;105:1098-100.
12. Gallego Page JC, Sánchez Alor G, Ortigosa Aso FJ, Ugarte Basterrechea J. [Article in Spanish] [Mitral valve prosthetic endocarditis due to *Hafnia alvei*]. *Med Clin (Barc)* 1999;112:199.
13. Fazal BA, Justman JE, Turett GS, Telzak EE. Community-acquired *Hafnia alvei* infection. *Clin Infect Dis* 1997;24:527-8.
14. Polk HC Jr, Heinzelmann M, Mercer-Jones MA, Malangoni MA, Cheadle WG. Pneumonia in the surgical patient. *Curr Probl Surg* 1997;34:117-200.
15. Thomson KS, Sanders CC, Washington JA. Ceftazidime resistance in *Hafnia alvei*. *Antimicrob Agents Chemother* 1993;37:1375-6.