

Fatal pulmonary embolism in an adolescent case: Cardiac and hepatic hydatid cyst

Ergen olguda ölümcül pulmoner emboli: Kardiyak ve hepatik kist hidatik

Erman Cılsal,¹ Okan Dilek,² Cengiz Yılmaz²

Departments of ¹Pediatric Cardiology, ²Radiology, Adana Numune Training and Research Hospital, Adana, Turkey

ABSTRACT

Hydatid cysts are mostly located in the visceral organs, and cardiac involvement is very rare. Pulmonary arterial embolisms due to hydatid cyst are extremely rare, and they usually develop secondary to the rupture of a cardiac or hepatic hydatid cyst. Herein, we describe a case of clinically silent, but disseminated pulmonary embolism originating from a right ventricular hydatid cyst. Patients with a disseminated pulmonary embolism have a poor prognosis in case of delayed diagnosis, and these patients under anti-parasitic treatment after hydatid cyst resection should be monitored carefully and screened routinely in terms of visceral organ involvement.

Keywords: Cardiac hydatid cyst; echocardiography; hydatid cyst; pulmonary embolism.

Hydatid cyst disease is an important parasitic disease which affects all populations in the world, where agriculture and stockbreeding are common and preventive healthcare services are limited. There are three forms of echinococcosis affecting humans; cystic echinococcosis (by *E. granulosus*), alveolar echinococcosis (*E. multilocularis*), and polycystic echinococcosis (*E. vogeli* and *E. oligarthus*).^[1] These cysts are mostly located in the liver, lungs, and rarely in the heart. Cardiac involvement in hydatid disease is not common, and cardiac hydatid cysts are extremely rare. Of all the reported cases of echinococcosis, cardiac hydatid cysts range between 0.5 and 2%.^[2] Although pulmonary arterial cyst embolization is also very rare, it has a high mortality rate.^[3] Intra-cardiac cysts may lead to multiple

ÖZ

Kist hidatik sıklıkla iç organ yerleşimli olup, kardiyak tutulum çok nadirdir. Kist hidatiğe bağlı pulmoner arter embolisi son derece nadir olup, genellikle kardiyak veya hepatik kist rüptürüne bağlı olarak ortaya çıkmaktadır. Bu makalede, sağ ventrikülde kist hidatik kaynaklı klinik olarak sessiz, ancak yaygın bir pulmoner emboli olgusu sunuldu. Tanının gecikmesi durumunda yaygın pulmoner kist hidatik embolisi olan hastaların prognozu kötüdür ve kist hidatik rezeksiyonu sonrası antiparaziter tedavi alan bu hastalar titizlikle izlenmeli ve iç organ tutulumu açısından rutin olarak taranmalıdır.

Anahtar sözcükler: Kardiyak kist hidatik; ekokardiyografi; kist hidatik; pulmoner emboli.

micro- and cystic pulmonary embolism. Herein, we reported a case who developed disseminated pulmonary embolism originating from a liver and cardiac hydatid cyst with delayed diagnosis and fatal prognosis.

CASE REPORT

A 15-year-old female patient was admitted to our emergency unit with dyspnea and chest pain complaints. She was referred to our clinic for echocardiographic evaluation. Her medical history revealed a successful operation in our hospital three years ago due to hepatic cyst hydatid disease, and oral albendazole treatment for nearly one year. Echocardiography which was performed one year ago showed normal findings.



Available online at
www.tgkdc.dergisi.org
doi: 10.5606/tgkdc.dergisi.2017.13968
QR (Quick Response) Code

Received: October 11, 2016 Accepted: January 04, 2017

Correspondence: Erman Cılsal, MD. Adana Numune Eğitim ve Araştırma Hastanesi, Çocuk Kardiyoloji Kliniği, 01370 Yüreğir, Adana, Turkey.

Tel: +90 322 - 355 01 01 e-mail: ermancılsal@gmail.com

©2017 All right reserved by the Turkish Society of Cardiovascular Surgery.

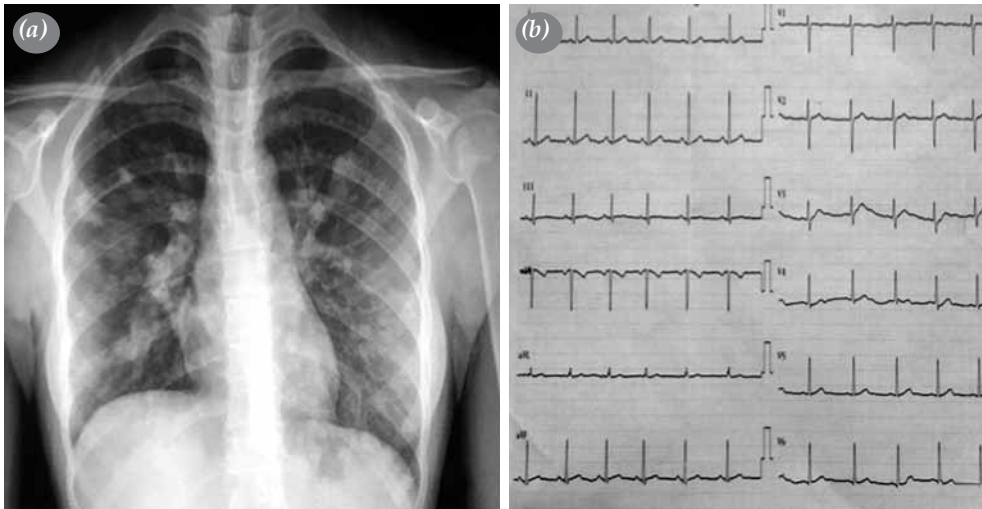


Figure 1. (a) A chest X-ray image showing bilateral nodular opacities at middle and lower zones and (b) an electrocardiogram showing normal findings.

On physical examination, vital signs and cardiac and other system findings were unremarkable. Laboratory tests revealed eosinophilia (13%), and mildly elevated sedimentation rates. Chest X-ray showed bilateral nodular opacities at the middle and lower zones (Figure 1a). Electrocardiographic findings were normal on admission and throughout the hospitalization period (Figure 1b). Transthoracic echocardiography showed a

single echogenic, immobile, rounded mass with central cystic alterations measuring 3.2x1.2 cm localized within the right ventricle apex (Figure 2). Cross-sectional echocardiography showed no dilatation of the main pulmonary artery and branches, and there were no signs of thrombus or pulmonary hypertension. Contrast-enhanced thoracic computed tomography (CT) showed bilateral multiple nodular lesions

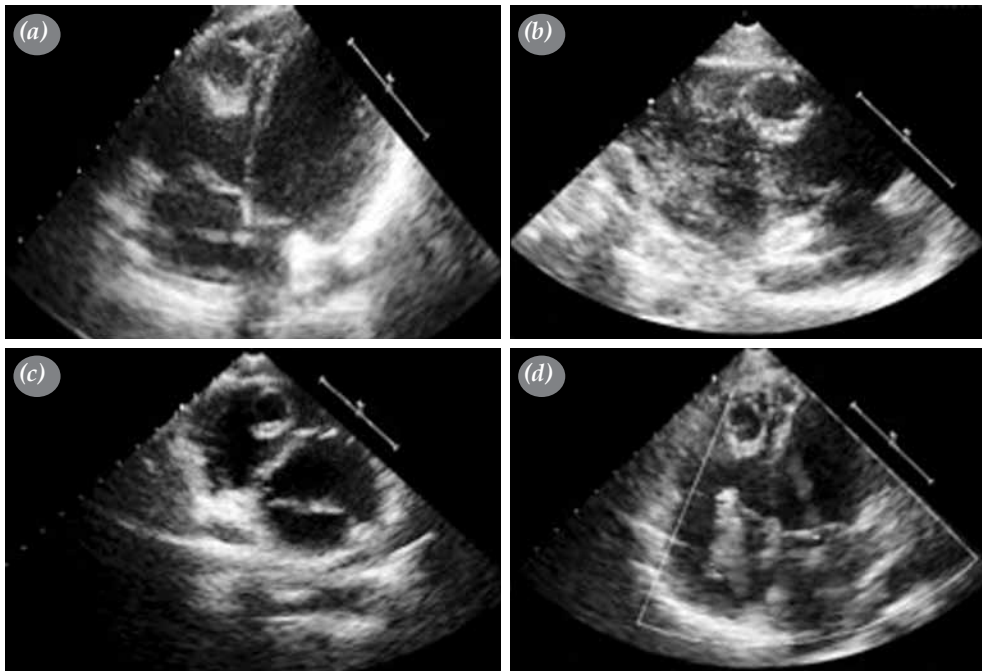


Figure 2. A transthoracic echocardiographic apical four-chamber (a-d) and short-axis view (b-c) showing a single echogenic, immobile, rounded mass with central cystic changes localized in right ventricle apex region and mild tricuspid regurgitation.

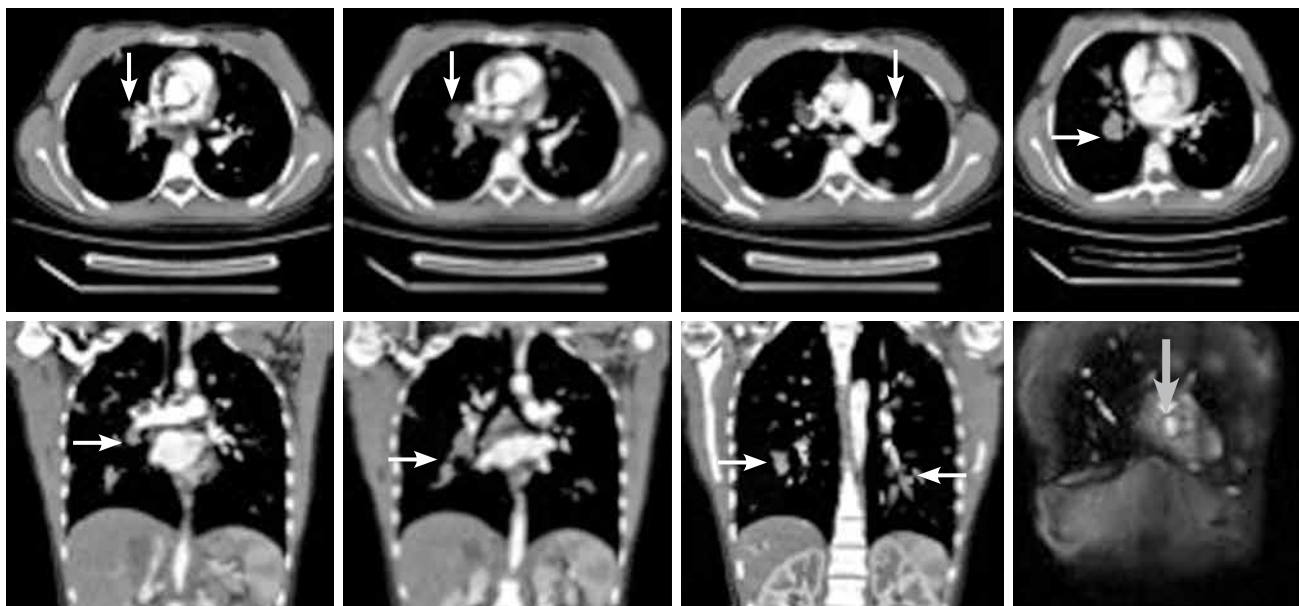


Figure 3. Transverse and coronal contrast-enhanced thoracic computed tomography scans showing bilateral multiple, cystic lesions within major and distal pulmonary artery branches (white arrow). Coronal contrast-enhanced magnetic resonance imaging scans showing a left ventricular cystic mass with a hypointense peripheral rim at T₂-weighted images (gray arrow) consistent with a hydatid cyst.

with a maximum diameter of 1.2 cm. Widespread hypodense nodular lesions were located within the main, lobar, and segmental pulmonary artery branches (Figure 3). Abdominal ultrasonography revealed a 2.7 cm hypodense lesion within the right lobe of the liver, in close proximity to the inferior caval vein. In addition, fat attenuation spots (fat droplets) within the lesion compatible with hydatid cyst were noted. Cardiac magnetic resonance imaging (MRI) also confirmed a cystic mass with a hypointense rim on T₂-weighted images (Figure 3).

Cranial CT showed no hydatidosis. Cardiac surgery was planned after a few days of therapy with 400 mg albendazole three times a day. After median sternotomy, the cyst inside the right ventricle was removed and extirpation of the lesion was completed under cardiopulmonary bypass. After removal of a section of the endoarterial hydatid cysts from the distal part of the right pulmonary artery during suction, a sudden complication developed secondary to hydatid pulmonary embolism. As a result, the patient had to undergo right pneumonectomy due to abundant hemoptysis from the endotracheal tube under total circulatory arrest. At the end of the procedure, due to hemodynamic deterioration, the patient was admitted to the intensive care unit with the support of extracorporeal membrane oxygenation (ECMO).

In the early postoperative period, the patient had an abnormally pupillary reflex, and it became obvious that a diffuse cerebral edema occurred, which was confirmed by CT. Although the need for inotropic support reduced in the postoperative first days and ECMO support was terminated on the fifth day, the patient died due to the disruption of the sudden hemodynamics on Day 17.

DISCUSSION

In Turkey, hydatid cyst is an endemic disease, and the annual incidence of hydatid disease is about 4.9/100,000.^[4] The most common organ involvement of hydatid cyst is liver and lungs, kidney, spleen, orbital, brain, heart, and bone. Cardiac involvement is a very rare involvement, and the left ventricle (60 to 70%) is the most frequently affected region.^[5] Decreasing order of frequency is right ventricle (10%), pericardium (7%), pulmonary artery (6%), atrial appendix (6%), and interventricular septum (4%).^[6,7] Pulmonary artery localization is a rare form of hydatid cysts. Pulmonary cyst embolization is thought to be caused by rupture of visceral cysts and migration of daughter vesicles through venous circulation or by rupture of cardiac cysts in the right ventricle.^[8] An extraordinary finding seen in our case is that, despite the widespread embolism of the pulmonary artery, there was no

evidence of pulmonary arterial hypertension. The rupture of cysts in micro-cysts resulting in pulmonary artery embolization may explain this mechanism.^[9] In certain cases, chest X-ray may reveal a parenchymal cystic mass or distortion of the heart contours, while echocardiography is helpful to assess the nature and localization of the cyst. The CT and MRI are useful in the differential diagnosis. Thoracic CT and CT angiography and pulmonary angiography are also extremely useful modalities for the diagnosing of pulmonary embolization.

Cardiac hydatid cysts should be surgically removed with appropriate technique due to the location of the cyst. Oral albendazole therapy should be administered to reduce the size of the cyst before excision and to prevent recurrence. The most important indicator of prognosis is pulmonary involvement and dissemination throughout the lung which complicates surgery. Occasionally, patients are lost secondary to anaphylactic shock, cardiac tamponade, and systemic or pulmonary embolization. The most life-threatening complication of cardiac hydatid cyst is perforation and with a reported intra-cardiac perforation frequency of 25 to 40%,^[6-10] After cyst perforation, three quarters of the patients die from embolic complications.

In conclusion, hydatid cyst patients should be carefully followed after surgical resection and monitor their adherence to anti-parasitic therapies. A routine echocardiographic imaging of patients with visceral hydatid disease can be also useful in detecting early cardiac involvement.

Declaration of conflicting interests

The authors declared no conflicts of interest with respect to the authorship and/or publication of this article.

Funding

The authors received no financial support for the research and/or authorship of this article.

REFERENCES

1. McManus DP, Zhang W, Li J, Bartley PB. Echinococcosis. *Lancet* 2003;362:1295-304.
2. Dighiero J, Canabal EJ, Aguirre CV, Hazan J, Horjales JO. Echinococcus disease of the heart. *Circulation* 1958;17:127-32.
3. Bakan S, Kandemirli S, Yıldırım O, Ersen E, Yanartaş M, Taşçı E, et al. Hydatid cysts of the pulmonary artery *Turk Gogus Kalp Dama* 2016;24:592-5.
4. Eroğlu A, Aydın Y, Altuntaş B, Ulaş AB. Surgical management of primary mediastinal hydatid cysts: a 30-year experience. *Turk Gogus Kalp Dama* 2016;24:495-500.
5. Shevchenko YL, Travin NO, Musaev GH, Morozov AV. Heart echinococcosis: current problems and surgical treatment. *Multimed Man Cardiothorac Surg* 2006;2006(810):mmcts.2 005.001115.
6. Ozsoyler I, Ozgen H, Uncu H, Yildiz GD, Ocak FT. Interventricular septal echinococcosis associated with multiple intracranial hydatid cyst. *Turk Gogus Kalp Dama* 2015;23:140-2.
7. Dursun M, Terzibasoglu E, Yilmaz R, Cekrezi B, Olgar S, Nisli K, et al. Cardiac hydatid disease: CT and MRI findings. *AJR Am J Roentgenol* 2008;190:226-32.
8. Odev K, Acikgözoglu S, Gormüs N, Aribas OK, Kiresi DA, Solak H. Pulmonary embolism due to cardiac hydatid disease: imaging findings of unusual complication of hydatid cyst. *Eur Radiol* 2002;12:627-33.
9. Lioulias A, Kotoulas C, Kokotsakis J, Konstantinou M. Acute pulmonary embolism due to multiple hydatid cysts. *Eur J Cardiothorac Surg* 2001;20:197-9.
10. Shevchenko YL, Travin NO, Musaev GH, Morozov AV. Heart echinococcosis: current problems and surgical treatment. *Multimed Man Cardiothorac Surg* 2006;2006(810):mmcts.2 005.001115.