



Tracheobronchial foreign bodies have never been so strange!

Trakeobronşiyal yabancı cisimler hiç bu kadar tuhaf olmamıştı!

Özgür Katrancıoğlu , Ekber Şahin , Şule Karadayı , Melih Kaptanoğlu 

Department of Thoracic Surgery, Medicine Faculty of Cumhuriyet University, Sivas, Turkey

ABSTRACT

Background: In the present study, we aimed to present our experience about retrieval of foreign bodies over a 28-year period.

Methods: We retrospectively analyzed the files of 22 patients (18 males, 4 females; mean age 34.9 years; range, 9 months to 80 years) who required removal of a foreign body from the tracheobronchial tree between April 1987 and December 2015.

Results: A total of 72.7% of the study group were 10 years old or older. There was no history of aspiration in 37% of cases, most often in older patients. Of the 22 unusual foreign bodies, seven (31.8%) were aspirated through permanent tracheostomy. The strangest foreign bodies were grass inflorescences, an acacia thorn, and construction nail. The foreign bodies were removed by rigid bronchoscopy in 18 patients, while thoracotomy was performed in two patients, and pericardiotomy in one patient. No intervention was required in one patient.

Conclusion: The elderly and patients with tracheostomies may aspirate unusual foreign bodies. Even if there is no history of aspiration, the differential diagnosis of cough or dyspnea should include foreign body aspiration.

Keywords: Airway; bronchus; foreign body aspiration; trachea; tracheostomy; unusual foreign bodies.

Foreign body aspiration often requires an emergency intervention, since it can be life-threatening.^[1,2] This condition is most oftenly seen in children, particularly those aged one to three years. In this age group, 7% of accidental deaths are due to foreign body aspiration.^[3] In adults, although foreign body aspiration is less frequent, it can still be life-threatening.^[4] Among adults, foreign body aspiration is most frequent in the elderly who may aspirate unusual objects.^[5] In the present study, we aimed to present our experience

ÖZ

Amaç: Bu yazıda 28 yıl boyunca yabancı cisim çıkarılmasına ilişkin deneyimimiz sunuldu.

Çalışma planı: Nisan 1987 - Aralık 2015 tarihleri arasında trakeobronşiyal ağaçtan yabancı cisim çıkarılan 22 hastanın (18 erkek, 4 kadın; ort. yaş 34.9 yıl; dağılım, 9 ay-80 yıl) dosyası retrospektif olarak incelendi.

Bulgular: Çalışma grubumuzun %72.7'si 10 yaş ve üzeri idi. Olguların %37'sinde özellikle de yaşlı hastalarda, aspirasyon öyküsü yoktu. Tuhaf 22 yabancı cisimden yedisi (%31.8) kalıcı trakeostomide aspire edilmişti. En dikkat çekici yabancı cisimler pisipisi otu, akasya dikenini ve inşaat çivisi idi. Yabancı cisimler 18 hastada bronkoskopi ile çıkarılırken, iki hastaya torakotomi ve bir hastaya perikardiyotomi yapıldı. Bir hastada herhangi bir girişim gerekmedi.

Sonuç: Yaşlı ve trakeostomili hastalarda tuhaf yabancı cisimler aspire edebilmektedir. Aspirasyon öyküsü olmasa dahi, öksürük ve dispnenin ayırıcı tanısında yabancı cisim aspirasyonu akla gelmelidir.

Anahtar sözcükler: Havayolu; bronş; yabancı cisim aspirasyonu; trakea; trakeostomi; tuhaf yabancı cisimler.

about retrieval of foreign bodies over a 28-year period.

PATIENTS AND METHODS

Medical files of a total of 475 patients who required removal of a foreign body from the tracheobronchial tree in our clinic between April 1987 and December 2015 were retrospectively analyzed. A total of 22 patients (18 males, 4 females; mean age 34.9 years; range, 9 months to 80 years)

Received: February 20, 2017 Accepted: June 02, 2017

Correspondence: Özgür Katrancıoğlu, MD. Cumhuriyet Üniversitesi Tıp Fakültesi, Göğüs Cerrahisi Anabilim Dalı, 58140 Sivas, Turkey.
Tel: +90 346 - 258 19 45 e-mail: ozgursongur@gmail.com

Cite this article as:

Katrancıoğlu Ö, Şahin E, Karadayı Ş, Kaptanoğlu M. Tracheobronchial foreign bodies have never been so strange!. Turk Gogus Kalp Dama 2018;26(2):260-264.

were included. All patients were evaluated in terms of age, gender, admission time, initial diagnosis, features of the aspirated foreign body, entry route, localization, and treatment. This study was approved by the Ethics Committee of Medicine Faculty of Cumhuriyet University (No. 2016-04/16). The study was conducted in accordance with the principles of the Declaration of Helsinki. The diagnoses were based on the history, symptoms, physical examination, and radiology studies. Plain posteroanterior chest X-rays were obtained from all patients. Two patients required thoracic computed tomography (CT). Rigid bronchoscopy was performed under general anesthesia and the unusual objects were removed in all, but two patients who aspirated grass inflorescences (one patient who aspirated a plastic whistle and one patient who aspirated a sewing needle). Of these last four patients, two required thoracotomy as one of them had bronchiectasis symptoms and the foreign body imitated the lung mass in the other patient

(Table 1) and another patient required thoracotomy and pericardiotomy to remove the foreign object.

Statistical analysis

Statistical analysis was performed using the IBM SPSS for Windows version 22.0 software (IBM Corp., Armonk, NY, USA). Descriptive statistics were expressed in mean, standard deviation (SD), number, and percentage. A *p* value of less than 0.05 was considered statistically significant.

RESULTS

Of 22 patients, 16 were older than 10 years (Figure 1). The aspirated foreign bodies (Table 1) included grass inflorescences (Figure 2), an acacia thorn, and an 11-cm-long construction nail (Figure 3).

The majority of the patients (n=14, 63.6%) were admitted on the day of the event. The longest delay was in one patient who underwent left inferior lobectomy

Table 1. Foreign bodies in cases, entry way and applied treatments

Case no	Foreign bodies	Entry way	Settlement	Applied treatments
1	Voice prosthesis device	Tracheostomy	Right main bronchus	Rigid bronchoscopy
2	Construction nail	Tracheostomy	Left main bronchus	Rigid bronchoscopy
3	A piece of wood	Tracheostomy	Right main bronchus	Rigid bronchoscopy
4	Grass inflorescence	Tracheostomy	Lung	Spontaneous
5	Grass inflorescence	Tracheal	Lung	Spontaneous + thoracotomy
6	Stile part	Tracheal	Right main bronchus	Rigid bronchoscopy
7	Acacia thorn	Tracheal	Right main bronchus	Rigid bronchoscopy
8	Bone	Tracheal	Left lower lobe bronchus	Rigid bronchoscopy
9	Wild spike	Tracheal	Right upper lobe bronchus	Rigid bronchoscopy
10	Screw	Tracheal	Right main bronchus	Rigid bronchoscopy
11	Plastic whistle	Tracheal	Tracheal	Rigid bronchoscopy
12	Plastic whistle	Tracheal	Left lower lobe bronchus	Rigid bronchoscopy + thoracotomy
13	Nail head	Tracheal	Tracheal	Rigid bronchoscopy
14	Tablets medicine	Tracheal	Left lower lobe bronchus	Rigid bronchoscopy
15	Sewing needle	Tracheal	Pericardium	Rigid bronchoscopy + pericardiotomy
16	Plaster part	Tracheal	Right main bronchus	Rigid bronchoscopy
17	Screw	Tracheal	Right main bronchus	Rigid bronchoscopy
18	Chinese checkers move	Tracheal	Right lower lobe bronchus	Rigid bronchoscopy
19	Rolled napkins	Tracheostomy	Tracheal	Rigid bronchoscopy
20	Two voice prosthesis device	Tracheostomy	Bilateral main bronchus	Rigid bronchoscopy
21	Tracheostomy cannula	Tracheostomy	Left main bronchus	Rigid bronchoscopy
22	Valve needle	Tracheal	Right main bronchus	Rigid bronchoscopy

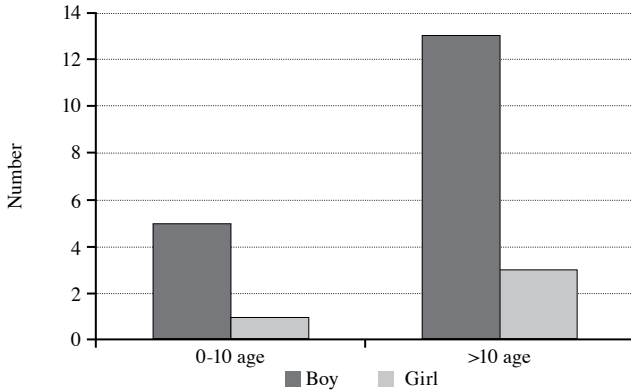


Figure 1. Age distribution of cases.

for bronchiectasis, and who applied six years after aspiration. The most common complaints on admission were cough and dyspnea. Physical examination findings were unremarkable in a total of 40.9% of the patients, while rhonchi were noted in 59% of the patients, rales in 13.6%, and unilateral decreased breath sounds in 31.8%. Of 22 foreign bodies, seven (31.8%) were aspirated through permanent tracheostomy (Table 1). These




Figure 2. Image of removed grass inflorescence.

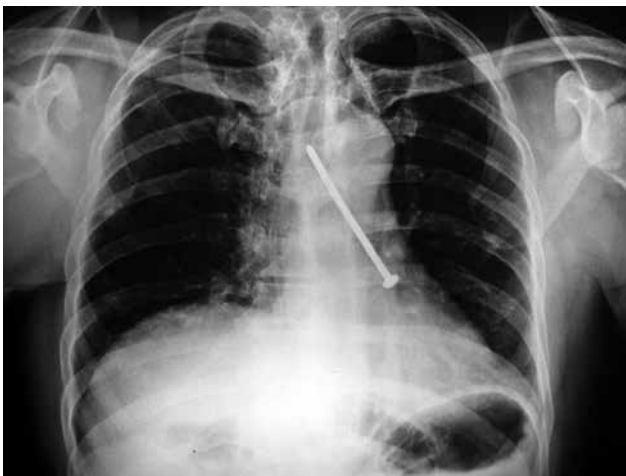

Figure 3. Image of the aspirated construction nail on posteroanterior chest X-ray.




Figure 4. Image of removed voice prosthesis device.

objects included a roll of napkins used for cleaning purposes, a piece of wood with cloth wrapped around one end, voice devices (Figure 4), and an 11-cm-long construction nail. The most common location of the foreign bodies was the right bronchial system (n=11), followed by the left bronchial system (n=6), trachea (n=3), and pericardium (n=1). Two voice prostheses were removed from one patient, although the devices were aspirated at different times. Two patients, both of whom aspirated grass inflorescence, expelled the foreign body spontaneously. As the grass inflorescence can move spontaneously via its own branches, it primarily advanced to the lung parenchyma and, then, passed through the chest wall and no intervention was required, while it was expelled spontaneously in the other patient and thoracotomy was performed for massive hemoptysis. The radiological studies were either unremarkable or they showed the foreign object or atelectasis, an indirect radiological sign of the object. Rigid bronchoscopy was performed in 18 of 22 patients, thoracotomy in two patients, and pericardiectomy in one patient. No intervention was required in the remaining patient. None of the patients developed any post-procedural complication.

DISCUSSION

Although aspiration can be seen in all age groups, most patients are younger than 10 years of age.^[6,7]

Foreign body aspiration is rare at advanced ages.^[8,9] and the frequency of unusual foreign bodies has been increasing.^[4,5,10,11] Of our atypical patients, 16 (72.7%) were older than 10 years of age. In addition, aspiration was more common in males (81.8%), which is consistent with the literature.^[2,12]

Admission time is influenced by the awareness level of the patients and their relatives, socioeconomic status of the family, and referral to a relevant specialist in the healthcare facility.^[3] In our series, the earliest admissions, for most patients, were on the same day as the event and the latest admission was six years after aspiration. It is easier to remove a foreign body on bronchoscopy in patients who present early,^[3] while complications may develop in patients who present late. These complications include bronchial stenosis, bronchiectasis, recurrent pneumonia, lung abscess, and hemoptysis.^[4,13,14] In our series, a dramatic complication was observed in one patient who presented with massive hemoptysis three months after aspirating a grass inflorescence, and this patient required right lower lobectomy (Case No. 5). The other late-admission patient who had a negative history aspirated a sewing needle and on plain X-rays, pericardial effusion was also observed. Initially, rigid bronchoscopy was performed and, then, the foreign body was removed via thoracotomy and pericardiotomy (Case No. 15). Foreign bodies may mimic many pathological conditions of the tracheobronchial tree. A foreign body may present as a mass with the growth of granulation tissue.^[4] In our series, a 70-year-old patient aspirated a bone fragment one month earlier; the patient did not specify this event in his history and presented to the chest medicine clinic with dyspnea. Atelectasis was observed on radiography and fiberoptic bronchoscopy was performed. An endobronchial lesion was considered, as the foreign body triggered marked peripheral granulation tissue growth. When this patient was referred to our clinic, rigid bronchoscopy was performed and the bone fragment beneath the granulation tissue was removed (Case No. 8).

Medical history and physical examination are of utmost importance for the diagnosis of foreign body aspiration.^[3] A high index of suspicion by the clinician is also critical. Despite the importance of the aspiration history, it may not always be possible to obtain a clear history from the family or patient.^[15] In a study conducted in our clinic which enrolled 414 foreign body aspiration cases, the history was positive in 88%,^[17] while it was positive in only 63% of the patients in the present series of unusual objects. The history is more likely to be negative in elderly patients. Therefore, clinicians should inquire about aspiration,

when medical histories are obtained from elderly patients.

Another important diagnostic tool is radiology. However, negative chest radiography does not necessarily rule out foreign body aspiration. When X-rays are evaluated in foreign body aspiration cases, no signs are observed in 24 to 30% of the patients.^[3,4] Therefore, bronchoscopy should be performed, if aspiration is suspected. In our study, no pathological findings were noted in seven (36.8%) patients, while the foreign body was directly visualized in six (31.5%) patients and atelectasis, an indirect finding, was also observed in six (31.5%) patients.

The foreign bodies which we identified as being unusual are listed in Table 1. Of these objects, the grass inflorescence was notable in terms of its structure, which caused it to migrate distally. Spontaneous expectoration is rare.^[1,16] In our series, grass inflorescences were spontaneously expectorated in two cases, and the history was negative in both patients; foreign body aspiration was diagnosed several months after the foreign body was aspirated.

The entry route of the foreign body was via a tracheostomy in seven (31.8%) patients: the roll of napkins, piece of wood with one end wrapped in cloth, 11-cm-long construction nail, and voice prosthesis device were removed. Patients with tracheostomy may use various objects to clean, rather than to remove, the cannula. We believe that this behavior is affected by the education level of the patients and advocate that tracheotomized patients should be trained more carefully and clearly informed about how to clean the cannula.

The current therapeutic approach to tracheobronchial foreign body aspiration is rigid bronchoscopy.^[2-4] We performed rigid bronchoscopy

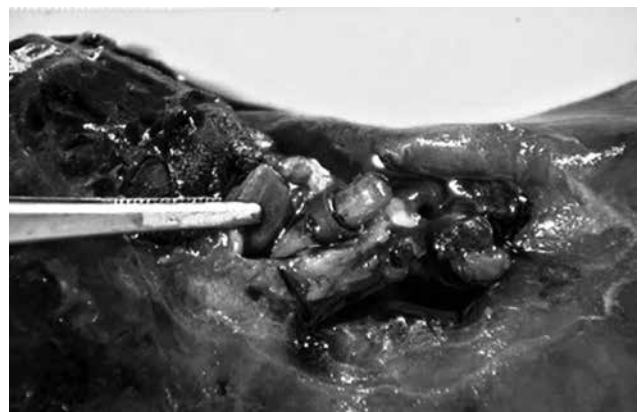

Figure 5. Intraoperative image of the plastic whistle.

in our clinic in 20 (90.9%) of the patients in this series. Removal of the foreign bodies did not cause any complications in these patients, and this complication rate is close to previously reported rates.^[17] Rigid bronchoscopy was unable to be performed in two patients due to spontaneous expectoration of the foreign body. Rigid bronchoscopy alone was insufficient in two patients (9%) due to late admission. The foreign body was removed with thoracotomy plus lobectomy in one patient (Figure 5) and thoracotomy plus pericardiotomy in the other.

In conclusion, in this series of unusual aspirated foreign bodies, the rate of aspiration was higher in the elderly, although a clear history was obtained in fewer patients in this population. Therefore, foreign body aspiration should be considered for elderly patients who present to the emergency service with dyspnea. This series included a number of objects that were used to clean tracheostomy cannulas, likely due to the inadequate training given to tracheotomized patients. Therefore, we believe that these patients should be given more in-depth training.

Declaration of conflicting interests

The authors declared no conflicts of interest with respect to the authorship and/or publication of this article.

Funding

The authors received no financial support for the research and/or authorship of this article.

REFERENCES

1. Yapucu MU, Yazgan S, Gürsoy S, Yıldız S, Ulgan M, Başok O. Pisi pisi otu (Grass Inflorescence) aspirasyonu sonrasında gelişen bronşektazi (dört olgu): pisi pisi otunun sıradışı yolculuğu. *Solunum* 2005;7:70-5.
2. Wei JL, Hollinger LD, Management of foreign bodies of the airway. In: Shields TW, Lo Cicero III J, Ponn RB, Rusch VW, editors. *General Thoracic Surgery*. Chapter 73, 6th ed. Philadelphia: Lippincott Williams & Wilkins; 2005. p. 995-1006.
3. Sayır F, Çobanoğlu U, Sertoğullarından B. Interestingly foreign bodies in esophageal and bronchial system: analysis of 9 cases. *J Clin Anal Med* 2012;3:278-82.
4. Gürsu S, Sırmalı M, Gezer S, Fındık G, Türüt H, Aydın E ve ark. Tracheobronchial foreign body aspirations in adults. *Türk Göğüs Kalp Dama* 2006;14:38-41.
5. Nadir A, Kaptanoğlu M, Şahin E, Acemoğlu M, Akkaş Y. Yabancı cisim aspirasyonu nedeniyle gelişen bronşektazi olgusu. *C. Ü. Tıp Fakültesi Dergisi* 2003;25:75-8.
6. Şahin E, Karadayı Ş, Kaptanoğlu M. Trakeobronşiyal yabancı cisimler. *Türkiye Klinikleri J Thor Surg-Special Topics* 2009;2:32-7.
7. Kaptanoğlu M, Nadir A, Dogan K, Sahin E. The heterodox nature of "Turban Pins" in foreign body aspiration; the central anatolian experience. *Int J Pediatr Otorhinolaryngol* 2007;71:553-8.
8. Sehgal IS, Dhoria S, Ram B, Singh N, Aggarwal AN, Gupta D, et al. Foreign body inhalation in the adult population: experience of 25,998 bronchoscopies and systematic review of the literature. *Respir Care* 2015;60:1438-48.
9. Dogan K, Kaptanoğlu M, Onen A, Saba T. Unusual sites of uncommon endobronchial foreign bodies. Reports of four cases. *Scand Cardiovasc J* 1999;33:309-11.
10. Møller J, Rasmussen F, Hilberg O, Løkke A. Airway foreign body aspiration: common, yet easily overlooked! Two interesting cases. *BMJ Case Rep* 2015;2015. pii: bcr2014209240.
11. Pazarlı CA, Havan AG. Fıstık he zaman lezzetli olmayabilir: İğinc bir aspirasyon. *Türk Toraks Derg* 2014;15:68-70.
12. Yıldızeli B, Yüksel M. Yabancı cisim aspirasyonları. In: Yüksel M, Kaptanoğlu M, editörler. *Pediyatrik Göğüs Cerrahisi*. İstanbul: Turgut Yayıncılık; 2004. s. 151-65.
13. Blair D, Kim R, Mills N, Barber C, Neeff M. A heuristic approach to foreign bodies in the paediatric airway. *Int J Pediatr Otorhinolaryngol* 2014;78:2262-6.
14. Rodríguez H, Cuestas G, Botto H, Nieto M, Cocciaaglia A, Passali D, et al. Complications in children from foreign bodies in the airway. *Acta Otorrinolaringol Esp* 2016;67:93-101.
15. Karadayı Ş, Kaptanoğlu M. Yabancı cisim aspirasyonu. In: Ökten İ, Kavukçu HŞ, editörler. *Göğüs Cerrahisi*. Bölüm 60. 2. Baskı. İstanbul: İstanbul Medikal Sağlık ve Yayıncılık Hiz. Tic. Ltd. Şti.; 2013. s. 859-64.
16. Kazım Çağlar M, Yeginsu A, Ozer I. Chest wall abscess due to aspiration of grass inflorescence. *West Indian Med J* 2007;56:312-4.
17. Oğuzkaya F, Akçali Y, Kahraman C, Bilgin M, Sahin A. Tracheobronchial foreign body aspirations in childhood: a 10-year experience. *Eur J Cardiothorac Surg* 1998;14:388-92.