



Case Report / Olgu Sunumu

A rare case of peripherally located non-bronchial pulmonary mucous gland adenoma

Periferik yerleşimli, bronşiyal olmayan nadir bir pulmoner mukus bezi adenomu olgusu

Ahmet Uluşan¹, Zeynep Bayramoğlu², Maruf Şanlı³, Kemal Bakır⁴

Institution where the research was done:

Medicine Faculty of Gaziantep University, Gaziantep, Turkey

Author Affiliations:

¹Department of Thoracic Surgery, Kahramanmaraş Necip Fazıl City Hospital, Kahramanmaraş, Turkey

²Department of Pathology, Medicine Faculty of Akdeniz University, Antalya, Turkey

³Department of Thoracic Surgery, Medicine Faculty of Gaziantep University, Gaziantep, Turkey

⁴Department of Pathology, Medicine Faculty of Sanko University, Gaziantep, Turkey

ABSTRACT

Pulmonary mucous gland adenomas are rare benign tumors, which need to be differentiated from malign lung masses. The differential diagnosis is of particular importance for those arising from lung parenchyma in atypical locations. In this article, we report a 70-year-old male patient, who had complaints of cough and expectoration for almost two years. Chest computed tomography showed a 1 cm nodule at the left lower lobe of lung. The tumor was totally resected with mini-thoracotomy and wedge resection and sent to the pathology department for a frozen examination. The frozen result was reported as benign. The pathological diagnosis was mucous gland adenoma. The patient had no postoperative complication and made a complete recovery. Pulmonary mucous adenomas may rarely originate from lung parenchyma and be seen in patients with peripherally located lung lesions.

Keywords: Bronchial neoplasms; differential diagnosis; mucinous adenoma surgery; video-assisted thoracic surgery.

ÖZ

Pulmoner mukus bezi adenomları, malign akciğer kitlelerinden ayırıcı tanısı yapılması gereken, nadir görülen benign tümörlerdir. Ayırıcı tanı atipik yerleşimlerde akciğer parankimi kaynaklı olanlar için özellikle önemlidir. Bu yazıda, yaklaşık iki yıldır öksürük ve balgam çıkarma yakınması olan 70 yaşında bir erkek hasta sunuldu. Göğüs bilgisayarlı tomografisinde akciğerin sol alt lobunda 1 cm'lik bir nodül görüldü. Tümör, mini torakotomi ve kama rezeksiyonu ile tamamen rezeke edildi ve frozen incelemesi için patoloji bölümüne gönderildi. Frozen sonucu benign olarak rapor edildi. Patolojik tanı mukus bezi adenomu idi. Hastada ameliyat sonrası komplikasyon gelişmedi ve tam iyileşme sağlandı. Pulmoner mukus adenomları nadiren akciğer parankiminden kaynaklanabilir ve periferik yerleşimli akciğer lezyonları olan hastalarda görülebilir.

Anahtar sözcükler: Bronşiyal neoplaziler; ayırıcı tanı; müsinoz adenoma cerrahisi; video-destekli göğüs cerrahisi.

Pulmonary mucous gland adenoma is a rare benign tumor originating from mucus-secreting cells of bronchi or trachea.^[1] The lesion is generally centrally located due to its bronchial or tracheal origin and hence causes obstruction symptoms. Peripherally located mucous gland adenoma, however, is extremely rare. Non-bronchial pulmonary mucous gland adenomas affecting lung parenchyma have also been rare entities.^[2]

Although benign in nature, pulmonary mucous gland adenomas may induce disturbing signs and symptoms.^[3] Elimination of these symptoms and its differentiation from malign lung cancers have critical importance. It has been reported that pulmonary mucous gland adenoma is generally centrally located because it mostly originates from bronchi or trachea. The differential diagnosis is particularly challenging

Received: September 29, 2017 Accepted: February 19, 2018

Correspondence: Ahmet Uluşan, MD. Kahramanmaraş Necip Fazıl Şehir Hastanesi, Göğüs Cerrahisi Kliniği, 46050 Kahramanmaraş, Turkey.

Tel: +90 364 - 223 03 00 e-mail: draulusan@gmail.com

Cite this article as:

Uluşan A, Bayramoğlu Z, Şanlı M, Bakır K. A rare case of peripherally located non-bronchial pulmonary mucous gland adenoma. Turk Gogus Kalp Dama 2018;26(4):664-667.

©2018 All right reserved by the Turkish Society of Cardiovascular Surgery.

for those arising from lung parenchyma in atypical locations. In this article, we report a rare case of pulmonary mucous gland adenoma, which was non-bronchial and located at the left lower lobe of lung.

CASE REPORT

A 70-year-old male patient was admitted to Thoracic Surgery Clinic in 2013 with complaints of cough and expectoration for almost two years. The patient had no other complaints. He had a history of 30 pack-year smoking and coronary artery disease, but no asbestos exposure. Chest computed tomography (CT) showed a 1 cm nodule in the left lower lobe of lung, which was followed-up periodically with CT (Figure 1a). A written informed consent was obtained from the patient.

One year after the initial assessment, the nodule was measured as 3.5 cm in diameter on chest CT (Figure 1b). F-fluorodeoxyglucose positron emission tomography (FDG-PET) revealed maximum standardized uptake value (SUV) of 2 at nodule on the left lower lobe of lung (Figure 2). Despite the low uptake in PET, we decided to make a resection to confirm the diagnosis of the lesion because the size of the lesion was increasing and based on the information that some lung cancers such as carcinoid tumors had low SUV level despite their malign nature. Surgical resection was applied by video-assisted thoracoscopic surgery (VATS). Since the nodule could not be completely explored with VATS, mini-thoracotomy and wedge resection were performed in the same session. Macroscopically, red-brown lung wedge

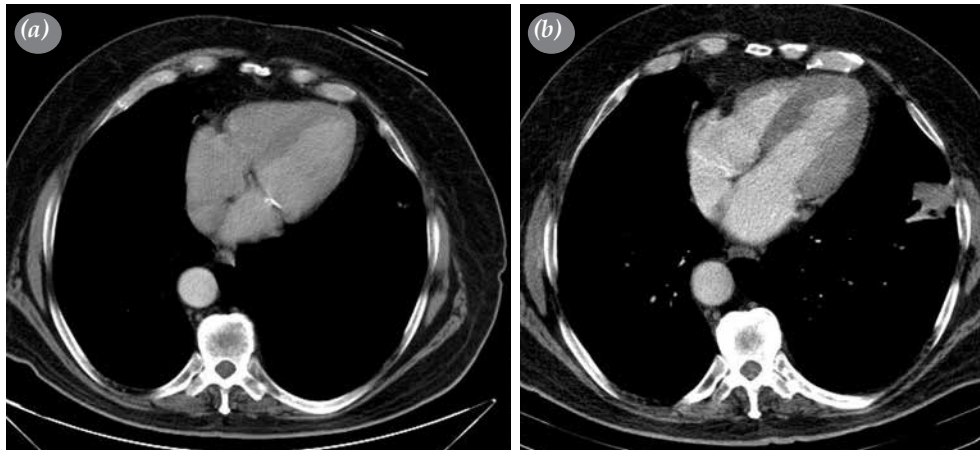


Figure 1. (a) Contrast-enhanced chest computed tomography one year and just before surgery. (b) There was a 1 cm nodule at left lower lobe of lung, which was measured as 3.5 cm in diameter after one year.

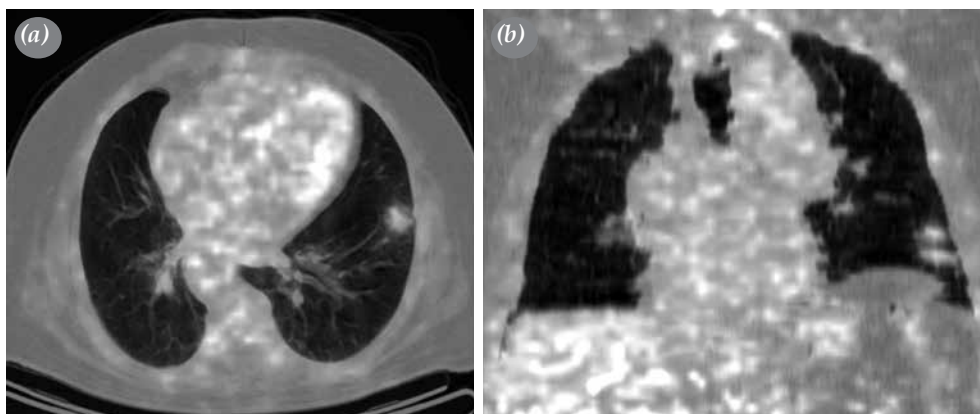


Figure 2. (a, b) Vertical and horizontal images of chest F-fluorodeoxyglucose positron emission tomography showed maximum standardized uptake value of 2 at nodule on left lower lobe of lung.

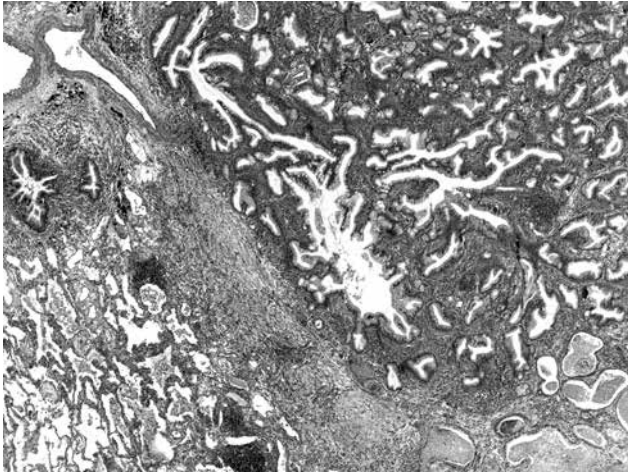


Figure 3. Histological section of tumor tissue showing abundant mucus-filled cystic areas and non-dilated microacinar gland and tubules (H-E \times 4).

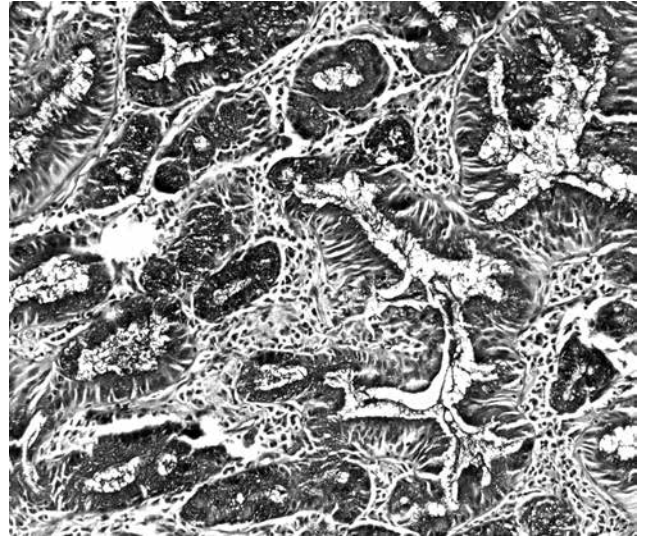


Figure 4. Microscopical image of intraluminal and intracytoplasmic mucus detected histochemically by periodic acid-Schiff-Alcian blue (\times 20).

resection material of 8 \times 2.5 \times 2 cm size was examined with serial sections. In the sections 2.2 \times 1.2 \times 0.8 cm in size, well-limited lesion of yellow and white color was observed. For differential diagnosis, frozen sections of the resection material were sent to pathology where no malignancy was detected. Based on the results of intraoperative pathological evaluation, lobectomy was not performed and surgery was completed.

Pathological evaluation of permanent sections showed abundant mucus-filled cystic areas and non-dilated microacinar gland and tubules (Figure 3). There was neither cytological atypia nor high mitotic activity. The Ki-67 proliferation index was low (maximum 1%). Immunohistochemically, the lesion showed a positive reaction with cytokeratin-7 (CK-7), carcinoembryonic antigen (CEA), epithelial membrane antigen (EMA), and negative reaction with cytokeratin-20 (CK-20), thyroid transcription factor-1 (TTF-1) and caudal type homeobox 2 (CDX2). Intraluminal and intracytoplasmic mucus was detected histochemically by mucicarmine and periodic acid-Schiff-Alcian blue (Figure 4). The pathological diagnosis was mucous gland adenoma. Therefore, no additional surgical intervention was planned. The patient had no postoperative complication and made a complete recovery.

DISCUSSION

Pulmonary mucous adenoma is an extremely rare benign tumor characterized histologically by abundant mucus-filled cystic areas and non-dilated microacinar glands and tubules without atypia or mitoses.^[1] Muller first described this benign tumor in 1882 as a tumoral

lesion separate from carcinoma of the lung. In a retrospective analysis of 1,405 primary pulmonary neoplasms by Takeda et al.,^[4] only one case was diagnosed as mucous gland adenoma.

Due to the rarity of mucous gland adenoma, its clinical characteristics, particularly those with unusual presentations, have not been well-established. The available literature on pulmonary mucous adenoma mainly includes case reports.^[3,4] Most of the cases were located centrally and originated from bronchi. Pulmonary mucous adenoma may cause a variety of respiratory symptoms. Couraud et al.^[3] reported a case of a 54-year-old male patient with symptoms of bronchial obstruction following acute pneumonia. Badyal et al.^[5] recently reported bronchial mucous gland adenoma in the left lower lobe of lung in a 32-year-old female misdiagnosed as tuberculosis for two years.

Mucous gland adenoma presenting as a peripheral lung mass is extremely rare. In the literature, only Karpathiou et al.^[2] and Lee et al.^[6] reported a case of mucous gland adenoma not related with a bronchus, but rather arising from lung parenchyma in a 59-year-old male and 68-year-old female, respectively. Here, we present another case of non-bronchial parenchymal mucous adenoma located peripherally. Our case was a 70-year-old male.

Diagnosis of mucous gland adenoma depends on biopsy. However, CT evaluation reveals signs suggestive of mucous gland adenoma such as

air-meniscus sign or abutting the bronchus, nevertheless, CT is not diagnostic for mucous gland adenomas.^[5] Similarly, on FDG-PET, mucous gland adenoma may mimic lung cancer. Thus, although complete lung workup including CT, bronchoscopy, and FDG-PET is necessary for cases with suspicious pulmonary signs and symptoms, a definite diagnosis of mucous gland adenoma can only be established by pathological evaluation. In our case, we detected the tumor on CT and showed SUV 2 on FDG-PET; however, final diagnosis could only be established by pathological evaluation of surgical resection material. The pathological findings in our case were typical to mucous gland adenoma-- mucus-filled cystic areas and non-dilated microacinar gland and tubules without cytological atypia or mitotic activity, showing immunopositivity for epithelial markers. In a series of 10 cases, England and Hochholzer^[7] reported that mucous gland adenomas show glandular and tubulocystic or papillocystic structure or a mixture of these features. These adenomas are rich in mucins and immunopositive for epithelial markers. The mucous adenomas should be differentiated from low-grade mucoepidermoid carcinoma and mucinous cystadenoma of the lung by not having atypia, necrosis, mitosis and infiltration.^[3]

The only way of treatment is complete surgical resection of the tumor for the best symptomatic relief.^[4] For surgical resection of mucous gland adenoma, bronchoplastic operations are suggested to preserve parenchymal tissue in cases with bronchial adenoma. However, for rare cases of mucous gland adenoma arising from parenchyma-like in the present case-not from bronchi, open surgical interventions are needed for complete resection of the tumor. In the present case, the tumor could not be completely explored with VATS, thus mini-thoracotomy and wedge resection were performed for complete resection of the adenoma. The size of the tumor in the present case (2.2×1.2×0.8 cm) was within the reported range of tumor size in the literature, which was from 0.8 to 6.8 cm. The lesion in our patient grew from 1 cm to 3.5 cm in one year in contrast with benign lesions' usually slow growth rate. The growth rate of

the lesion was too high compared to similar benign lesions in the literature.

In conclusion, although benign in nature, pulmonary mucous adenomas may present with various clinical symptoms and they need to be differentiated from malign pathologies of lung. Although commonly located centrally and originating from bronchial tissue, pulmonary mucous adenomas may rarely originate from lung parenchyma and should be considered for peripherally located lung lesions.

Declaration of conflicting interests

The authors declared no conflicts of interest with respect to the authorship and/or publication of this article.

Funding

The authors received no financial support for the research and/or authorship of this article.

REFERENCES

1. Flieder DB, Thivolet-Bejui F, Popper H. Mucus gland adenoma. In: Travis WD, Brambilla E, Muller-Hermelink HK, Harris CC, editors. Tumours of the lung, pleura, thymus and heart. Lyon: IARC Press; 2004. p. 85-100.
2. Karpathiou G, Sivridis E, Mikroulis D, Froudarakis M, Giatromanolaki A. Pulmonary mucus gland adenomas: are they always of endobronchial localization? *Case Rep Pathol* 2013;2013:239173.
3. Couraud S, Isaac S, Guibert B, Souquet PJ. Bronchial mucous gland adenoma revealed following acute pneumonia. *Interact Cardiovasc Thorac Surg* 2012;14:347-9.
4. Takeda S, Hashimoto T, Kusu T, Kawamura T, Nojiri T, Funakoshi Y, et al. Management and surgical resection for tracheobronchial tumors institutional experience with 12 patients. *Interact Cardiovasc Thorac Surg* 2007;6:484-9.
5. Badyal RK, Kakkar N, Vasishta RK, Mahajan S. Bronchial mucous gland adenoma presenting as massive hemoptysis: A diagnostic dilemma. *Lung India* 2014;31:274-6.
6. Lee B, Choi IH, Han J, Lee KS, Shim YM. An unusual case of pulmonary mucous gland adenoma with fibromyxoid stroma and cartilage islands in 68-year-old woman. *J Pathol* 2014;48:167-9.
7. England DM, Hochholzer L. Truly benign "bronchial adenoma". Report of 10 cases of mucous gland adenoma with immunohistochemical and ultrastructural findings. *Am J Surg Pathol* 1995;19:887-99.