



Case Report / Olgu Sunumu

Fluid inside driveline after left ventricular assist device implantation: A rare case

*Sol ventriküler destek cihazı implantasyonu sonrası driveline içerisinde sıvı birikimi:
Nadir bir olgu*

Tanıl Özer¹, Mustafa Mert Özgür¹, Özge Altaş¹, Davut Çekmecelioğlu¹, Sabit Sarıkaya¹, Kaan Kırallı¹

Department of Cardiovascular Surgery, Kartal Koşuyolu Yüksek İhtisas Training and Research Hospital, Istanbul, Turkey

ABSTRACT

In this article, we present our diagnostic and therapeutic approach in a rare case in whom fluid inside the driveline developed following left ventricular assist device implantation.

Keywords: Driveline, fluid, left ventricular assist device.

ÖZ

Bu yazıda sol ventriküler destek cihazı implantasyonu sonrası driveline içerisinde sıvı birikimi gelişen nadir bir olguda tanı ve tedavi yaklaşımımız sunuldu.

Anahtar sözcükler: Driveline, sıvı, sol ventriküler destek cihazı.

It is well-recognized by many specialists that ventricular assist devices have a noteworthy contribution to the daily living activities of patients with end-stage heart failure.^[1] Additionally, some patients who are supported with these devices get used to living with it and refuse to undergo heart transplantation, which is considered the gold standard destination therapy for these patients. Although these devices provide sufficient effort capacity to patients, some handicaps are still present. Herein, we present our experience in a case who dived with left ventricular assist device (LVAD) for several times and fluid accumulation inside the silicone cover of the driveline developed.

CASE REPORT

A 45-year-old male patient who had a history of continuous flow LVAD (HeartMate II; Thoratec Corp., Pleasanton, CA, USA) implantation three years ago was admitted with a condition of sudden pump stop and pump alarm lasting for a minute at home. When he arrived to the emergency unit, the device was functioning normally. Upon physical examination, he was conscious and oriented, but he was excited, as this was the first time he experienced the pump stop alarm.

His blood pressure was 95/70 mmHg and heart rate was 77 bpm. There was no symptom of low cardiac output syndrome. On echocardiography at emergency unit, aortic valve was opening on each cardiac cycle. The ventricular septum was at the midline with normally functioning and positioned device. There was no sign of device thrombosis. His anticoagulation management was effective. He was using warfarin and acetylsalicylic acid and his international normalized ratio was 2.9. The other routine blood tests were within normal range. After the initial evaluation, the patient was transferred to the inpatient clinic and connected to the backup system controller. There was only one stop alarm recorded before admission to the emergency unit at home. It was decided that the patient would be followed until further diagnosis, while being connected to the backup system controller. After an hour, the pump stopped again, although there was no clinical deterioration and about 30 sec later, the device started to work spontaneously. We connected the patient to a different system controller, but the pump stop occurred while it was on the power module support, and few minutes later, it started to work again. We observed that the frequency of these start and stop

Received: August 16, 2018 Accepted: January 02, 2019 Published online: April 24, 2019

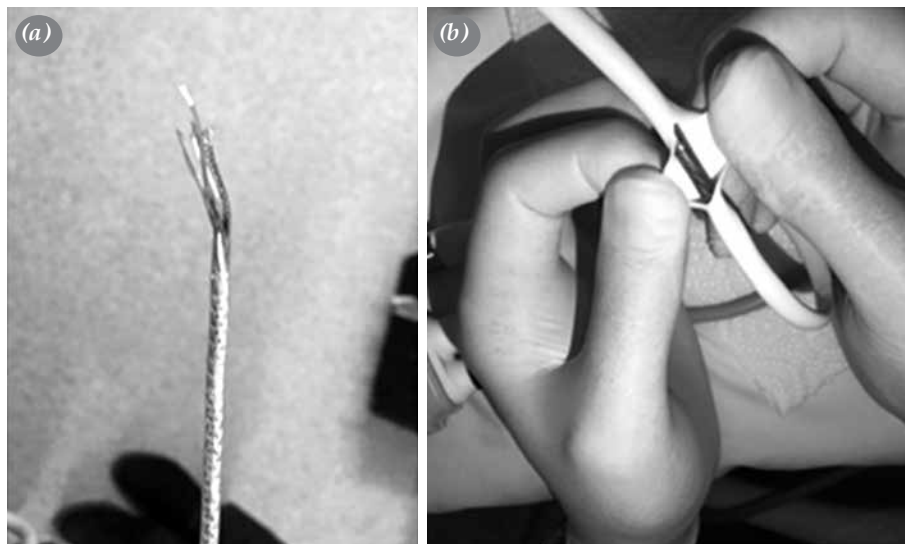
Correspondence: Mustafa Mert Özgür, MD, Kartal Koşuyolu Yüksek İhtisas Eğitim ve Araştırma Hastanesi, Kalp ve Damar Cerrahisi Kliniği, 34865 Cevizli, Kartal, İstanbul, Turkey. Tel: +90 216 - 500 15 00 e-mail: drmertozgur@gmail.com

Cite this article as:

Özer T, Özgür MM, Altaş Ö, Çekmecelioğlu D, Sarıkaya S, Kırallı K. Fluid inside driveline after left ventricular assist device implantation: A rare case. Turk Gogus Kalp Dama 2019;27(2):230-233

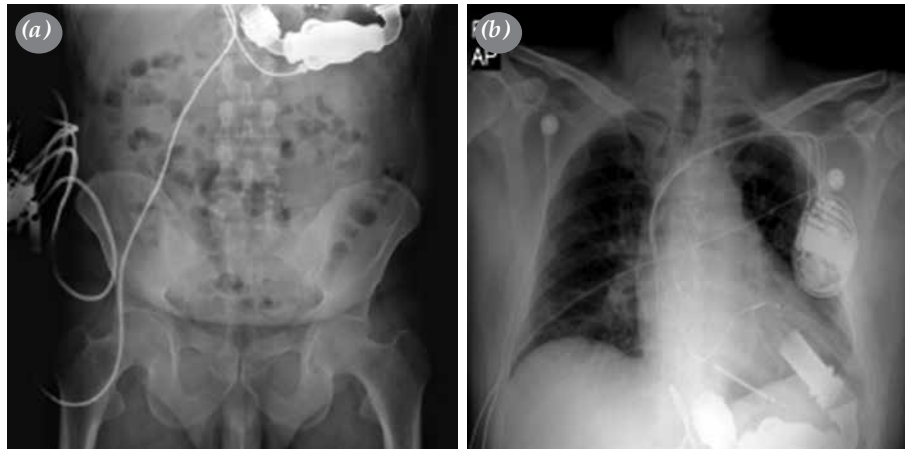

Figure 1. Left and right panels of X-ray showing no visible lesions of driveline and device.



Report Form
Manufacturer's Incident Report
Medical Devices Vigilance System
(MEDDEV 2.12/1 rev 8)

Incident description narrative

The patient was implanted with a HeartMate II Left Ventricular Assist Device (LVAD) on 2014-01-08. It was reported that on 2017-01-09 after approximately 3 years of support, the patient's System Controller suddenly sounded with a Red Heart/Change Controller/Controller Fault alarm at 03:00am and the pump's green "running" symbol was not illuminated during the alarm. At that time the System Controller was connected to battery power. The patient was reportedly responding adequately to questions and did not feel symptomatic during this time. Three minutes after connecting to the back-up System Controller at home, Low Flow alarms occurred. The patient went to the hospital. A third System Controller was connected and immediately a pump stoppage was observed while on Power Module support. Another pump stoppage reportedly occurred on 2017-01-10 after which pump function went back to normal. The patient was placed back on the second System Controller and was issued a non-grounded patient cable for use with the Power Module.

On 2017-01-16, an external driveline evaluation was performed by the manufacturer's Technical Services representatives and fluid was found inside the driveline. It was reported that no further intervention is possible and that the plan is for the patient to receive a heart transplant as soon as possible. No further information was provided. A final report will be submitted when the manufacturer's investigation is completed.

Figure 2. (a) Showing original view of cables after silicone cuff removed, (b) showing green-color and lubricated view of cables after technical service cut the silicone cuff, and (c) showing official report of manufacturers' technical staff.

periods increased with the body movements of the patient and while he was lying on his left side, the pump stop periods were seen less often. We considered that some body movements might cause electrical loss of contact between any part along the electrical system of the driveline. This stop and start periods occurred several times during follow-up. Chest and abdominal X-ray and computed tomography findings were normal and no lesion or break through the driveline and no visual abnormality of the device itself (Figure 1) was observed. A few days later, authorized staff arrived from the manufacturer's technical service to the hospital and checked the device and connecting systems and decided to dissect the silicone cuff of the driveline. When they dissected the silicone cuff of the driveline, they found fluid inside the driveline and reported to us that it was technically not possible to fix this problem (Figure 2). When we re-evaluated the patient's history, we found out that he died several times in a special outfit that he designed without our permission. We performed echocardiography, when the pump was stopped. Ejection fraction was 20% and left ventricular end-diastolic diameter was found to be 6.7 cm. Therefore, with these poor ventricular functions, the device removal would not have been the appropriate approach. The patient was informed about the two possible interventions: first was heart transplantation as soon as possible and the latter one was the exchange of the device. The patient's primary preference was heart transplantation. It was decided to take the patient on urgent transplantation list and two weeks later, the patient underwent a heart transplant.

DISCUSSION

There are many reports in the literature about pump dysfunction and driveline fracture, although there are no reports about lubrication or fluid accumulation inside the driveline.^[2-4] Today, the main approach for the treatment of driveline fracture is to change the device or perform heart transplantation.^[5] Therefore, if we knew any other possible solution to repair the damaged part of the driveline, the patient would not

have been operated again and would have been treated more favorably.

Currently, most of patients with end-stage heart failure may have dramatic improvement in their exercise capacity after LVAD support. In some occasions, patients may prefer LVAD implantation to heart transplantation or cannot receive heart transplant for specific reasons. Conditions such as swimming, diving, and similar hobbies are harmful for patients under LVAD support. On the other hand, these devices still have technical difficulties which complicate the quality of life of patients. Special clothes or bags should be manufactured to overcome these undesired conditions.

In conclusion, as these complicative issues are resolved, mechanical support devices may get one step closer to replacing heart transplantation.

Declaration of conflicting interests

The authors declared no conflicts of interest with respect to the authorship and/or publication of this article.

Funding

The authors received no financial support for the research and/or authorship of this article.

REFERENCES

1. Slaughter MS, Pagani FD, Rogers JG, Miller LW, Sun B, Russell SD, et al. Clinical management of continuous-flow left ventricular assist devices in advanced heart failure. *J Heart Lung Transplant* 2010;29:S1-S39.
2. Loforte A, Della Monica PL, Musumeci F. A unique case of driveline fracture in a continuous-flow mechanical support device. *J Heart Lung Transplant* 2011;30:967-8.
3. Stulak JM, Schettle S, Haglund N, Dunlay S, Cowger J, Shah P, et al. Percutaneous Driveline fracture after implantation of the HeartMate II left ventricular assist device: How durable is driveline repair? *ASAIO J* 2017;63:542-5.
4. Schima H, Stoiber M, Schlöglhofer T, Hartner Z, Haberl T, Zimpfer D. Repair of left ventricular assist device driveline damage directly at the transcutaneous exit site. *Artif Organs* 2014;38:422-5.
5. Gregoric ID. Exchange techniques for implantable ventricular assist devices. *ASAIO J*. 2008;54:14-9.

EDITORIAL COMMENT

Mehmet Hakan Akay

The short-to-shield phenomenon is a very unique driveline dysfunction observed in HeartMate II left ventricular assist device (LVAD) patients. Disruption of the driveline wiring results in pump stoppage which

could be fatal, if not recognized and appropriately managed in a timely manner. The pump stoppage-related pump thrombosis or severe regurgitation through the outflow graft and pump into the left

ventricle would deteriorate hemodynamic status of the patient. In a retrospective analysis of patients who underwent HeartMate II LVAD placement at our institution, there were 14 patients who had short-to-shield phenomenon. At our institution, any patients who are suspected to have this phenomenon are immediately called and admitted to our hospital. The manufacturer of the device is also notified immediately and the engineers from the manufacturing company arrive at our institution to perform subsequent analysis. During this analysis, they evaluated the driveline and fixed the issue once recognized. If driveline cannot be repaired from skin level and out, then an immediate pump exchange is performed via subcostal incision with cardiopulmonary bypass or by off-pump approach.^[1,2] There are few reports of heart transplantation from other centers who have the ability to get a donor heart in a week or two, since with ground connected the pump does not have

short-to-shield; however, we do not have that short waiting time and we favor pump exchange in these patients. Additionally, at our institution, we are very stringent in our pre-LVAD criteria and ensure that the patient and the family adhere to our center's pre-and-post implantation guidelines. Such contracts allow us to ensure compliance on the patient's part.

REFERENCES

1. Jafar M, Gregoric ID, Radovancevic R, Cohn WE, McGuire N, Frazier OH. Urgent exchange of a HeartMate II left ventricular assist device after percutaneous lead fracture. *ASAIO J* 2009;55:523-4.
2. Cohn WE, Mallidi HR, Frazier OH. Safe, effective off-pump sternal sparing approach for HeartMate II exchange. *Ann Thorac Surg* 2013;96:2259-61.

Correspondence: Mehmet Hakan Akay, MD. UT Health, ACTAT, Houston, USA.

Tel: 7134866738 e-mail: mehmet.h.akay@uth.tmc.edu