



The results of interventional catheterization in infants weighing under 2,000 g

2000 g altında ağırlığı olan bebeklerde girişimsel kateterizasyon sonuçları

Birgül Varan¹, N. Kürşad Tokel¹, Kahraman Yakut¹, İlkay Erdoğan¹, Murat Özkan²

¹Department of Pediatric Cardiology, Başkent University Faculty of Medicine, Ankara, Turkey

²Department of Cardiovascular Surgery, Başkent University Faculty of Medicine, Ankara, Turkey

ABSTRACT

Background: The aim of this study was to evaluate the early and mid-term results of interventional cardiac catheterization and procedure-related complications in infants weighing <2,000 g.

Methods: Between May 1998 and April 2017, 22 patients (14 males, 8 females; mean age 14±8.4 days; range, 1 to 30 days) weighing <2,000 g who underwent a total of 23 interventional cardiac catheterization were retrospectively analyzed. Procedures were balloon coarctation angioplasty in 14, balloon atrial septostomy in five, balloon aortic valvuloplasty in one, balloon pulmonary valvuloplasty in one, patent ductus arteriosus closure in one, and stent placement in the ductus in one patient. Another patient underwent balloon coarctation angioplasty and balloon aortic valvuloplasty in the same session.

Results: The overall success rate of the interventional procedures was 95.6%. The mean follow-up was 3.2±1.6 years (range, 1 to 5.5) for 18 patients with available records. The rate of serious complications was 18%. The most frequent complications in the early period were low hemoglobin levels requiring erythrocyte suspension transfusion (54.5%) and vascular injury (54.5%). Two patients required reintervention, one patient required surgery after the second intervention, and three patients required only surgery. Six patients underwent palliative interventional procedures, and interventional procedures led to definitive treatment in five patients.

Conclusion: The mortality and morbidity rate of surgery is high in premature under 2,000 g infants and interventional heart catheterization can be life-saving in this patient group, although it is associated with significant complications in low birth weight newborns.

Keywords: Complication, congenital heart disease, interventional cardiac catheterization, low birth weight, prematurity.

ÖZ

Amaç: Bu çalışmada <2000 g ağırlığındaki bebeklerde girişimsel kalp kateterizasyonunun erken ve orta dönem sonuçları ve işleme bağlı komplikasyonlar değerlendirildi.

Çalışma planı: Mayıs 1998 - Nisan 2017 tarihleri arasında 23 girişimsel kalp kateterizasyonu yapılan ağırlığı 2000 g altındaki 22 hasta (14 erkek, 8 kız; ort. yaş 14±8.4 gün; dağılım 1-30 gün) retrospektif olarak incelendi. Hastaların 14'üne balon koarktasyon anjiyoplasti, beşine balon atriyal septostomi, birine balon aortik valvüloplastisi, birine balon pulmoner valvüloplastisi, birine patent duktus arteriozozus kapatılması ve birine duktusa stent yerleştirilme işlemi uygulandı. Bir başka hastaya da aynı seansta balon koarktasyon anjiyoplastisi ve balon aortik valvüloplastisi yapıldı.

Bulgular: Girişimsel işlemlerin genel başarı oranı %95.6 idi. Kayıtlarına ulaşılan 18 hastanın ortalama takip süresi 3.2±1.6 (dağılım, 1-5.5) yıl idi. Ciddi komplikasyon oranı %18 idi. Erken dönemde en sık görülen komplikasyonlar eritrosit süspansiyonu transfüzyonu gerektirecek hemoglobin düşüklüğü (%54.5) ve damar yaralanması (%54.5) idi. İki hastaya yeniden işlem gerekli oldu; bir hastaya ikinci girişim sonrasında cerrahi yapılması gerekti ve üç hastaya yalnızca cerrahi uygulandı. Altı hastaya palyatif amaçlı girişimsel işlem yapıldı ve beş hastada girişimsel işlemler kesin tedavi sağlamıştı.

Sonuç: 2000 g altındaki bebeklerde cerrahinin mortalite ve morbidite oranı yüksek olup, düşük doğum ağırlıklı yenidoğanlarda önemli komplikasyonlar ile ilişkili olsa da, bu hasta grubunda girişimsel kalp kateterizasyonu hayat kurtarıcı olabilir.

Anahtar sözcükler: Komplikasyon, doğuştan kalp hastalığı, girişimsel kalp kateterizasyonu, düşük doğum ağırlığı, prematürite.

Received: September 13, 2018 Accepted: March 10, 2019 Published online: June 21, 2019

Correspondence: Birgül Varan, MD. Başkent Üniversitesi Tıp Fakültesi Çocuk Kardiyolojisi Bilim Dalı, 06490 Bahçelievler, Ankara, Turkey.
Tel: +90 312 - 203 68 68 / 1382 e-mail: birgulv@hotmail.com

Cite this article as:

Varan B, Tokel NK, Yakut K, Erdoğan İ, Özkan M. The results of interventional catheterization in infants weighing under 2,000 g. Turk Gogus Kalp Dama 2019;27(3):304-313

Technological advances in medicine have favorably affected the survival rates of infants with low birth weight (LBW) which, in turn, have increased the need for interventional cardiac procedures. The risk of LBW is slightly higher in infants with congenital heart disease (CHD).^[1] The high risk of mortality and morbidity in palliative or definitive surgical procedures in infants with CHD and LBW have created a need for catheterization-based interventions. Although surgery is the treatment of choice for aortic coarctation and patent ductus arteriosus (PDA), it has high mortality and morbidity in LBW newborns.^[2] Therefore, balloon angioplasty of coarctation is used to delay surgery in these vulnerable patients. Balloon atrial septostomy is life-saving in some congenital heart defects, particularly in transposition of great arteries, while balloon aortic valvuloplasty and pulmonary balloon valvuloplasty can relieve obstruction without a need for surgery.

In the present study, we aimed to evaluate the early and mid-term results of interventional cardiac catheterization and procedure-related complications in infants weighing <2,000 g.

PATIENTS AND METHODS

Between May 1998 and April 2017, 22 patients (14 males, 8 females; mean age 14 ± 8.4 days; range, 1 to 30 days) weighing <2,000 g who underwent a total of 23 interventional cardiac catheterization were retrospectively analyzed. Data including cardiac findings, catheterization results, and early and mid-term complications were recorded. A written informed consent was obtained from each parent. The study protocol was approved by the institutional Ethics Committee of Baškent University Faculty of Medicine (KA17/229-12.09.2017). The study was conducted in accordance with the principles of the Declaration of Helsinki.

The patients were classified according to the type of interventions. The smallest possible sheaths were chosen for the catheters to be used during the procedure. The sheath sizes of 4-French (Fr) and 5-Fr were chosen depending on the balloon catheters used, and none of the procedures were performed sheathless. During the interventional procedures, all infants were placed under radiant warmers and their skin temperatures were recorded using a skin probe.

Operative technique

Balloon coarctation angioplasty was performed using balloons with a balloon diameter-to-diaphragmatic aorta ratio ≤ 1 and/or balloon-to-

coarctation diameter ratio ≤ 3 . The success criteria for balloon coarctation angioplasty were systolic gradient <20 mmHg, and a 50% increase in diameter of the stenotic region.^[3-5] All patients were administered general and local anesthesia during balloon coarctation angioplasty procedure. General anesthesia was achieved with intravenous ketamine (2-5 mg/kg) and local anesthesia with prilocaine hydrochloride (1-4 mg/kg) was administered to the operative field. Ten patients were accessed via femoral artery (retrograde) and four patients via femoral vein (anterograde) (via atrial septal defect [ASD]/patent foramen ovale [PFO] in one patient and via ventricular septal defect [VSD] in three patients) for the procedure. Contrast material was injected into the aorta and angiographic views were taken in the anteroposterior and lateral views before and after the procedure. As the patients were small, manual contrast injection was preferred. Systolic, diastolic, and mean pressures were measured in the ascending and descending aorta before and after the procedure in all patients. The balloon was inflated for five to six sec for one to three times under fluoroscopy, until the indentation at the stenotic segment was eliminated. The procedures considered unsuccessful according to the prespecified criteria were repeated using a 1 to 2-mm larger balloon not exceeding the diameter of the descending aorta at the level of diaphragma.

A balloon-to-annulus ratio of 0.8 to 1 was used for aortic valvuloplasty, and a balloon-to-annulus ratio of 1 to 1.4 was used for pulmonary valvuloplasty. The procedural success criteria for aortic valvuloplasty were 40% reduction in systolic pressure gradient, gradient <50 mmHg in patients with normal cardiac output, reduced left ventricle end-diastolic pressure, increased forward flow from the valve, and termination of prostaglandin treatment or inotropic support.^[6-8] The procedural success criteria for balloon pulmonary valvuloplasty were reduced right ventricle-to-left ventricle systolic pressure ratio below 0.5, increased forward flow in the valve, or the termination of prostaglandin treatment.^[9-11] The procedural success criteria for balloon atrial septostomy were reduced pressure difference on the atrial septum, increased oxygen saturation, or the demonstration of increased flow through the atrial septum by echocardiography. A VSD was present in four of five patients who underwent balloon atrial septostomy. One patient had a small perimembranous outlet VSD; one had a small midmuscular VSD; and two had small apical VSDs. Among these patients, the one with a small perimembranous outlet VSD was receiving ventilatory support and had an oxygen saturation below 60% and

metabolic acidosis, while receiving prostaglandin E1. The other three patients had also small VSDs and an oxygen saturation below 65%, while receiving prostaglandin E1. As they were clinically unstable, insufficient mixture through VSD and PFO was considered and septostomy was performed. All patients were accessed via femoral vein using a 5-Fr sheath. Septostomy procedure was performed using a 1 mL balloon septostomy catheter (NuMED, Canada Inc., Ontario, Canada).

Intravenous heparin (100 U/kg) was administered to the patients after sheath insertion to the femoral artery. In case of prolonged interventional procedures, intravenous heparin dose was repeated as 50 U/kg. Heparin was rarely used in right cardiac catheterization. In all patients with sheath insertion in the femoral artery, heparin infusion continued at the dose of 20 U/kg/h for at least six hours. Active partial thromboplastin time was used to monitor the anticoagulant effect and bleeding risk. Heparin was used as an anticoagulant to treat the patients who had impaired blood flow in the extremities after venous intervention. Streptokinase infusion was initiated in the patients with absent femoral pulse, despite six-hour heparin infusion. The loading dose of heparin was 50 U/kg (intravenous), and the maintenance dose was 20 U/kg/h. For streptokinase, the intravenous loading dose was 3,000 U/kg, and the maintenance dose was 1,500 to 2,000 U/kg/h. Transfontanellar ultrasonography was performed before and after the treatment to all patients who received streptokinase. During heparinization, active partial thromboplastin time value was kept between 60 and 80 sec. If the fibrinogen level fell below 100 mg/dL after streptokinase treatment, the patients were administered fresh frozen plasma (fresh frozen plasma; 10 mL/kg). The patients with absent pulse and/or impaired blood flow in the extremities underwent Doppler ultrasonography.

Major complications were defined as cardiac arrest, mortality, severe vascular injury to cause gangrene or compartment syndrome in the extremities, cardiac perforation, arrhythmia, atrioventricular block, and severe blood loss which could lead to hemodynamic changes.

Statistical analysis

Statistical analysis was performed using the PASW version 17.0 software (SPSS Inc., Chicago, IL, USA). Descriptive statistics were expressed in mean \pm standard deviation (SD), median (min-max), or number and frequency. Chi-square test was used to

compare the categorical variables. A *p* value less than 0.05 was considered statistically significant.

RESULTS

The mean gestational age of the patients was 32.9 ± 2.8 (range, 28 to 39) weeks and the mean body weight was 1.7 ± 0.3 (range, 1 to 2) kg. Fourteen patients underwent balloon coarctation angioplasty, five balloon atrial septostomy, one balloon aortic valvuloplasty, one balloon pulmonary valvuloplasty, one PDA closure, and one stent placement in the ductus. Balloon angioplasty of coarctation and balloon aortic valvuloplasty was performed at the same session to one patient with borderline left ventricle; however, this case underwent Norwood procedure at the age of 2.5 months, as the left ventricle did not develop enough to be adequate for biventricular repair. During PDA closure, the Amplatzer Duct Occluder II device (St. Jude Medical, St. Paul, MN, USA), which was placed in the duct, led to pulmonary artery obstruction and severe pulmonary regurgitation, and, therefore, it was retrieved and PDA was closed surgically. A 1.5-kg infant who had severe valvular aortic stenosis, unicuspid aortic valve, aortic coarctation, mitral valve hypoplasia, ASD, PDA, and borderline left ventricular hypoplasia underwent balloon aortic valvuloplasty and balloon coarctation angioplasty in the same session. Further follow-up showed failure of the left ventricle development, and the patient underwent Norwood surgery after reaching 2,000 g of body weight. Balloon coarctation angioplasty was repeated in three of 14 patients who underwent balloon coarctation angioplasty. Two patients underwent only surgical repair of coarctation. In one patient, the balloon coarctation angioplasty procedure was repeated first, followed by a surgical repair. Three patients who underwent balloon coarctation angioplasty were followed for a mean duration of 3.6 (range, 2.5 to 5.5) years. A seven-month old infant who underwent balloon coarctation angioplasty was operated for comorbid VSD and later died, and three patients were lost-to-follow-up after the procedure. During the first 72 hours, 11 patients received anticoagulant treatment. Bleeding with anticoagulant treatment was not observed in any of the patients. Patient characteristics and interventions are shown in Table 1.

Arterial access was obtained in 11 patients, venous access was obtained in nine patients, and both were obtained in two patients. The sheaths were chosen at a size of 4-Fr or 5-Fr depending on the balloon catheters used and no procedure was performed sheathless. There was no significant difference between the sheath sizes

Table 1. Clinical characteristics of patients and cardiac interventions

Diagnoses	GA (week)	Weight (kg)	Age (day)	Intervention	GPI (mmHg)	GAI (mmHg)	Reintervention (day)	Surgery timing (month)	Follow-up time (year)	Outcome
CoA	30	1.3	17	BCA	41	20	-	-	2.5	Alive
CoA	32	1.3	15	BCA	36	11	-	-	3	Alive
CoA	34	1.4	14	BCA	44	12	-	CoA-R 3	4	Alive
CoA	32	1.5	22	BCA	70	4	-	-	5.5	Alive
TGA, VSD, CoA, ASD	32	1.8	6	BCA	12	4	-	-	-	Death
CAVSD, CoA	39	1.7	11	BCA	12	7	-	-	-	No follow-up
CoA, PDA, ASD	36	2	16	BCA	91	10	-	-	-	No follow-up
CoA, PDA, LVSD	32	1	1	BCA	20	8	-	-	-	Death
VSD, CoA, PDA, ASD	35	1.8	21	BCA	37	14	BCA 60	VSD-R 6	2	Alive
VSD, CoA	33	1.3	12	BCA	18	5	BCA 60	CoA-R 6	1	Alive
VSD, CoA	34	1.7	7	BCA	34	7	BCA 45	VSD-R 7	-	Death
VSD, CoA	33	1.8	14	BCA	43	18	-	VSD-CoA-R 6	5	Alive
VSD, CoA	32	1.5	26	BCA	74	19	-	-	-	No follow-up
HLHS, CoA, AS	28	1.5	21	BCA, BAV	15	1	-	Norwood 2.5	-	Death
PS	29	2	30	BPV	87	42	-	-	1	Alive
TGA, VSD	35	1.8	3	BAS	-	-	-	-	-	No follow-up
TGA	31	1.5	4	BAS	-	-	-	ASO-VSD-R 2.5	2.5	Alive
TGA, VSD	33	1.8	6	BAS	-	-	-	Senning 5.5	3.5	Alive
TGA, VSD	36	1.5	1	BAS	-	-	-	ASO-VSD-R 1	-	Death
TGA, VSD	30	2	21	BAS	-	-	-	ASO-VSD-R 1.5	-	Death
VSD, PA	38	1.9	15	Ductal-stent	-	-	-	-	-	Death
PDA	30	2	25	PDA-closure	-	-	-	PDA-L 1	5	Alive

GA: Gestational age; GPI: Gradient pre-intervention; GAI: Gradient after intervention; BCA: Balloon coarctation angioplasty; CoA: Coarctation of the aorta; R: Repair; TGA: Transposition of great arteries; VSD: Ventricular septal defect; ASD: Atrial septal defect; CAVSD: Complete atrioventricular septal defect; PDA: Patent ductus arteriosus; LVSD: Left ventricle systolic dysfunction; HLHS: Hypoplastic left heart syndrome; AS: Aortic stenosis; BAV: Balloon aortic valvuloplasty; PS: Pulmonary stenosis; BPV: Balloon pulmonary valvuloplasty; BAS: Balloon atrial septostomy; ASO: Arterial switch operation; L: Ligament, PA: Pulmonary atresia.

Table 2. Technical details and complications

Diagnoses	GA (week)	BW (kg)	Age (day)	Interventions	Access	Sheath	Complications	PI-Hg	AI-Hg	Transfusions	Anticoagulant	VAT
CoA	30	1.3	17	BCA	RFA	4 F	VI	13	10	ES	Hep	Open
CoA	32	1.3	15	BCA	RFA	4 F	VI	13	8.8	ES, FFP	Hep, Strep	Blocked
CoA	34	1.4	14	BCA	LFA	4 F	VI	9.6	6.6	ES	Hep	Open
CoA	32	1.5	22	BCA	RFA	4 F	VI	12.3	8.4	ES	Hep	Open
TGA, VSD, CoA, ASD	32	1.8	6	BCA	LFV	4 F	CA	15.5	10.5	ES, FFP	-	Open
CAVSD, CoA	39	1.7	11	BCA	RFA, LFV	4 F, 5 F	VI	12	8.5	ES, FFP	Hep	Open
CoA, PDA, ASD	36	2	16	BCA	RFV	5 F	-	16	12.6	-	-	Open
CoA, PDA, LVSD	32	1	1	BCA	LFA	4 F	VI, PGPVS	15	9.2	ES, FFP	-	Blocked
VSD, CoA, PDA, ASD	35	1.8	21	BCA	RFV	4 F	-	15	14	-	-	Open
VSD, CoA	33	1.3	12	BCA	RFA	4 F	-	13	11	-	-	Open
VSD, CoA	34	1.7	7	BCA	LFA	4 F	VI	12	11	ES	Hep	Open
VSD, CoA	33	1.8	14	BCA	RFA	4 F	VI	15	12.4	-	-	Open
VSD, CoA	32	1.5	26	BCA	RFA	4 F	VI	13	11.5	FFP	Hep, Strep	Open
HLHS, CoA, AS	28	1.5	21	BCA, BAV	RFA	4 F	VI, TRD	12	8.6	ES, FFP	Hep, Strep	Open
PS	29	2	30	BPV	RFV	5 F	-	12.1	11.5	-	-	Open
TGA, VSD	35	1.8	3	BAS	RFV	5 F	-	14.5	13.5	-	-	Open
TGA	31	1.5	4	BAS	RFV	5 F	-	16	14	FFP	-	Open
TGA, VSD	33	1.8	6	BAS	RFV	5 F	-	18.5	17.6	-	-	Open
TGA, VSD	36	1.5	1	BAS	RFV	5 F	-	12.5	11	-	-	Open
TGA, VSD	30	2	21	BAS	RFV	5 F	VI	16	10.5	ES, FFP	Hep	Open
VSD, PA	38	1.9	15	Ductal-stent	RFV	5 F	VI	13.1	8.5	ES, FFP	Hep, Strep	Blocked
PDA	30	2	25	PDA-closure	RFA, LFV	4 F, 5 F	PR, PAS	12.6	8.4	ES	-	Open

GA: Gestational age; BW: Bodyweight; PI-Hg: Pre-intervention hemoglobin; AI-Hg: hemoglobin after intervention; VAT: Vessels after treatment; CoA: Coarctation of the aorta; BCA: Balloon coarctation angioplasty; RFA: Right femoral artery; LFA: Left femoral artery; VI: Vascular injury; ES: Erythrocyte suspension; Hep: Heparin; Strep: Streptokinase; FFP: Fresh frozen plasma; TGA: Transposition of great arteries; VSD: Ventricular septal defect; LFV: Left femoral vein; CA: Cardiac arrest; CAVSD: Complete atrioventricular septal defect; RFV: Right femoral vein; PDA: Patent ductus arteriosus; LVSD: Left ventricle systolic dysfunction; PGPVS: Presence of gas in the portal venous system; HLHS: Hypoplastic left heart syndrome; AS: Aortic stenosis; BAV: Balloon aortic valvuloplasty; TRD: Transient respiratory depression; PS: Pulmonary stenosis; BPV: Balloon pulmonary valvuloplasty; BAS: Balloon atrial septostomy; PA: Pulmonary atresia; PR: Pulmonary regurgitation; PAS: Pulmonary artery stenosis.

with respect to the rate of arterial or venous stenosis. The loss of pulse in the extremities was observed in 10 of 13 patients who underwent arterial intervention and in two of 12 patients with venous access. Seven of 12 patients with pulse loss received heparin, whereas four received heparin and streptokinase. Pulse was restored in five of seven patients who received heparin and in one of four patients who received heparin and streptokinase. Doppler ultrasonography showed intact vessels in these six patients. One patient with pulse loss was not given anticoagulant treatment due to the risk of bleeding. Severe vascular injury such as extremity gangrene or compartment syndrome did not develop in the patients with pulse loss and major limb problems were not seen in any of them. Technical details and complications are shown in Table 2.

Complications were observed in 63.4% of the infants. The most frequent complications in the early period were low hemoglobin levels requiring erythrocyte suspension transfusion (54.5%) and vascular injury (54.5%). The rate of serious complications was 18% (n=4). Transient respiratory depression which did not cause bradycardia was observed in one case, and the patient was intubated and the procedure continued. In another case, cardiac arrest occurred during the procedure, and the procedure continued following a brief period of cardiac massage and respiratory

support. One patient with poor condition and impaired kidney function who underwent balloon coarctation angioplasty had ultrasonographic examination for abdominal distention which showed gaseous distention and pneumobilia in the hepatic left lobe and portal venous system. The patient's left ventricular systolic function and kidney function did not improve. Ten days after the interventional catheterization, the patient died in the intensive care unit (ICU) due to severe sepsis and multiorgan failure. Another important complication was stenosis in the pulmonary artery and severe pulmonary regurgitation during PDA closure. No permanent damage or mortality was observed during the procedures.

The mid-term follow-up results of 18 patients (81%) were available. The mean follow-up for these patients was 3.2 ± 1.6 (range, 1 to 5.5) years. Eighteen of 22 patients (81%) who underwent interventional catheterization were discharged from the hospital. Three of four patients who were not discharged from the hospital died due to low cardiac output, multiple organ failure, and severe sepsis (independent of the catheterization procedure) and another patient died due to cardiac failure after arterial switch surgery. Seven of 18 patients (38%) who were followed in our clinic died. Four of them died after surgery and three died during follow-up. There is no information about their outcome

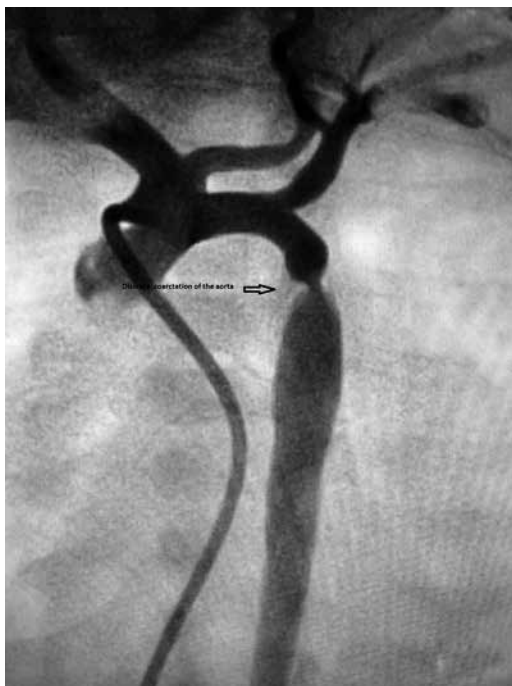


Figure 1. Discrete aortic coarctation in a premature infant.

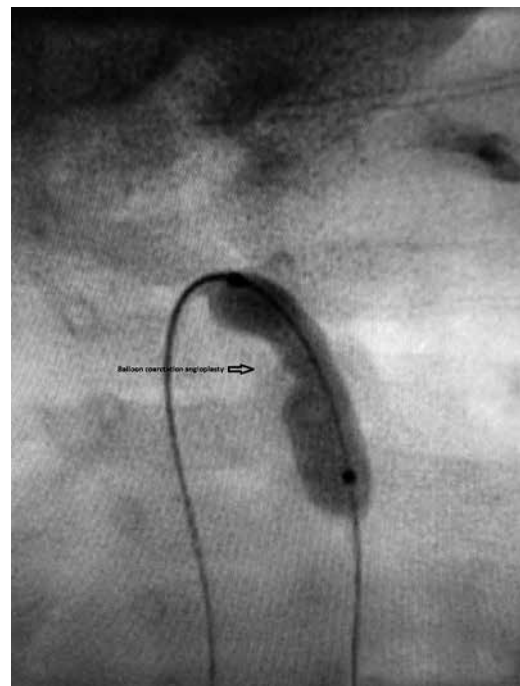


Figure 2. Balloon coarctation angioplasty in discrete aortic coarctation.

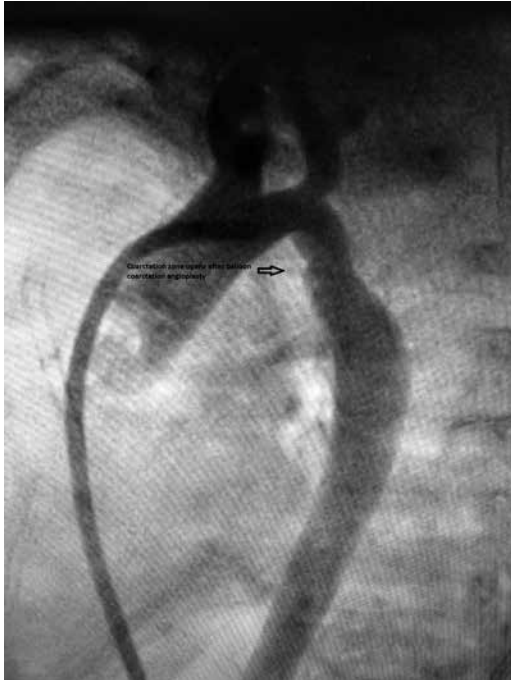

Figure 3. Coarctation zone patent after balloon coarctation angioplasty.

as they did not come for follow-up after discharge from the hospital. Three of 14 patients who underwent balloon coarctation angioplasty have been followed for a mean duration of 3.7 ± 1.6 (range, 2.5 to 5.5) years without reintervention (Figures 1, 2, 3). The balloon coarctation angioplasty procedure was repeated in three patients, surgical repair was performed in one patient due to recoarctation, and seven months later, one patient died in the ICU after VSD operation. Two patients underwent only surgical repair due to recoarctation. A 2.5-month infant who underwent balloon coarctation angioplasty died after the Norwood surgery due to hypoplastic left heart syndrome; an 18-day-old infant who had comorbid CHDs (i.e., transposition of the great arteries, VSD, ASD, and coarctation of the aorta) died without any surgical intervention; a 12-day-old infant who had coarctation of the aorta, PDA, and severe left ventricle systolic dysfunction died in the ICU due to severe sepsis and multiple organ failure. Three patients who underwent balloon coarctation angioplasty were lost-to-follow-up.

Arterial switch operation was performed in three of five patients who underwent balloon atrial septostomy; two of them died in the ICU after arterial switch operation, whereas one patient is still under follow-up for two years. One patient underwent the Senning procedure and is currently uneventful. One patient

who underwent balloon atrial septostomy died in the second month in another center due to severe sepsis and multiple organ failure without any surgical intervention.

One patient who was diagnosed with VSD and pulmonary atresia underwent stent placement in atypical patent duct and died on postoperative Day 3 due to sudden cardiac arrest.

During the PDA closure, the Amplatzer Duct Occluder II device, which was placed in the duct, led to pulmonary artery occlusion and severe pulmonary regurgitation and it was, then, removed and PDA was closed surgically. The patient has been followed for 4.5 years.

A patient who underwent balloon pulmonary valvuloplasty due to valvular pulmonary stenosis is still under follow-up without any further intervention.

DISCUSSION

Interventional cardiac procedures in infants with LBW have become relatively easier due to the technical advances, the development of low profile equipment, and advances in catheter types. Despite the increasing success rates of surgical procedures in infants with CHD who have LBW, the morbidity and mortality rates are still high.^[12-15] Due to the availability of interventional cardiac procedures, these infants are provided with palliation, until they reach a bodyweight that is suitable for a more successful surgery. In our series, the smallest possible sheaths were preferred depending on the catheters to be used during the interventional procedures. As the study was long-term, there were some progresses in the technical equipment such as lower profile catheters and wires.

In the present study, the most frequent interventional cardiac procedure was balloon coarctation angioplasty (60%). In our routine practice, surgery is the treatment of choice of our clinic for aortic coarctation, as it is recommended; however, in this study, balloon coarctation was performed to LBW newborns with discrete coarctation and metabolic acidosis caused by systemic circulatory collapse, as the mortality risk of surgery was considered high in these cases. Interventions were as a bridge to surgery, which allowed clinician to stabilize newborn and perform a safer surgery. Angioplasty was not preferred in the patients with long-segment coarctation. However, a retrospective review of our experiences showed that balloon angioplasty of coarctation was performed as palliative approach to a small number cases who were LBW and clinically unstable, as surgery had

a high risk in this patient group. It was considered that interventional cardiac therapy could give time to high-risk newborns to grow up and become clinically more stable, which could also reduce the mortality and morbidity of surgery. In these patients, vascular access was provided by interventional radiologists under the guidance of ultrasonography.

In the current study, we observed no permanent injury or mortality related to the interventional procedures in any patient. Except for a small number of infants with pulmonary stenosis and aortic coarctation (18%), the majority of interventions were palliative procedures (82%). The long-term mortality rate was 36%.

In their study, Kobayashi *et al.*^[16] reported that reintervention was not necessary during the six-year follow-up in four of six infants (67%) weighing <2,500 g who underwent balloon pulmonary valvuloplasty due to the isolated valvular pulmonary stenosis. According to the literature, balloon pulmonary valvuloplasty is a curative treatment, even for infants with LBW.^[16,17]

Despite the high risk of recurrent stenosis, balloon valvuloplasty has an important place in the treatment of congenital aortic stenosis. Sutton *et al.*^[18] used balloon valvuloplasty in four patients with valvular aortic stenosis and LBW. One of these patients had mild aortic regurgitation and aortic stenosis and was followed for 4.5 years without reintervention. In addition, Kobayashi *et al.*^[16] reported that one of two patients who underwent balloon aortic valvuloplasty did not require any other procedure during the six-year follow-up. In the present study, a 20-day-old infant with borderline hypoplastic left heart syndrome underwent balloon aortic valvuloplasty and balloon coarctation angioplasty procedures. The failure of the left ventricle to support systemic circulation necessitated Norwood surgery. While balloon aortic valvuloplasty can be curative in very small infants where surgery is risky, it can be performed as a palliative treatment, until surgery is performed under suitable conditions.

Although surgery is the treatment of choice of PDA, transcatheter closure of PDA was performed in only one patient in this study, since this case had metabolic acidosis and sepsis. The PDA occluder caused pulmonary stenosis and severe pulmonary regurgitation in this case. Therefore, the device was retrieved and PDA was ligated surgically. However, transcatheter approach to PDA in premature infants was not attempted again, as it was considered unsafe. Iatrogenic coarctation, pulmonary stenosis, and severe vessel injury are common complications which are

encountered during transcatheter closure of PDA in preterm babies. It should be recognized that PDA in preterm infant is closed surgically with low complications in the current practice.

Balloon atrial septostomy is an important palliative treatment for CHDs, such as transposition of the great arteries. Given the high risk of surgical procedures in infants with LBW, balloon atrial septostomy can be a life-saving procedure, until the infants reach a reasonable body weight. In the present study, the final surgical procedure was performed, when four of five patients who underwent balloon atrial septostomy without any complications reached the appropriate weight. These results are also consistent with the previous findings.^[16,19]

Although interventional procedures are life-saving for the infants with CHD and LBW they may cause serious complications. Several studies have reported complication rates ranging between 26 and 56% during cardiac catheterization in infants weighing <2,500 g.^[13,17,19-21] In the present study, we found a rate of 63.4% in infants <2,500 g in weight. According to the literature, the most frequent complications include arrhythmias, vascular injuries, bleeding requiring blood transfusion, respiratory depression, and mortality.^[15-21] Low-birth-weight babies with duct-dependent lesions can be followed under prostaglandin infusion, until they gain weight. We did not observe procedure-related mortality in any patient. In our series, the most frequent complications were blood loss leading to low hemoglobin levels and vascular injury. Umbilical artery and vein can be used for the vascular access in newborns with LBW. When ductus venosus is patent, umbilical vein can be used to access all cardiac sites. Although the exact upper size limit is unknown for catheters to be safely placed in umbilical vessels in newborns with LBW, 4-Fr and 5-Fr catheters can be safely used. In order to use the umbilical vessels, catheters must be placed within the first three days after birth. In our patients, interventional procedures were performed beyond three days in all but three patients, and the umbilical artery/vein access was not suitable. Although favorable outcome has been reported with procedures performed via carotid artery, some authors have reported complications with this approach.^[22,23] Vessel selection is rather related to our center's experience. Interventional procedures performed via femoral arterial and venous access are considered safe in infants with LBW.^[17] Vascular injuries and stenosis are particularly major problems in infants. Vascular complications are lower, when 3-Fr sheath-fitted balloons are used. We have started

to employ this equipment in our clinic recently; however, 3-Fr sheath was not used in any patient included in this study. In the present study, the arterial route was used to perform interventional procedures in 13 patients and, despite the anticoagulant treatment, five of these patients had no femoral pulse at the time of discharge. Anticoagulant treatment-related bleeding was not observed in any patient. Also, transfontanelar ultrasonography did not show intracranial hemorrhage related to streptokinase. Heparin was not used during the interventional procedures in two of 12 patients with vascular complications. Anticoagulant treatment, when administered in suitable doses, minimizes vascular complications. During the arterial intervention procedures of LBW infants and after the procedure (independent of the presence of pulse), we routinely use heparin treatment for six hours, followed by streptokinase treatment in patients with no pulse. Currently, there is notably no consensus on the treatment modalities, dosage, and duration of fibrinolytic treatment in the neonatal period. Different fibrinolytic treatment regimens are based on relevant data drawn from small case series in the literature.^[24,25] The most common complications are minor or major bleedings.^[24,25] We believe that streptokinase treatment is a safe and effective method of clot dissolution in LBW infants. We did not observe major bleeding or, thrombosis or allergic reaction during streptokinase treatment, which supports the safety of these medications in LBW infants.

Several studies have reported a rate of serious complications ranging between 11 and 13%.^[16-18,20] The rate of serious complications (18%) in our study is consistent with the previous findings. More interestingly, despite general anesthesia, respiratory complications were not frequent in infants. When performing interventional procedures to these infants, a healthcare professional who is expert on endotracheal intubation in infants should be present.

The retrospective nature and missing data about the patients who did not attend to their scheduled follow-up visits are the main limitations of the present study.

In conclusion, in our clinic, the preferred treatment strategy for infants with low birth weight is to wait for the suitable time for the final or palliative surgical treatment to reduce the risk (i.e., medical treatment and/or catheterization). Our study findings indicate that interventional procedures are possible and can be performed with acceptable complication rates in infants with low birth weight. In addition, these results support that anticoagulant treatment can be safely administered in appropriate doses. Nonetheless, further large-scale, long-term studies are needed to establish a definite conclusion.

Declaration of conflicting interests

The authors declared no conflicts of interest with respect to the authorship and/or publication of this article.

Funding

The authors received no financial support for the research and/or authorship of this article.

REFERENCES

1. Rosenthal GL, Wilson PD, Permutt T, Boughman JA, Ferencz C. Birth weight and cardiovascular malformations: a population-based study. *The Baltimore-Washington Infant Study*. *Am J Epidemiol* 1991;133:1273-81.
2. Curzon CL, Milford-Beland S, Li JS, O'Brien SM, Jacobs JP, Jacobs ML, et al. Cardiac surgery in infants with low birth weight is associated with increased mortality: analysis of the Society of Thoracic Surgeons Congenital Heart Database. *J Thorac Cardiovasc Surg* 2008;135:546-51
3. Fletcher SE, Nihill MR, Grifka RG, O'Laughlin MP, Mullins CE. Balloon angioplasty of native coarctation of the aorta: midterm follow-up and prognostic factors. *J Am Coll Cardiol* 1995;25:730-4.
4. Park Y, Lucas VW, Sklansky MS, Kashani IA, Rothman A. Balloon angioplasty of native aortic coarctation in infants 3 months of age and younger. *Am Heart J* 1997;134:917-23.
5. Rao PS, Waterman B. Relation of biophysical response of coarcted aortic segment to balloon dilatation with development of recoarctation following balloon angioplasty of native coarctation. *Heart* 1998;79:407-11.
6. Egito ES, Moore P, O'Sullivan J, Colan S, Perry SB, Lock JE, et al. Transvascular balloon dilation for neonatal critical aortic stenosis: early and midterm results. *J Am Coll Cardiol* 1997;29:442-7.
7. Moore P, Egito E, Mowrey H, Perry SB, Lock JE, Keane JF. Midterm results of balloon dilation of congenital aortic stenosis: predictors of success. *J Am Coll Cardiol* 1996;27:1257-63.
8. Pass RH, Hellenbrand WE. Catheter intervention for critical aortic stenosis in the neonate. *Catheter Cardiovasc Interv* 2002;55:88-92.
9. Colli AM, Perry SB, Lock JE, Keane JF. Balloon dilation of critical valvar pulmonary stenosis in the first month of life. *Cathet Cardiovasc Diagn* 1995;34:23-8.
10. Radtke W, Keane JF, Fellows KE, Lang P, Lock JE. Percutaneous balloon valvotomy of congenital pulmonary stenosis using oversized balloons. *J Am Coll Cardiol* 1986;8:909-15.
11. Rome JJ. Balloon pulmonary valvuloplasty. *Pediatr Cardiol* 1998;19:18-24.
12. Ades AM, Dominguez TE, Nicolson SC, Gaynor JW, Spray TL, Wernovsky G, et al. Morbidity and mortality after surgery for congenital cardiac disease in the infant born with low weight. *Cardiol Young* 2010;20:8-17.
13. Cheng HH, Almodovar MC, Laussen PC, Wypij D, Polito A, Brown DW, et al. Outcomes and risk factors for mortality in premature neonates with critical congenital heart disease. *Pediatr Cardiol* 2011;32:1139-46.

14. Zampi JD, Armstrong AK, Hirsch-Romano JC. Hybrid perventricular pulmonary valve perforation and right ventricular outflow stent placement: a case report of a premature, 1.3-kg neonate with tetralogy of Fallot and pulmonary atresia. *World J Pediatr Congenit Heart Surg* 2014;5:338-41.
15. Akin A, Aykan HH, Karagöz T. Antegrade balloon valvuloplasty for critical aortic stenosis in a premature neonate weighing 1100 g. *Turk J Pediatr* 2014;56:115-7.
16. Kobayashi D, Sallaam S, Aggarwal S, Singh HR, Turner DR, Forbes TJ, et al. Catheterization-based intervention in low birth weight infants less than 2.5 kg with acute and long-term outcome. *Catheter Cardiovasc Interv* 2013;82:802-10.
17. Simpson JM, Moore P, Teitel DF. Cardiac catheterization of low birth weight infants. *Am J Cardiol* 2001;87:1372-7.
18. Sutton N, Lock JE, Geggel RL. Cardiac catheterization in infants weighing less than 1,500 grams. *Catheter Cardiovasc Interv* 2006;68:948-56.
19. McMahon CJ, Price JF, Salerno JC, El-Said H, Taylor M, Vargo TA, et al. Cardiac catheterisation in infants weighing less than 2500 grams. *Cardiol Young* 2003;13:117-22.
20. Karagöz T, Akin A, Aykan HH, Çeliker A, Alehan D, Özer S, et al. Interventional cardiac catheterization in infants weighing less than 2500 g. *Turk J Pediatr* 2015;57:136-40.
21. Rhodes JF, Asnes JD, Blaufox AD, Sommer RJ. Impact of low body weight on frequency of pediatric cardiac catheterization complications. *Am J Cardiol* 2000;86:1275.
22. Fischer DR, Ettetgui JA, Park SC, Siewers RD, del Nido PJ. Carotid artery approach for balloon dilation of aortic valve stenosis in the neonate: a preliminary report. *J Am Coll Cardiol* 1990;15:1633-6.
23. Maeno Y, Akagi T, Hashino K, Ishii M, Sugimura T, Takagi J, et al. Carotid artery approach to balloon aortic valvuloplasty in infants with critical aortic valve stenosis. *Pediatr Cardiol* 1997;18:288-91.
24. Cheah FC, Boo NY, Rohana J, Yong SC. Successful clot lysis using low dose of streptokinase in 22 neonates with aortic thromboses. *J Paediatr Child Health* 2001;37:479-82.
25. Aydın B, Beken S, Dilli D, Çınar HG, Özkan E, Zenciroğlu A, et al. Fibrinolytic therapy of thrombosis in 27 newborns followed-up in neonatal intensive care unit. *Pediatr Hematol Oncol* 2013;30:705-16.