



The diagnostic value of fiberoptic bronchoscopy in ruptured lung hydatid cysts

Rüptüre akciğer kist hidatiklerinde fiberoptik bronkoskopinin tanı değeri

Ali Bilal Ulaş¹, Atilla Eroğlu¹, Yener Aydın¹, Ömer Araz², Ayman Ahmed¹

¹Department of Thoracic Surgery, Atatürk University Faculty of Medicine, Erzurum, Turkey

²Department of Chest Diseases, Atatürk University Faculty of Medicine, Erzurum, Turkey

ABSTRACT

Background: This study aims to evaluate the diagnostic yield of fiberoptic bronchoscopy in ruptured pulmonary hydatid cysts indistinguishable from pulmonary masses on imaging techniques.

Methods: Between January 2000 and January 2018, a total of 45 consecutive patients (27 males, 18 females; mean age 46.4±13.5 years; range, 23 to 78 years) who underwent fiberoptic bronchoscopy to establish the definitive diagnosis following radio-diagnostic procedures were retrospectively analyzed. Data including demographic and clinical characteristics of the patients, preoperative diagnostic studies, bronchoscopic findings, and postoperative diagnosis were recorded.

Results: Endobronchial hyperemia (n=42) and purulent secretion (n=34) are the most common findings of bronchoscopy. The most specific finding was the presence of pieces of cystic membranes in 23 patients. Scolices were seen in five patients in bronchial aspirate. In one patient, both pieces of cystic membranes and scolices in bronchial aspirate were detected. The preliminary diagnosis of a hydatid cyst was made based on these findings in 28 patients (62.2%) preoperatively. The definitive diagnosis of a hydatid cyst was confirmed through thoracotomy in all patients.

Conclusion: Bronchoscopy is a particularly valuable method in the definitive diagnosis of ruptured lung hydatid cysts. The definite diagnosis is based on the visualization of the endobronchial membrane during bronchoscopy or scolices in the bronchial aspirate. It can be also used to prevent complications such as bronchial dissemination and asphyxia due to intra-bronchial membrane pieces.

Keywords: Bronchoscopy, hydatid disease, lung.

ÖZ

Amaç: Bu çalışmada, görüntüleme teknikleri ile akciğer kitlelerinden ayırt edilemeyen rüptüre akciğer hidatik kistlerinin tanısında fiberoptik bronkoskopinin katkısı araştırıldı.

Çalışma planı: Ocak 2000 - Ocak 2018 tarihleri arasında radyolojik tanı işlemlerinden sonra kesin tanı konması amacıyla fiberoptik bronkoskopi yapılan toplam 45 ardışık hasta (27 erkek, 18 kadın; ort. yaş 46.4±13.5 yıl; dağılım, 23-78 yıl) retrospektif olarak incelendi. Hastaların demografik ve klinik özellikleri, ameliyat öncesi tanı çalışmaları, bronkoskopi bulguları ve ameliyat sonrası tanıları dahil olmak üzere veriler kaydedildi.

Bulgular: Endobronşiyal hiperemi (n=42) ve pürülan sekresyon (n=34) bronkoskopinin en yaygın bulgularıydı. Hastaların 23'ünde en belirgin bulgu kistik membran parçacıklarının varlığı idi. Beş hastada bronşiyal aspiratta skoleksler görüldü. Bir hastada ise, bronşiyal aspiratta hem kist membran parçacıkları hem de skoleksler tespit edildi. Hastaların 28'inde (%62.2) ameliyat öncesinde bu bulgulara dayanarak kist hidatik öncül tanısı kondu. Kist hidatiğin kesin tanısı tüm hastalarda torakotomi ile doğrulandı.

Sonuç: Bronkoskopi, rüptüre akciğer hidatik kistlerinin kesin tanısında bilhassa değerli bir yöntemdir. Bronkoskopide endobronşiyal membranın veya bronşiyal aspiratta skolekslerin görülmesi kesin tanı koydurucudur. Ayrıca, intrabronşiyal membran parçacıklarına bağlı asfiksi ve bronşiyal disseminasyon gibi komplikasyonları önlemede kullanılabilir.

Anahtar sözcükler: Bronkoskopi, hidatik hastalık, akciğer.

Received: November 01, 2018 Accepted: November 19, 2018 Published online: June 25, 2019

Correspondence: Ali Bilal Ulaş, MD. Atatürk Üniversitesi Tıp Fakültesi Göğüs Cerrahisi Anabilim Dalı, 25240 Erzurum, Turkey.
Tel: +90 542 - 225 87 39 e-mail: dralibilalulas@gmail.com

Cite this article as:

Ulaş AB, Eroğlu A, Aydın Y, Araz Ö, Ahmed A. The diagnostic value of fiberoptic bronchoscopy in ruptured lung hydatid cysts. Turk Gogus Kalp Dama 2019;27(3):350-354

Lung with hydatid disease caused by the larval form of *Echinococcus granulosus* ranks the second after liver. Diagnosis is easily made in endemic regions based on typical location and imaging findings, although ruptured hydatid cysts can be misdiagnosed as bronchial carcinomas or cavitory lung lesions.^[1] Bronchoscopic investigation is necessary in case of ruptured hydatid cysts, which can mimic the lung masses with their various and strange manifestations and in the centrally located cysts.^[2]

Fiberoptic bronchoscopy has been increasingly used in pulmonary diseases and is effective in the diagnosis of various pathologies. However, there is a very limited number of studies in the literature regarding the diagnosis of hydatid disease using fiberoptic bronchoscopy.

In the present study, we aimed to evaluate the diagnostic yield of fiberoptic bronchoscopy in ruptured pulmonary hydatid cysts which are indistinguishable from pulmonary masses on imaging techniques.

PATIENTS AND METHODS

We retrospectively reviewed the medical records of the patients who underwent thoracotomy and diagnosed with pulmonary hydatid disease in our clinic between January 2000 and January 2018. A total of 670 consecutive patients with intra-thoracic hydatid disease were operated in our clinic. Of the patients, 45 (27 males, 18 females; mean age 46.4 ± 13.5 years; range, 23 to 78 years) who underwent preoperative bronchoscopic examination due to diagnostic difficulties were included in this study. A written informed consent was obtained from each patient. The study protocol was approved by the Atatürk University Medical Faculty Ethics Committee. The study was conducted in accordance with the principles of the Declaration of Helsinki.

Thoracic X-ray and computed tomography (CT) were performed in all patients. Bronchoscopy was performed in all patients either due to negative radiographies for hydatid cysts or to eliminate malignancy. Bronchoscopies were performed using a flexible fiberoptic bronchoscope. Two types of fiberoptic bronchoscope (Olympus BF 20D and BF 1T240, models of Olympus Optical Co. Ltd., Tokyo, Japan) were used for the bronchoscopic examination. The patients were sedated with 5 mg diazepam and, during the procedure, local anesthesia was administered to all patients with the instillation of 2% prilocaine hydrochloride solution. The transnasal route was used during bronchoscopy. Bronchial lavage specimens were taken for smear and culture testing. The diagnosis of pulmonary hydatid

disease was based on the direct visualization of hydatid membrane or microscopically confirmation of scolices. Nine patients in whom a diagnosis was not made either from radiological techniques, or laboratory or bronchoscopy underwent thoracotomy to rule out malignancy. Data including demographic and clinical characteristics of the patients, preoperative diagnostic studies, bronchoscopic findings, and postoperative diagnosis were recorded.

Statistical analysis

The IBM SPSS version 20.0 software (IBM Corp., Armonk, NY, USA) was used for statistical analyses. Data are presented as mean, standard deviation, median; and with the minimum and maximum values, numbers and percentages. A *p* value <0.05 were considered as statistically significant.

RESULTS

The most common symptoms in our patients were cough and blood-streaked sputum. Thoracic X-ray and CT revealed abnormal findings in all patients, although there were no specific parenchymal lesions for hydatid disease of the lung. Thoracic X-ray showed a central mass in 32 (71.1%) of the patients and peripheral type lesions in 13 (28.9%) of the patients; however, it was not enough for the definitive diagnosis of a hydatid cyst. The most frequent CT manifestation of the patients was heterogeneous mass lesions (Figures 1-3). Serological testing was performed in 22 of the patients, although the results were positive only in eight patients (36.3%). Fiberoptic bronchoscopy was performed in all

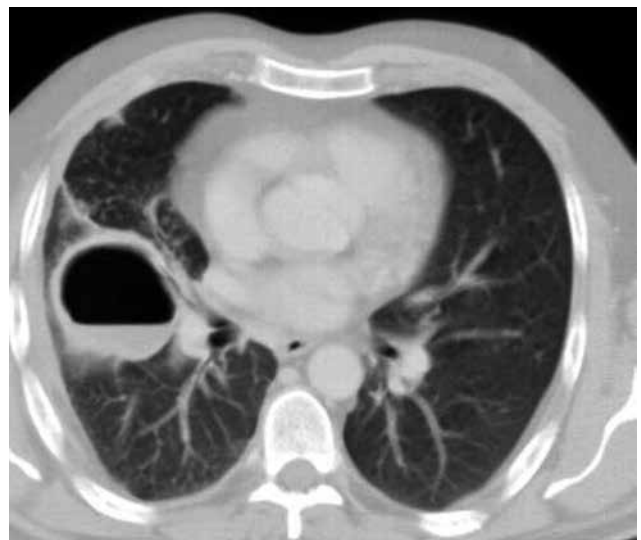


Figure 1. An axial computed tomography image showing a ruptured right lung hydatid cyst.

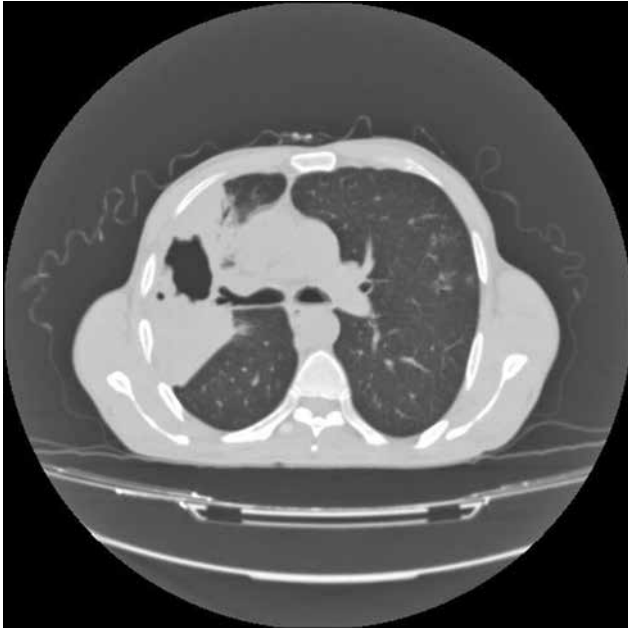

Figure 2. An axial computed tomography image showing a ruptured right lung hydatid cyst.

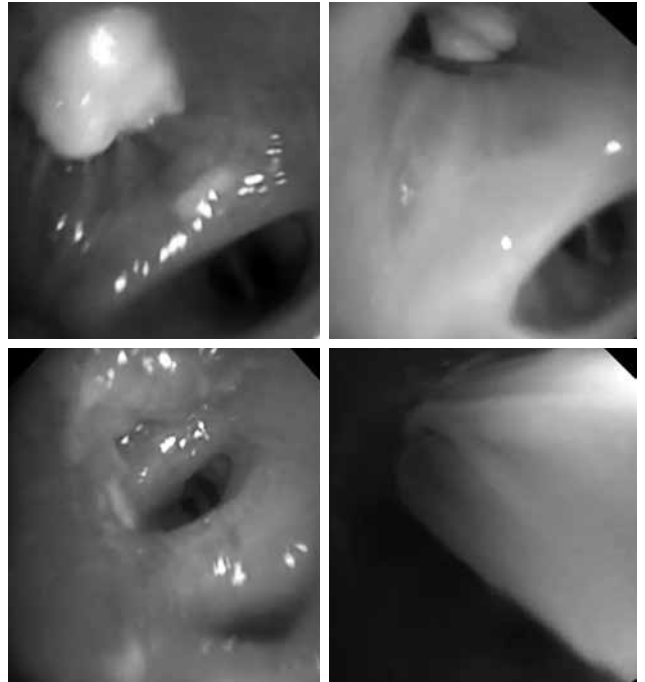

Figure 3. A bronchoscopic image showing germinal membrane in ruptured hydatid cyst.

patients, as the probability of tumor was unable to be eliminated by other methods.

The mean time between the initial symptom to bronchoscopy was 21.6 (range, 6 to 54) days. Endobronchial hyperemia was found in 42 (93.3%) of the patients. The definitive diagnosis was made by detecting germinative membranes in 23 patients (51.1%) and by the presence of scolices in the bronchial

aspirate in five patients (11.1%) (Figures 4a-c). The preliminary diagnosis of a hydatid cyst was made based on these findings in 28 patients (62.2%) preoperatively. All patients were, then, treated surgically with posterolateral thoracotomy. The applied operation types included cystotomy and capitonnage (n=37, 84.4%)




Figure 4. Lamellar acellular membrane and associated protoscolices. Period acid-Schiff (PAS) staining (a) (2×), (b) (10×), (c) (20×).

Table 1. Demographic and clinical characteristics of patients and procedure-related data

	n	%	Mean±SD	Range
Age (year)			46.4±13.5	23-78
Gender				
Male	27	60		
Female	18	40		
Symptoms				
Cough	45	100		
Blood-streaked sputum	37	67.3		
Fever	25	55.6		
Chest pain	16	35.6		
Urticaria	6	13.3		
Diagnostic applications				
Chest X-ray	45	100		
Computed tomography	45	100		
Abdominal ultrasound	17	37.8		
Indirect hemagglutination	22	48.9		
Bronchoscopy findings				
Endobronchial hyperaemia	42	93.3		
Purulent secretion	34	75.6		
Mucosal hemorrhage	24	53.3		
Membrane fragments	23	51.1		
External compression of bronchus	10	22.2		

SD: Standard deviation.

and cystectomy and capitonnage (15.6%, n=8). There were no postoperative complications or mortality after bronchoscopy or surgery. Albendazole was administered to all patients after the operation for one to three months. The mean follow-up was 4.5 years (range, 3 months to 7 years). Demographic and clinical data and procedure-related data are summarized in Table 1.

DISCUSSION

Imaging methods and radiographic signs are often enough for the diagnosis of pulmonary hydatid disease in countries where the disease is endemic.^[3-5] In endemic regions, the imaging modalities are more sensitive than serological examinations. In general, hydatid cysts are well-defined homogeneous, spherical lesions which are located at the basal portions of the lungs. In the presence of typical radiological findings to lung hydatid cyst, the diagnosis can be made without suspicion, even if serological tests yield negative results.^[6] However, in the presence of cyst ruptures, radiological findings become more complicated and can mimic other diseases. In these cases, laboratory methods and other diagnostic procedures can be used. The expectoration of the hydatid fluid and germinative

membranes which can be seen in 2 to 9% of cases is a pathognomonic finding of cyst hydatid, representing the rupture of the cyst to the bronchial system.^[7,8] The visualization of scolices at the bronchial lavage or membrane fragments during the bronchoscopy procedure performed simultaneously also can make the definitive diagnosis.

In areas where hydatid cysts is endemic, thoracic CT is usually sufficient for the diagnosis of intact simple hydatid cysts. It also provides important data in differential diagnosis. When the hydatid fluid is emptied completely from the pericystic cavity, the residual membrane constitutes more homogeneous opaque appearance and the size of the lesion becomes smaller.^[9,10] The CT density values range from 42 to 60 HU in simple hydatid cysts, while it ranges from 9 to 160.5 HU in ruptured hydatid cysts.^[11] The higher attenuation values represent the fibrosis and infection of the cyst. The increased densities due to residual membrane after the drainage of the cystic fluid and the beginning of the infectious process can be misdiagnosed with other lung diseases particularly with malignant carcinomas. Bronchoscopy is particularly the choice of the diagnostic methods, when a centrally located, ruptured cyst hydatid simulates

the radiological findings of malignant mass lesions. To rule out malignancy, this method was considered more time-saving and cost-effective, compared to other diagnostic methods.

The bronchoscopy procedures which are made for the differential diagnosis can provide diagnostic findings specific to the cyst. Saygi et al.^[12] provided bronchoscopic diagnosis in 14 of 24 patients (58%) in whom complicated pulmonary hydatid disease diagnosis was confirmed by thoracotomy. In our study, we made the definitive diagnosis in 23 patients based on the presence of endobronchial membranes on bronchoscopy which was performed for the differential diagnosis of the mass or cavitary lesion. The detection of scolices on histological examination of the bronchial lavage, despite the absence of membranes provided definitive preoperative diagnosis in five patients. In our opinion, low accuracy of cytological diagnosis is mainly due to total expectoration of the hydatid fluid. In addition, we believe that, in our study group, the mean delay of bronchoscopic evaluation led to difficulty in cytological diagnosis of hydatid materials. The accuracy of preoperative diagnosis of bronchoscopy was 62.2% as confirmed by postoperative results.

Furthermore, bronchial spreading of the hydatid fluid and the obstruction due to membranes may be fatal. In addition to lavage and aspiration during bronchoscopy, the extraction of the pieces of the membrane becomes preventive for possible complications. The extraction of membrane pieces only by bronchoscopy is not a safe procedure for the treatment. Pericystic cavity and residual membranes continue to become a source to recurrent infection, even if some parts of the membrane are being extracted. Surgical approach is necessary for the treatment of the residual pericystic cavity, despite this procedure.^[10]

The main limitations of the present study include its small sample size and retrospective design.

In conclusion, the confirmation of the diagnosis by fiberoptic bronchoscopy in uncertain cases is both a simple and cost-saving approach. The definitive diagnosis can be made during this procedure in selected patients. Tracheobronchial complications of

ruptured hydatid cysts can be also controlled during bronchoscopy, thereby, preventing complications such as bronchial dissemination and asphyxia due to intra-bronchial membrane pieces.

Declaration of conflicting interests

The authors declared no conflicts of interest with respect to the authorship and/or publication of this article.

Funding

The authors received no financial support for the research and/or authorship of this article.

REFERENCES

1. Komurcuoglu B, Ozkaya S, Cirak AK, Yalniz E, Polat G. Pulmonary hydatid cyst: The characteristics of patients and diagnostic efficacy of bronchoscopy. *Exp Lung Res* 2012;38:277-80.
2. Taha AS. Diagnosis of ruptured pulmonary hydatid cyst by means of flexible fiberoptic bronchoscopy: a report of three cases. *J Thorac Cardiovasc Surg* 2005;130:1196-7.
3. Kurkuoglu IC, Eroglu A, Karaoglanoglu N, Turkyilmaz A, Tekinbas C, Basoglu A. Surgical approach of pulmonary hydatidosis in childhood. *Int J Clin Pract* 2005;59:168-72.
4. Aydin Y, Dostbil A, Araz O, Oglu H, Ulas AB, Zeytun H, et al. Pre-school children with hydatid lung disease. *Acta Chir Belg* 2013;113:340-5.
5. Aydin Y, Celik M, Ulas AB, Eroglu A. Transdiaphragmatic approach to liver and lung hydatid cysts. *Turk J Med Sci* 2012; 42:1388-93.
6. Olut AI, Erguven S, Emri S, Ozunlu H, Akay H. Diagnostic value of a dot immunobinding assay for human pulmonary hydatidosis. *Korean J Parasitol* 2005;43:15-8.
7. Keramidas D, Mavridis G, Soutis M, Passalidis A. Medical treatment of pulmonary hydatidosis: complications and surgical management. *Pediatr Surg Int* 2004;19:774-6.
8. Kuzucu A. Parasitic diseases of the respiratory tract. *Curr Opin Pulm Med* 2006;12:212-21.
9. Karaoglanoglu N, Kurkuoglu IC, Gorguner M, Eroglu A, Turkyilmaz A. Giant hydatid lung cysts. *Eur J Cardiothorac Surg* 2001;19:914-7.
10. Ramos G, Orduña A, García-Yuste M. Hydatid cyst of the lung: diagnosis and treatment. *World J Surg* 2001;25:46-57.
11. Koul PA, Koul AN, Wahid A, Mir FA. CT in pulmonary hydatid disease: unusual appearances. *Chest* 2000;118:1645-7.
12. Saygi A, Oztek I, Güder M, Söngün F, Arman B. Value of fiberoptic bronchoscopy in the diagnosis of complicated pulmonary unilocular cystic hydatidosis. *Eur Respir J* 1997;10:811-4.