



## Multiple hydatid cysts of the interventricular septum

### *İnterventriküler septumda multipl kist hidatik*

Mustafa Tascanov<sup>1</sup>, Mehmet Uğur<sup>2</sup>

*Institution where the research was done:*  
Medical Park Elazığ Hospital, Elazığ, Turkey

*Author Affiliations:*

<sup>1</sup>Department of Cardiology, Medicine Faculty of Harran University, Şanlıurfa, Turkey

<sup>2</sup>Department of Cardiovascular Surgery, Medical Park Elazığ Hospital, Elazığ, Turkey

#### ABSTRACT

Hydatid disease, *Echinococcus granulosus*, is a parasitic infection which is endemic in some countries. The liver and lungs are the most common sites of infection. Cardiac involvement is extremely rare. The most common localizations of cardiac involvement are the left ventricular free wall, right ventricle, and interventricular septum. Herein, we present a rare case of multiple cardiac hydatid cysts in the interventricular septum.

**Keywords:** Hydatid cyst, interventricular septum, multiple.

Hydatid disease, *Echinococcus granulosus*, is a parasitic infection which is endemic in some countries. The liver (65%) and lungs (25%) are the most common sites of infection. Cardiac involvement is rare and represents 0.02 to 2% of all hydatid cysts. The most common localizations of cardiac involvement are the left ventricular free wall (75%), right ventricle (18%), and interventricular septum (7%).<sup>[1-3]</sup>

Herein, we present a rare case of multiple cardiac hydatid cysts in the interventricular septum.

#### CASE REPORT

A 30-year-old male patient was admitted to our outpatient clinic with dyspnea and fatigue. He underwent neurosurgery for a hydatid cyst four years ago. Physical examination revealed normal heart sounds, a blood pressure of 110/70 mmHg (both arms), and a normal pulse of 70 bpm. His electrocardiogram displayed

#### ÖZ

Kist hidatik, *Echinococcus granulosus*, paraziter bir enfeksiyon olup, bazı ülkelerde endemiktir. Karaciğer ve akciğerler en sık enfeksiyon bölgeleridir. Kardiyak tutulum oldukça nadirdir. En sık görülen kardiyak tutulum bölgeleri sol ventrikül serbest duvarı, sağ ventrikül ve interventriküler septumdur. Bu yazıda, nadir bir interventriküler septumda multipl kardiyak kist hidatik olgusu sunuldu.

**Anahtar sözcükler:** Hidatik kist, interventriküler septum, multipl.

normal sinus rhythm. T-wave negativity was observed in leads II, III, and aVF. Routine blood analysis and chest X-ray indicated no abnormal findings. Transthoracic echocardiography revealed multiple cystic masses, the largest of which was 38×40 mm in diameter and extended from the interventricular septum to the inferoposterior wall, as confirmed by the apical two-chamber and the parasternal short-axis (Figure 1a, Videos 1 and 2).

Color Doppler ultrasound displayed no correlation between the cystic structure and cavity. Computed tomography examination of the lungs and liver showed no other cystic structures. He was prescribed albendazole 400 mg and was referred to surgery. A written informed consent was obtained from the patient.

A median sternotomy and bicaval cannulation were performed. After the cross-clamp was placed in the aorta, crystalloid cardioplegia solution was given and

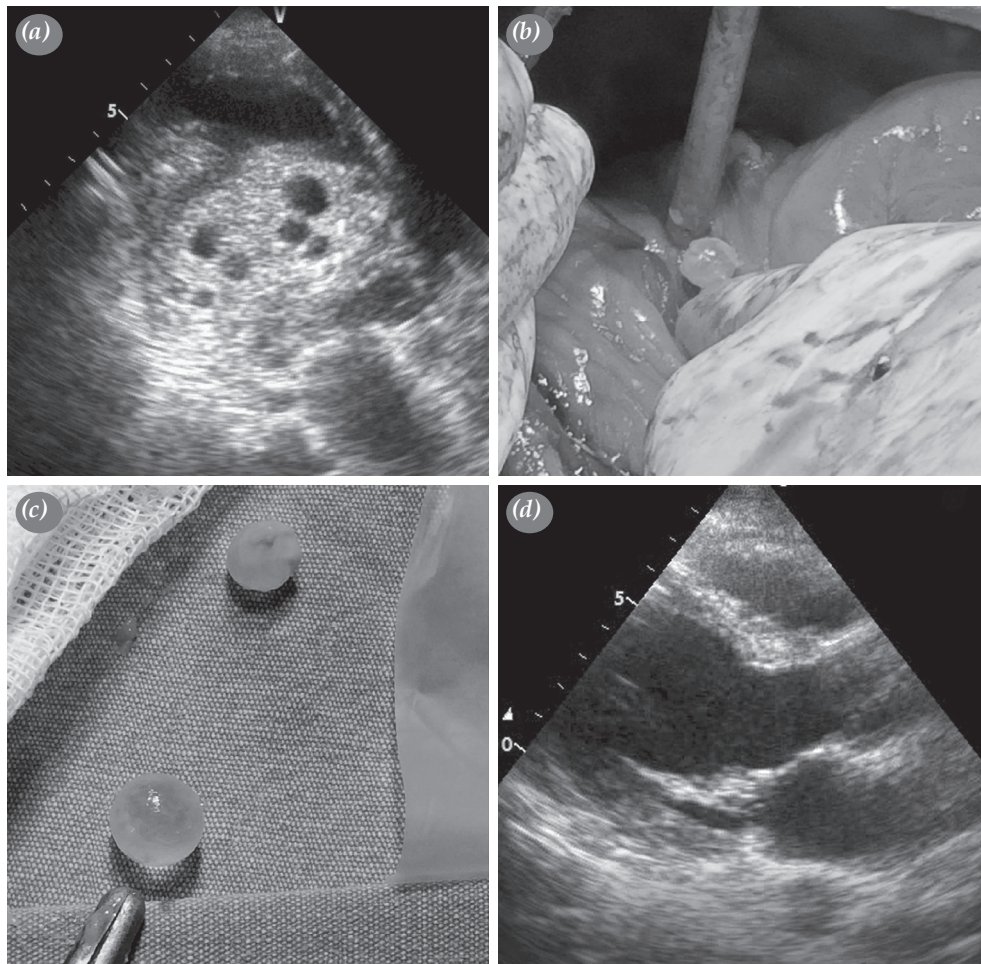
Received: December 26, 2018 Accepted: March 12, 2019 Published online: June 14, 2019

**Correspondence:** Mustafa Tascanov, MD, Harran Üniversitesi Tıp Fakültesi, Kardiyoloji Anabilim Dalı, 63300 Şanlıurfa, Turkey.  
Tel: +90 555 - 786 00 33 e-mail: drbegenc@gmail.com

**Cite this article as:**

Tascanov M, Uğur M. Multiple hydatid cysts of the interventricular septum. Turk Gogus Kalp Dama 2019;27(3):398-400

©2019 All right reserved by the Turkish Society of Cardiovascular Surgery.



**Figure 1.** (a) An echocardiographic image showing cardiac hydatid cysts. (b, c) An intraoperative image of cysts. (d) An echocardiographic image after surgery.

returned with superior and inferior vena cava tapes. Moderate hypothermia was applied. Before the cyst was opened, 20% NaCl-impregnated gauze was placed around both the heart and right cardiac spaces. The cyst was reached with a delicate and careful small surgical incision on the cyst, located in the interventricular septum. Cysts were removed without rupture. A right ventriculotomy was performed followed by excision of the hydatid cyst from the interventricular septum; the patient was moved to the recovery room without any complications (Figure 1b-d. Video 3). The pathology examination result was compatible with multiple hydatid cysts.

## DISCUSSION

Echinococcosis is an endemic parasitic disease, and cardiac involvement is rare. There is no specific

clinical picture of a cardiac hydatid cyst. However, the age, size, and degree of cyst calcification are the determinant factors for the clinical presentation. Symptoms are usually subjective symptoms such as dyspnea, palpitations, and atypical chest pain.<sup>[4,5]</sup>

With the growth of the cyst, life-threatening complications such as myocardial infarction, ventricular arrhythmias, sudden cardiac arrest, and pulmonary edema may develop due to the compression of the coronary arteries, cardiac conduction system and cardiac cavities. Also, cyst rupture, pulmonary or systemic embolism, or sudden death due to anaphylactic shock may occur.<sup>[5]</sup>

Our patient was diagnosed by transthoracic echocardiography and transesophageal echocardiography. He was unable to tolerate cardiac

magnetic resonance imaging. After the diagnosis was made, emergency surgery was performed to eliminate the potentially fatal consequences of rupture of the cyst. Albendazole treatment was initiated for six months to prevent a relapse. In hydatid cysts located in the interventricular septum, the surgical approach may be a right atriotomy or right ventriculotomy. In our case, we preferred the right ventriculotomy approach.

Cardiopulmonary bypass surgery has several advantages including the prevention of systemic embolization by clamping the aorta, the possibility of performing other intracranial exploration of other cysts which may be missed during the preoperative examination, and lack of any other surgical intervention for intracardiac cysts.<sup>[6]</sup>

Although there was a risk of atrioventricular block during the operation of cysts localized in the interventricular septum, this complication did not occur in our case. Care should be taken to avoid the distribution of cyst contents into cardiac spaces during surgical intervention.

In conclusion, early surgical removal of the cyst both prevents catastrophic complications and provides safe and satisfactory results.

#### **Declaration of conflicting interests**

The authors declared no conflicts of interest with respect to the authorship and/or publication of this article.

#### **Funding**

The authors received no financial support for the research and/or authorship of this article.

#### **REFERENCES**

1. Keçelgil H.T, Kolbakır F, Kalaç R, M.K. Erk M.K. Bir kardiyak kist hidatik olgusu ve cerrahi tedavisi. Turk Gogus Kalp Dama 1995;3:48-50.
2. Mushtaque M, Mir MF, Malik AA, Arif SH, Khanday SA, Dar RA. Atypical localizations of hydatid disease: experience from a single institute. Niger J Surg 2012;18:2-7.
3. Eckert J, Deplazes P. Biological, epidemiological, and clinical aspects of echinococcosis, a zoonosis of increasing concern. Clin Microbiol Rev 2004;17:107-35.
4. Ozer N, Aytemir K, Kuru G, Atalar E, Ozer Y, Ovünç K, et al. Hydatid cyst of the heart as a rare cause of embolization: report of 5 cases and review of published reports. J Am Soc Echocardiogr 2001;14:299-302.
5. Tuygun AK, Olsun A, Keser S, Tuygun A, Yurtseven N, Dağsalı S. Recurrent cardiac hydatid cyst with pulmonary involvement. Turk Gogus Kalp Dama 2005;13:59-61.
6. Tellez G, Nojek C, Juffe A, Ruffilanchas J, O'Connor F, Figuera D. Cardiac echinococcosis: report of 3 cases and review of the literature. Ann Thorac Surg 1976;21:425-30.