



Case Report / Olgu Sunumu

Urgent double switch operation in a patient with congenitally corrected transposition of great arteries and an untrained systemic ventricle

Doğumsal büyük arterlerin düzeltilmiş transpozisyonu ve hazır olmayan sistemik ventrikül olan bir hastada acil double switch operasyonu

Mehmet Salih Bilal¹, Arda Özyüksel^{1,2}, Mustafa Kemal Avşar¹, Özgür Yıldırım¹

Institution where the research was done:

Medicana International Istanbul Hospital, Istanbul, Turkey

Author Affiliations:

¹Department of Cardiovascular Surgery, Medicana International Istanbul Hospital, Istanbul, Turkey

²Department of Cardiovascular Surgery, Biruni University, Istanbul, Turkey

ABSTRACT

Congenitally corrected transposition of the great arteries is a rare cardiac abnormality. A nine-month-old male infant with the diagnosis of congenitally corrected transposition of the great arteries was admitted to our clinic with a history of pulmonary artery banding to train the left ventricle three months ago. On admission, he presented with bronchopneumonia, cyanosis, dyspnea, and severe biventricular heart failure associated with significant valvular regurgitation. An urgent double switch operation was performed with atrial and arterial switch procedures. Eight days of mechanical circulatory support was deemed mandatory following surgery. The patient is still under follow-up uneventfully three years after the operation.

Keywords: Congenitally corrected transposition of the great arteries, double switch procedure, intact interventricular septum, pulmonary artery banding.

Congenitally corrected transposition of the great arteries (cc-TGA) is a rare cardiac malformation. The surgical treatment options and timing of operation in cases with cc-TGA may vary depending on the associated congenital heart defects and dominance of the left or right ventricle. The double switch operation (DSO), which is also termed as the anatomical repair, provides the left ventricle (LV) serving as the systemic ventricle. The LV may be trained with a prior pulmonary artery banding (PAB) followed by the DSO in selected

ÖZ

Doğumsal büyük arterlerin düzeltilmiş transpozisyonu nadir görülen bir kalp anomalisidir. Doğumsal büyük arterlerin düzeltilmiş transpozisyonu tanısı konmuş dokuz aylık bir erkek bebek üç ay önce sol ventrikülün hazırlanması amacıyla pulmoner arter bantlama öyküsü ile kliniğimize başvurdu. Başvuru sırasında hasta bronkopnömoni, siyanoz, solunum sıkıntısı ve ciddi kapak yetmezliği ile ilişkili biventriküler kalp yetmezliği tablosunda idi. Atriyal ve arteriyal switch işlemleri ile birlikte acil double switch operasyonu yapıldı. Ameliyat sonrasında sekiz günlük mekanik dolaşım desteği zaruri görüldü. Hasta ameliyattan üç yıl sonra halen sorunsuz izlenmektedir.

Anahtar sözcükler: Doğumsal büyük arterlerin düzeltilmiş transpozisyonu, double switch prosedürü, intakt interventriküler septum, pulmoner arter bantlama.

cases.^[1] This approach retrains the LV, providing an increased afterload.^[2] A neonatal DSO following the PAB procedure may eliminate the untoward effects of PAB such as branch pulmonary artery distortion and neo-aortic valve dysfunction.

Herein, we describe the surgical management of a patient with the diagnosis of cc-TGA, severe systemic atrioventricular (AV) valve insufficiency with Ebstein's anomaly and ventricular failure who underwent an urgent DSO with a temporary mechanical systemic

Received: April 05, 2019 Accepted: December 03, 2019 Published online: January 23, 2020

Correspondence: Arda Özyüksel, MD, Medicana International İstanbul Hastanesi, Kalp ve Damar Cerrahisi Bölümü, 34520 Beylikdüzü, İstanbul, Türkiye.
Tel: +90 212 - 467 77 77 e-mail: ozyukselarda@yahoo.com

Cite this article as:

Bilal MS, Özyüksel A, Avşar MK, Yıldırım Ö. Urgent double switch operation in a patient with congenitally corrected transposition of great arteries and an untrained systemic ventricle. Turk Gogus Kalp Dama 2020;28(1):197-200

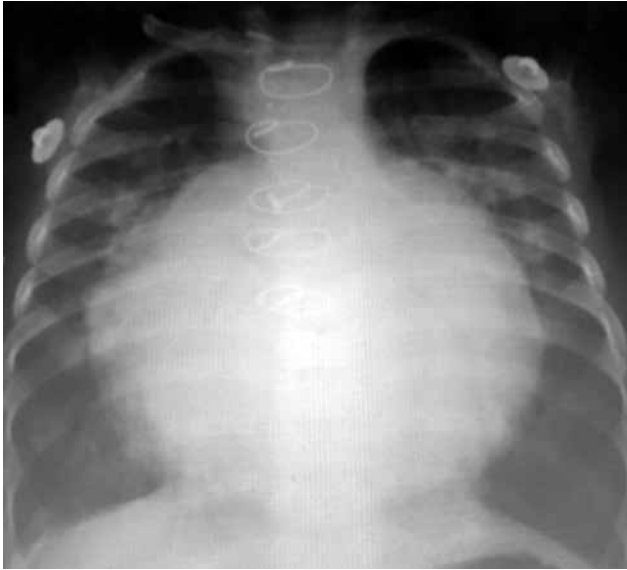

Figure 1. Chest X-ray showing significant cardiomegaly.

ventricular support. Although the PAB was performed prior to admission of this patient, the LV was still untrained, and we had to proceed with a salvage DSO; otherwise, the expected mortality would be high due to severe biventricular heart failure and cardiogenic shock.

CASE REPORT

A nine-month-old male infant weighing 5 kg was admitted to our clinic with the diagnosis of cc-TGA, Ebstein's anomaly and severe regurgitation of the systemic AV valve with an intact ventricular septum. The patient underwent a PAB procedure, when he was six months old. The procedure was completed with the pressure recordings of systemic (right) and pulmonary (left) ventricles as 80 and 55 mmHg,

respectively. The patient was well doing for four months, until when he was admitted to our clinic with bronchopneumonia, cyanosis, dyspnea, and severe biventricular heart failure associated with significant valvular regurgitation. Chest X-ray revealed severe cardiomegaly (Figure 1). The systemic ventricular mass index was calculated to be 54.2 g/m², and the interventricular septum was significantly bulging to the left on transthoracic echocardiography (Figure 2). The patient was electively intubated with worsening oxygenation parameters on blood gas analysis. Appropriate antibiotics were administered intravenously for the treatment of bronchopneumonia. Pretibial edema, hepatomegaly, and crackling rales at the bases of the lungs were unable to be resolved with the administration of moderate to high doses of inotropic support. Clinical status of the patient was unable to be stabilized medically and, therefore, an urgent DSO was scheduled. A written informed consent was obtained from each parent.

Atrial switch (modified Senning procedure) and arterial switch operations were performed. The interior flap was constituted with a polytetrafluoroethylene patch and the outer flap was enlarged with bovine pericardium. Arterial switch procedure was completed following a LeCompte maneuver. Pulmonary artery debanding was, then, performed. The aortic cross-clamping and cardiopulmonary bypass times were 186 and 223 min, respectively. Although the patient was weaned from cardiopulmonary bypass with high dose inotropic support, the systemic ventricle failed at the first postoperative hour at the operating room. Therefore, a left atrium to the ascending aortic mechanical circulatory support was implemented with a centrifugal pump. The functions of the systemic ventricle gradually improved after eight days of mechanical circulatory support. The patient was

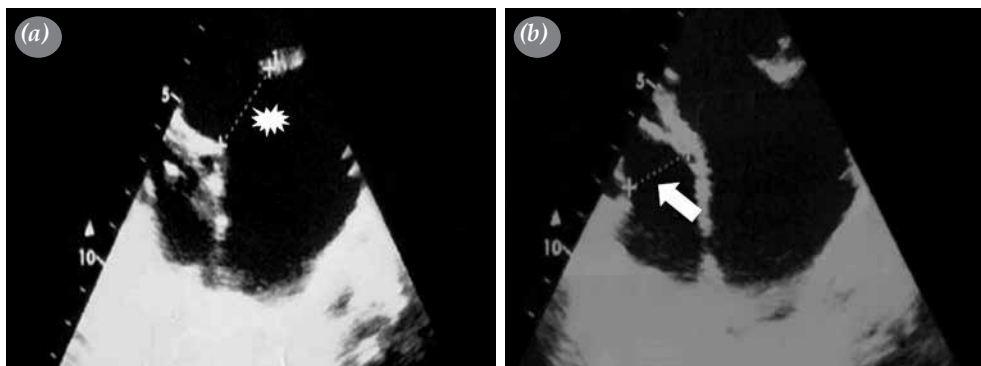


Figure 2. Preoperative transthoracic echocardiography showing significant dilatation of systemic ventricle with an increased diameter of tricuspid annulus. (a) Tricuspid-systemic valve annulus (Asterisk). (b) Mitral-right atrioventricular valve annulus (Arrow).

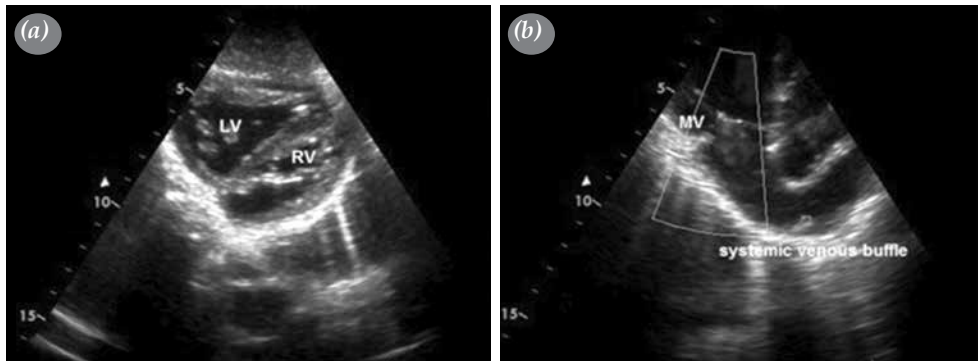


Figure 3. (a) Postoperative transthoracic echocardiography showing left and right ventricles and (b) an unobstructed systemic venous baffle.
LV: Left ventricle; RV: Right ventricle; MV: Mitral valve.

weaned off, when transthoracic echocardiography revealed a LV mass index and Z-score of 115 g/m^2 and 3, respectively (Figure 3). Both AV valves had mild incompetence with a systemic ventricular ejection fraction of 60% at the time of discharge. The patient is still uneventful three years after the DSO.

DISCUSSION

In patients presenting with cc-TGA, PAB is a noteworthy treatment strategy, which have important effects such as systemic ventricular training and prevention of pulmonary overflow, particularly in patients with large ventricular septal defects.^[3] This surgical option has been shown to be associated with improved tricuspid valve function in terms of regurgitation, which is probably related to the modification of the septal geometry following PAB.^[4] Delays in anatomic correction may lead to AV valve and ventricular dysfunction, and timing for a DSO may be based on the criteria of LV mass/volume ratio.^[5] A LV mass/volume ratio and LV mass index are dependable criteria for timing of DSO after PAB.^[3] The assessment of the LV preparedness for a DSO may depend on various parameters. The Stanford University Working Group defined five main parameters to evaluate the LV before the DSO:^[6] LV pressure (90% of systemic pressure), LV systolic function (ejection fraction $>55\%$), LV end-diastolic pressure ($<12 \text{ mmHg}$), mitral valve function (mild or less insufficiency), and LV mass index ($>50 \text{ g/m}^2$ in children and $>65 \text{ g/m}^2$ in adults). The LV mass index of our case was 54.2 g/m^2 . However, we encountered a respiratory infection triggering a clinically poor state with significant heart failure. Although the LV preparedness was borderline, we had to operate the patient for an anatomical repair; otherwise, the expected mortality would be higher.

We performed the DSO and provided a mechanical support with a centrifugal pump between the left atrium to the aorta for the failed ventricle. The patient was weaned off after eight days with satisfactory cardiac functions. The mechanisms for significant increase in the LV mass index in the postoperative period may be speculative, which the result is probably a combination of mechanical circulatory support and positive inotropes. Individual variations in the effects of pressure and volume overload on the ventricular function as well as coronary vascular reserve may influence the end results.^[7] Some reports in the literature support our results with significant increase in the LV mass index over time.^[8] However, at the initial assessment of our case, there were clinical findings of significant acute heart failure probably induced by respiratory tract infection. Assessment of LV mass index and other parameters of contractility may have led to false negative results due to ventricular dilatation.

Double switch operation may be considered as a procedure of choice in the newborn or young infants presenting with congestive heart failure due to systemic valvular regurgitation. Furthermore, the DSO may be the only option to convert the failing tricuspid valve to a low-pressure environment, taking the challenging neonatal Ebsteinoid tricuspid valve repair into consideration.^[9]

In conclusion, although congenitally corrected transposition of the great arteries is a rare cardiac malformation, its treatment mandates a meticulous surgical technique as well as a strict follow-up schedule. We believe that such salvage double switch operations may be encouraged in patients with early ventricular failure and atrioventricular insufficiency in cases where the systemic ventricle is not trained, yet.

A mechanical circulatory support may also provide a time for the systemic ventricle to recover after the procedure.

Declaration of conflicting interests

The authors declared no conflicts of interest with respect to the authorship and/or publication of this article.

Funding

The authors received no financial support for the research and/or authorship of this article.

REFERENCES

1. Brawn WJ, Barron DJ, Jones TJ, Quinn DW. The fate of the retrained left ventricle after double switch procedure for congenitally corrected transposition of the great arteries. *Semin Thorac Cardiovasc Surg Pediatr Card Surg Annu* 2008;69-73.
2. Sebastian VA, Cooley A, Ramaciotti C, Guleserian KJ, Forbess JM. Neonatal double switch for congenitally corrected transposition with Ebstein anomaly and bilateral superior venae cavae. *J Thorac Cardiovasc Surg* 2014;148:e241-2.
3. Bilal MS, Avşar MK, Yıldırım Ö, Özyüksel A, Zeybek C, Küçükosmanoğlu O, et al. Double Switch Procedure and Surgical Alternatives for the Treatment of Congenitally Corrected Transposition of the Great Arteries. *J Card Surg* 2016;31:231-6.
4. Devaney EJ, Charpie JR, Ohye RG, Bove EL. Combined arterial switch and Senning operation for congenitally corrected transposition of the great arteries: patient selection and intermediate results. *J Thorac Cardiovasc Surg* 2003;125:500-7.
5. Bove EL, Ohye RG, Devaney EJ, Kurosawa H, Shin'oka T, Ikeda A, et al. Anatomic correction of congenitally corrected transposition and its close cousins. *Cardiol Young* 2006;16 Suppl 3:85-90.
6. Ibrahimiyeh AN, Mainwaring RD, Patrick WL, Downey L, Yarlagađa V, Hanley FL. Left ventricular retraining and double switch in patients with congenitally corrected transposition of the great arteries. *World J Pediatr Congenit Heart Surg* 2017;8:203-9.
7. Boutin C, Wernovsky G, Sanders SP, Jonas RA, Castaneda AR, Colan SD. Rapid two-stage arterial switch operation. Evaluation of left ventricular systolic mechanics late after an acute pressure overload stimulus in infancy. *Circulation* 1994;90:1294-303.
8. Myers PO, del Nido PJ, Geva T, Bautista-Hernandez V, Chen P, Mayer JE Jr, et al. Impact of age and duration of banding on left ventricular preparation before anatomic repair for congenitally corrected transposition of the great arteries. *Ann Thorac Surg* 2013;96:603-10.
9. Ishibashi N, Aoki M, Fujiwara T. Double switch operation in a young infant. *Cardiol Young* 2004;14:661-3.