



Case Report / Olgu Sunumu

Pleuropulmonary blastoma: A report of two cases

Plöropulmoner blastom: İki olgu sunumu

Ömer Faruk Demir¹, Ömer Önal¹, Leyla Hasdıraz¹, Fahri Oğuzkaya¹, Olgun Kontaş², Ayşe Ülgey³

¹Department of Thoracic Surgery, Erciyes University Faculty of Medicine, Kayseri, Turkey

²Department of Pathology, Erciyes University Faculty of Medicine, Kayseri, Turkey

³Department of Anesthesiology and Reanimation, Erciyes University Faculty of Medicine, Kayseri, Turkey

ABSTRACT

Pleuropulmonary blastoma is a rare and aggressive childhood tumor of mesenchymal origin. It has a poor prognosis and mainly classified as cystic (type 1), mixed type (type 2), and solid (type 3). Herein, we present two cases of pleuropulmonary blastoma type 3 presenting with pneumothorax, a rare clinical presentation of pleuropulmonary blastoma, which was successfully treated with surgery.

Keywords: Pleuropulmonary blastoma, pneumothorax, thoracotomy.

Pleuropulmonary blastoma (PPB) is a rare tumor with a poor prognosis which often affects children under six years of age and is believed to be disemryogenic.^[1] It may be of pleural or pulmonary origin, or both.^[2] In certain cases, the origin cannot be determined.^[2] Although rare, it is still the most frequent primary lung malignancy in childhood.^[3] Pleuropulmonary blastomas are mainly classified as cystic (type 1), mixed type (type 2), and solid (type 3).^[4,5] They may result in local relapse and distant metastasis^[3] and is a part of a tumor spectrum related to DICER1 gene mutation.^[3] It has been also shown to be linked with a disorder of the long arm of chromosome 8.^[1]

In this report, we present two cases of PPB type 3 presenting with pneumothorax, a rare clinical presentation of PPB, which was successfully treated with surgery.

ÖZ

Plöropulmoner blastom çocukluk çağında mezenkimal kökenli, nadir ve agresif bir tümördür. Prognozu kötü olup, başlıca kistik (tip 1), mikst tip (tip 2) ve solid (tip 3) olarak sınıflandırılır. Bu yazıda plöropulmoner blastomun nadir bir klinik tablosu olan pnömotoraksın eşlik ettiği ve cerrahi ile başarılı bir şekilde tedavi edilen iki plöropulmoner blastom tip 3 olgusu sunuldu.

Anahtar sözcükler: Plöropulmoner blastom, pnömotoraks, torakotomi.

CASE REPORT

Case 1- A 32-month-old male child was admitted to the emergency department with severe stomach pain and fever. A right total pneumothorax was detected on chest X-ray, when no respiratory sounds were heard on the right side, and a chest tube was inserted. Clinical symptoms of the patient relieved following the insertion of the chest tube and a giant bulla type image was detected on thoracic computed tomography (CT). A written informed consent was obtained from each parent and the patient underwent video-assisted thoracoscopic surgery (VATS) and the bulla was removed from the thorax with complete excision. The patient presented with sudden high fever and coughs during the fifth month of follow-up, and a large opacity on the right side was detected on chest X-ray (Figure 1). Thoracic CT revealed fluid collection with regular limited density on the right side. A VATS was

Received: May 19, 2019 Accepted: November 01, 2019 Published online: January 23, 2020

Correspondence: Ömer Faruk Demir, MD. Erciyes Üniversitesi Tıp Fakültesi Göğüs Cerrahisi Anabilim Dalı, 38030 Melikgazi, Kayseri, Türkiye.
Tel: +90 352 - 207 66 66 / 22203 e-mail: ofdemir@erciyes.edu.tr

Cite this article as:

Demir ÖF, Önal Ö, Hasdıraz L, Oğuzkaya F, Kontaş O, Ülgey A. Pleuropulmonary blastoma: A report of two cases. Turk Gogus Kalp Dama 2020;28(1):209-212

initiated; however, right thoracotomy was switched due to severe adhesions and possible surgical complications and poor health status. During thoracotomy, a mass, which was considered lung initially, was observed toward the right lower lobe. The lesion was controlled and it was observed to be a mass originating from the pleural base covered with a thin and fragile capsule. The lesion was completely removed from the diaphragmatic region in which it originated. However, it was not possible to remove the fragile lesion as a single piece. The patient was discharged five days later without any complications.

Case 2- A 12-month-old female patient was admitted to our institution with a foreign body aspiration diagnosis, after she started crying while playing with a balloon filled with fluid. A chest tube was inserted in the patient after detecting total pneumothorax on chest X-ray. No foreign body was detected in the rigid bronchoscopy. A cavitory lesion with a diameter of approximately 12 mm was observed on CT in the right chest upper lobe anterior segment. A written informed consent was obtained from each parent and a right thoracotomy was performed, and an air leak focus was observed in the right lung upper lobe and

a linear stapler was applied. At six-month follow-up, the patient was hospitalized after detecting a right-sided distinctive opacity on chest X-ray and thoracic CT revealed findings compatible with the presence of a pneumothorax 4 cm in diameter in the anterior section of the right hemothorax and a 5×7-cm lesion in the vicinity of this air appearance for which fluid mass distinction was unable to be made. A lesion with indistinct borders and a cystic appearance was observed in the thoracic cavity after right thoracotomy was performed. The primary origin of the mass remained undetermined. The lesion was separated from the thymus surface via wedge resection. Similarly, the parenchyma of the lung was subjected to wedge resection (Figure 2). The patient was discharged after chest tube removal with suggestions.

Histopathological examination showed neoplastic tissues consisting of spindle and some pleomorphic cells. Cystic areas were only observed as microscopic foci and tumoral tissue was completely solid. Neoplastic cells showed diffuse vimentin positivity. There was focal desmin and myogenin positivity showing rhabdomyoblastic differentiation. The result was reported as PPB type 3 in both patients.

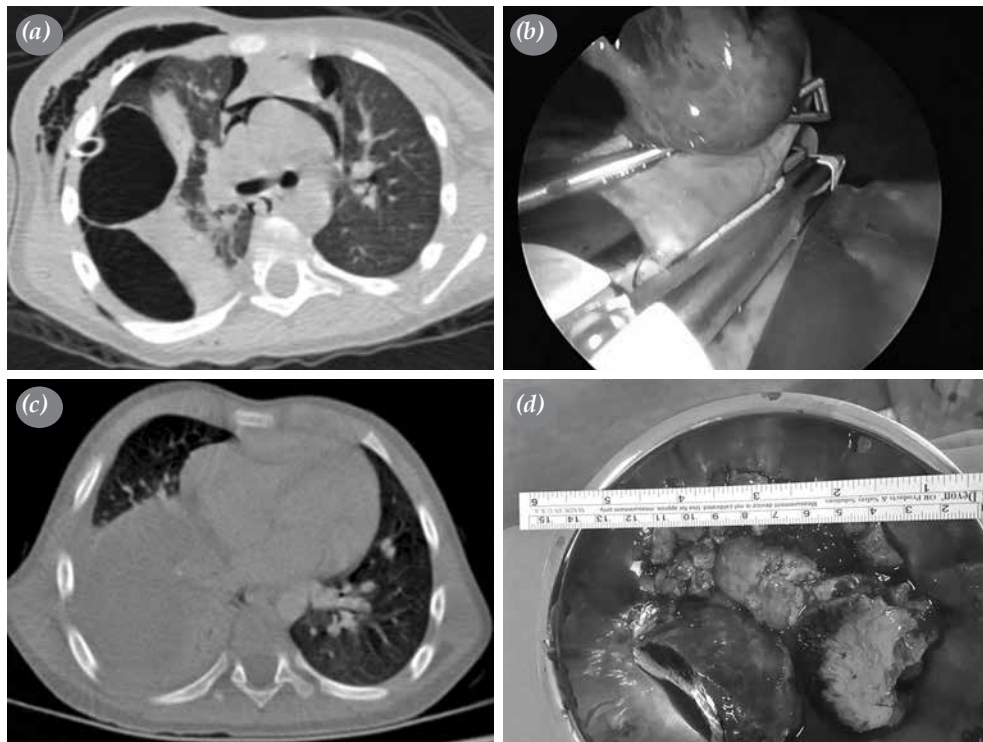

Figure 1. (a) First application, a giant bulla on thoracic CT. (b) First surgery, resection by endoscopic linear stapler of giant bulla. (c) Second application, second surgery for mass, resected tumor tissue (d) Surgical specimen (Case 1).

CT: Computed tomography.

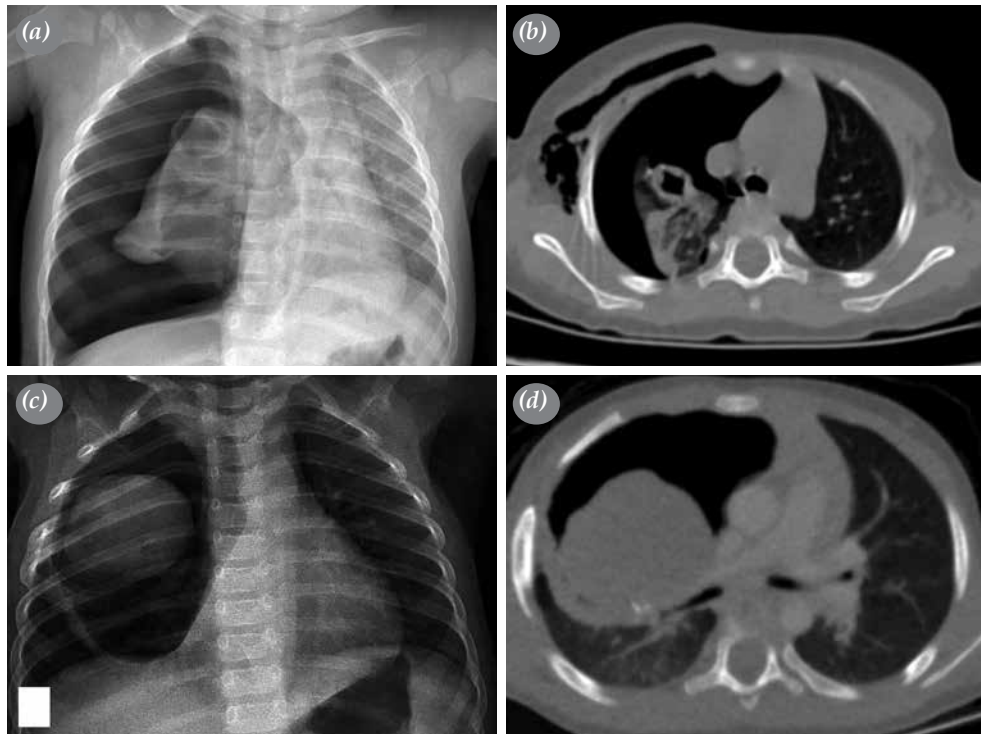


Figure 2. (a) First application with pneumothorax. (b) Cavitory lesion on right upper lobe. (c) Second application, an opacity seen in right superior lobe on chest X-ray. (d) a 5x7-cm lesion (Case 2).

DISCUSSION

The majority of tumors of the thorax in childhood are comprised of metastases of malignancies outside the thorax.^[2] Primary malignant thoracic tumors account for less than 1% of all pediatric malignancies.^[6] Pleuropulmonary blastoma was first described in 1988 based on presentation of the histopathological and clinical characteristics of this mesenchymal cell-based disease.^[2] Later on, the International Pleuropulmonary Blastoma Registry (IPPBR) and European Cooperative Study Group for Pediatric Rare Tumors (EXPERT) studies collected data on this rare disease and put forth definitions related to the diagnosis, treatment, and follow-up of PPB.^[1,7]

Clinical presentation of PPBs include complaints resembling respiratory system infections such as coughing, fever, and shortness of breath.^[7] Therefore, patients are often misdiagnosed with upper respiratory tract infections.

Surgery is the primary method of treatment. Thoracotomy is performed and total mass excision is recommended. However, many studies have shown that subtotal resection is also acceptable. Although

there is currently no established chemotherapy regimen, different protocols with doxorubicin have been used in the treatment. In addition, the effect of radiotherapy on PPBs has not been determined, yet.^[1,7] However, the mean disease-free survival (DFS) and overall survival (OS) have been more clearly defined in recent years. Five-year DFS and OS rates have been reported as 82% and 91%, respectively for type 1 disease, 59% and 37%, respectively for type 2 disease, and 71% and 53%, respectively for type 3 disease.^[7]

In the literature, there are patients similar to our cases who underwent surgery following the presentation with pneumothorax complaints without histopathological or intraoperative detection of a tumor, but in whom a PPB was diagnosed about six months after surgery and underwent a further surgical treatment.^[8] In such cases, cystic lung disease may be a precursor of PPB.^[8] Although it has been indicated in both EXPERT and IPPBR studies that all three types can transform into one another and cystic lesions are indicated in some cases as precursors, the exact mechanisms remain unclear. Further studies are, therefore, warranted.

In conclusion, pleuropulmonary blastoma should be kept in mind in the early stage for pediatric cases presenting with spontaneous pneumothorax complaints and close follow-up on a monthly basis is recommended for these patients, since pleuropulmonary blastoma may grow rapidly within six months.

Declaration of conflicting interests

The authors declared no conflicts of interest with respect to the authorship and/or publication of this article.

Funding

The authors received no financial support for the research and/or authorship of this article.

REFERENCES

1. Bisogno G, Brennan B, Orbach D, Stachowicz-Stencel T, Cecchetto G, Indolfi P, et al. Treatment and prognostic factors in pleuropulmonary blastoma: an EXPeRT report. *Eur J Cancer* 2014;50:178-84.
2. Manivel JC, Priest JR, Watterson J, Steiner M, Woods WG, Wick MR, et al. Pleuropulmonary blastoma. The so-called pulmonary blastoma of childhood. *Cancer* 1988;62:1516-26.
3. Dishop MK, Kuruvilla S. Primary and metastatic lung tumors in the pediatric population: a review and 25-year experience at a large children's hospital. *Arch Pathol Lab Med* 2008;132:1079-103.
4. Priest JR, Williams GM, Hill DA, Dehner LP, Jaffé A. Pulmonary cysts in early childhood and the risk of malignancy. *Pediatr Pulmonol* 2009;44:14-30.
5. Hill DA, Jarzembowski JA, Priest JR, Williams G, Schoettler P, Dehner LP. Type I pleuropulmonary blastoma: pathology and biology study of 51 cases from the international pleuropulmonary blastoma registry. *Am J Surg Pathol* 2008;32:282-95.
6. Priest JR, Watterson J, Strong L, Huff V, Woods WG, Byrd RL, et al. Pleuropulmonary blastoma: a marker for familial disease. *J Pediatr* 1996;128:220-4.
7. Messinger YH, Stewart DR, Priest JR, Williams GM, Harris AK, Schultz KA, et al. Pleuropulmonary blastoma: a report on 350 central pathology-confirmed pleuropulmonary blastoma cases by the International Pleuropulmonary Blastoma Registry. *Cancer* 2015;121:276-85.
8. Calabria R, Srikanth MS, Chamberlin K, Bloch J, Atkinson JB. Management of pulmonary blastoma in children. *Am Surg* 1993;59:192-6.