

Concomitant Cardiac and Pulmonary Operations

A. Kürşat BOZKURT, Levent GÜVENDİK

Cardia Thoracic Surgery Castle Hill Hospital Hull, United Kingdom

To assess the incidence of asymptomatic pulmonary lesions, the records of 500 consecutive patients who were referred by different physicians for open heart surgery, were reviewed. Three patients (0.6%) were found to have pulmonary pathology of indeterminate aetiology. Pulmonary resections were performed through median sternotomy before (two cases) or after cardiopulmonary bypass (one case). One lobectomy, one wedge resection and one excision of the bulla were carried out. Histopathological examination revealed adenocarcinoma, chondroadenoma and subpleural bulla, respectively. There were no postoperative complications.

The incidental finding of pulmonary lesion in patients who were referred for cardiac surgery is 0.6 per cent in this series and would stress the importance of careful preoperative evaluation of the chest x-rays by the cardiac surgical team. This limited experience with three patients suggests that simultaneous pulmonary and cardiac operations can be performed safely and offer the advantage of avoiding two separate operations.

GKD Cer Derg 1995;3:232-235

With the increasing frequency of heart operations performed, cardiac surgeons are likely to see incidental pulmonary lesions of indeterminate aetiology in a small number of patients. In those patients concomitant pulmonary resection has not been a universally accepted procedure because of the increased risk of bleeding due to heparinisation, limited surgical exposure via the median sternotomy and dissemination of the disease as a result of altered cellular and humoral immunity on extracorporeal circulation⁽¹⁾. Consequently references in the literature to concomitant cardiac and pulmonary surgery are sparse^(2,3,4,5).

The hospital records of 500 consecutive patients, who underwent cardiac operations over a period of two years, were reviewed retrospectively. All

operations were performed by the same surgeon (LG). Three patients had pulmonary lesions which were detected incidentally.

Case report 1: A sixty-six year old man, who was initially diagnosed as having aortic stenosis with a gradient of 70 mmHg 4 years previously. A chest x-ray was clear at the time. He declined to have an operation and was followed up 6 monthly without a change in his transaortic gradient. He gradually developed angina pectoris. Coronary angiography revealed a critical proximal LAD stenosis. He was then referred to our unit for aortic valve replacement and coronary artery bypass grafting. At the first outpatient visit, a peripheral opacity in the right lower lobe was noted.

A CT scan of the thorax confirmed the well rounded opacity which showed spiculation, lobulation and central cavitation without lymph node involvement to be consistent with a bronchogenic carcinoma (Figures 1,2).

Therefore a decision was made to proceed to combined pulmonary resection, aortic valve replacement and coronary artery bypass grafting. Following median sternotomy, the right pleura was opened, the lesion was biopsied and frozen section was reported as possible adenocarcinoma. A right lower lobectomy was carried out before heparinisation.

Aortic valve replacement and left internal mammary grafting to the left anterior descending artery was performed with full heparinisation on cardiopulmonary bypass. The histopathology report showed adenocarcinoma with clear resection margins and tumour-free

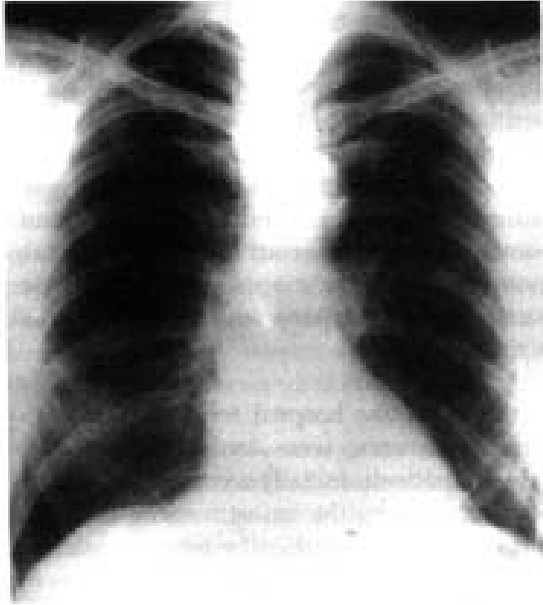

Figure 1. The peripheral opacity in the right lower lobe (Case 1).

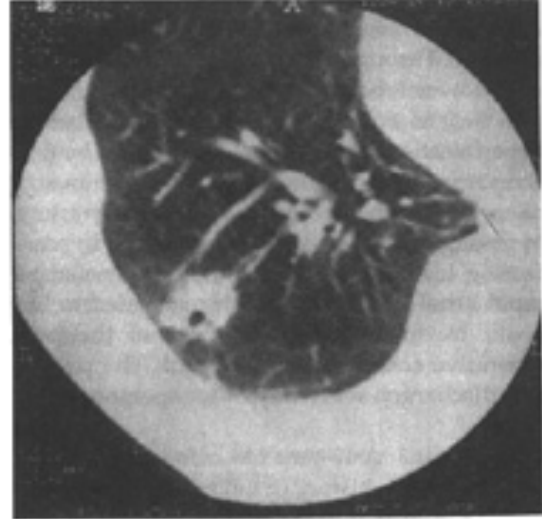


Figure 2. CT scan of the chest showing the well rounded opacity with central cavitation (Case 1).

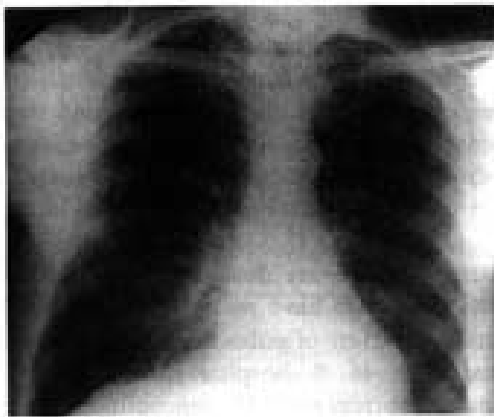


Figure 3. Chest x-ray showing a opacity in right lower lobe (Case 2).

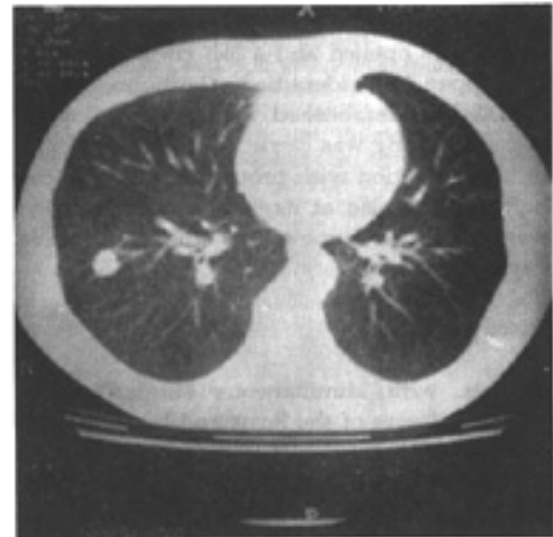


Figure 4. CT scan of the chest which shows a well-defined 1.5 cm nodule in the right lower lobe (Case 2).

interlobar glands. This patient was discharged home on the 7th postoperative day without complication. He was totally asymptomatic with no evidence or tumour recurrence 12 months after the operation.

Case report 2: A sixty-five year old male presented with moderately severe exertional angina pectoris. Coronary angiography showed triple vessel coronary artery disease and he was

therefore referred for coronary artery bypass grafting. A routine chest x-ray showed a opacity in right lower lobe (Figure 3). Consequently, the patient was investigated with a CT scan of the chest which showed a welldefined 1.5 cm nodule in the right lower lobe (Figure 4).

There was no calcification within the mass and a bronchial neoplasm remained the likely diagnosis. Through a median sternotomy the right lower lobe lesion measuring 2.5x1.5 cms was excised and sent for frozen section before heparinisation. The report suggested benign chondroadenoma with no evidence of malignancy. It was then proceeded to coronary artery bypass grafting on cardiopulmonary bypass. During his postoperative course he developed rapid atrial fibrillation which responded to Digoxin treatment. The remainder of the postoperative course was uneventful. The patient was discharged seven days after operation.

Case report 3: A 49-year-old man was admitted with a 6 month history of moderately severe angina of effort and occasional rest pain. Coronary angiography revealed triple vessel coronary artery disease and he was then referred for coronary artery bypass grafting. A preoperative chest x-ray revealed a bulla in the left apex. Following median sternotomy the left pleura was opened and a 3x3 cm bulla in the left upper lobe identified. Cardiopulmonary bypass grafting was carried out. After reversal of heparinisation with protamine sulphate, the bulla was stapled at its base and excised. He was discharged home on the 6th postoperative day.

Discussion

Patients with simultaneous surgically correctable disease of the heart and lungs are not unusual. A recent report from the Mayo Clinic documented 1 per cent concomitant pulmonary resection in a group of 28,604 adult open heart operations and this was the largest series reported so far⁽²⁾. These patients usually present with surgically correctable cardiac disease and an incidental pulmonary lesion, detected on the preoperative chest x-ray.

In general, surgeons are reluctant to perform pulmonary operations combined with open heart surgery. Intrapulmonary bleeding due to systemic heparinisation and altered coagulation mec-

hanism after cardiopulmonary bypass are the major concerns. The other disadvantage is compromised exposure for pulmonary resection and lymph node sampling for staging through median sternotomy. Consequently many cardiothoracic surgeons advocate staged procedures⁽³⁾. However from the patients standpoint, it is advantageous to have a slightly more extensive single operation than two separate major operations within a short period of time.

In this study the hospital records of 500 consecutive patients, were analysed retrospectively. All patients, initially were seen in the outpatients clinic by the senior surgeon (LG) and subsequently operated on by him or under his direct supervision. Three patients (3/500) were diagnosed as having asymptomatic pulmonary lesions, two solitary nodules and one bulla. Each lesion was confirmed with CT scan of the chest. Both solitary nodules were peripheral lesions without mediastinal lymph node involvement and were amenable to resection through a median sternotomy.

Piehler et al reported 43 patients who underwent concomitant pulmonary and cardiac procedures⁽⁴⁾. Forty patients (93%) presented with cardiac symptoms and 3 with pulmonary signs and symptoms (7%). Thirty-one patients had benign pulmonary disease (72.15) and 12 (27.9%) proved to have malignant lesions. In this study, a variety of pulmonary lesions were resected with 46% hospital mortality. Yokoyama et al reported 11 concomitant pulmonary resections for bronchial carcinoma in a total of 2909 adult cardiac surgical procedures. In each patient asymptomatic pulmonary lesion was found on preoperative chest x-ray films. There were no major postoperative complication related to the cardiac or pulmonary procedures among 11 patients.

Recently Miller et al reported Mayo Clinic experience with 30 patients who underwent open heart surgery and pulmonary resection for carcinoma of the lung⁽²⁾. Twenty-five (83.3%) of the resections performed either before or after

cardiopulmonary bypass and the remaining 5 on bypass. There were 2 operative deaths, one myocardial ischemia secondary to graft occlusion and one due to the acute respiratory distress syndrome. Two re-explorations for bleeding were carried out. The most striking finding in this study was the five-year survival for stage I patients in the concomitant resection group was 36.5%. This was significantly worse than the control stage I group patients who underwent pulmonary resection in a staged fashion with a five-year survival rate of 100%.

They attribute this difference to the inadequate lymph node evaluation and underestimation of the extent of the disease at the time of combined surgery. From the patients point of view, it would be logical to perform two procedures during the same operation. However technical considerations must be taken into account and patient management should be individualised. Large central tumours, tumours with chest wall involvement or extensive lymph node involvement and superior sulcus tumours should be treated in a staged fashion. Unilateral lung ventilation with a staged fashion. Unilateral lung ventilation with a double lumen endotracheal tube and mechanical staplers are important to facilitate the resection. It is safer to perform

pulmonary resection before heparinisation in order to avoid bleeding complications.

The exposure of the hilar structures on the left site may be difficult and unsafe, therefore decompressing the heart by cardiopulmonary bypass may assist the procedure in selected patients. In summary, our limited experience, suggest that concomitant cardiac and pulmonary procedures can be safely performed in carefully selected patients and eliminates the morbidity associated with a second operation.

References

1. Peters RM, Swain JA: Management of the patient with emphysema, coronary artery disease and lung cancer. *Am J Surg* 1982; 143:701-5.
2. Miller DL, Orszulak TA, Pairolero PC, Trastek VF, Schaff HV: Combined operation for lung cancer and cardiac disease. *Ann Thorac Surg* 1994; 58:978-88.
3. Yokoyama T, Derrick MJ, Lee AW: Cardiac operation with associated pulmonary resection. *J Thorac Cardiovasc Surg* 1993; 105:912-17.
4. Pichler JM, Trastek VF, Pairolero PC, Pluth JR, Danielson GK, Schaff HV, Orszulak TA, Puga FJ: Concomitant cardiac and pulmonary operations. *J Thorac Cardiovasc Surg* 1985; 90:662-67.
5. Canver CC, Bhayana JN, Lajos TZ, Raza ST, Lewin AN, Bergsland J, Mentzer RM: Pulmonary resection combined with cardiac operations. *Ann Thorac Surg* 1990; 50:769-9.

Correspondence: Levent Güvendik MD, Castle Hill Hospital, Castle Road, Cottingham, Hull, United Kingdom, HU16 5JQ
