

## Heart transplant recipient survivor from COVID-19: The first case of Turkey

*Sağ kalan kalp nakil alıcısında COVID-19: Türkiye'den ilk olgu*

Güle Çınar<sup>1</sup>, Cahit Sarıcaoğlu<sup>2</sup>, Bahadır İnan<sup>2</sup>, İrem Dinçer<sup>3</sup>, Mehmet Çakıcı<sup>2</sup>,  
Tamer Sayın<sup>3</sup>, Alpay Azap<sup>1</sup>, Ahmet Rüşan Akar<sup>2</sup>

<sup>1</sup>Department of Infectious Diseases and clinical Microbiology, Ankara University School of Medicine, Ankara, Turkey

<sup>2</sup>Department of Cardiovascular Surgery, Ankara University School of Medicine, Ankara, Turkey

<sup>3</sup>Department of Cardiology, Ankara University School of Medicine, Ankara, Turkey

### ABSTRACT

Any highly infectious and rapidly spreading disease is a primary concern for immunocompromised solid organ transplant recipients. The number of data about the spectrum of clinical illness, the treatment modalities, and the outcomes of COVID-19 in this vulnerable population is scant and still remains empirical. Herein, we report the first COVID-19 case of a heart transplant recipient in Turkey who presented with fever, postnasal discharge, and myalgias for two days. The possibility of lung involvement was ruled out by thoracic computed tomography. Despite stable vital signs, we reduced the intensity of immunosuppressive therapy and maintained home self-isolation promptly. We also commenced a five-day course of hydroxychloroquine 200 mg q12h initially. After confirmation of real-time reverse-transcriptase-polymerase-chain-reaction testing of the nasopharyngeal swab positive for COVID-19, the patient was hospitalized. After a loading dose of favipiravir 1,600 mg b.i.d., the patient received a five-day course of favipiravir 600 mg q12h. He was discharged with cure after 23 days of hospital isolation and treatment. In conclusion, treatment process can be affected by the daily electrocardiography, hand-held portable echocardiography, myocardial injury markers, and pulse oximeter for self-monitoring in the follow-up of previous heart transplant recipients suffering from COVID-19. The lack of treatment protocols in the solid organ transplant recipients with COVID-19 infection and the controversies about the protective effect of immunosuppression invite a global and update discussion.

**Keywords:** COVID-19; heart transplantation; immunocompromised.

### ÖZ

Oldukça bulaşıcı ve hızla yayılan herhangi bir hastalık, bağışıklığı zayıflamış solid organ nakli alıcıları için başlıca endişe kaynağıdır. Bu savunmasız popülasyonda klinik hastalık spektrumu, tedavi yöntemleri ve COVID-19 sonuçlarına ilişkin veriler yetersizdir ve halen ampirik düzeyde kalmaktadır. Bu yazıda, iki gün boyunca ateş, postnazal akıntı ve miyalji ile başvuran bir kalp nakli alıcısında Türkiye'deki ilk COVID-19 olgusu sunuldu. Akciğer tutulumu olasılığı, toraks bilgisayarlı tomografisi ile dışlandı. Stabil seyreden vital bulgulara rağmen, immünsüpresif tedavi yoğunluğu azaltıldı ve hasta derhal evde izolasyona alındı. Ayrıca başlangıçta her 12 saatte bir 200 mg olmak üzere beş gün süreyle hidroklorokin başlandı. Nazofarengeal sürüntü örneğinde COVID-19 için gerçek zamanlı revers transkriptaz polimeraz zincir reaksiyon testinin pozitifliği doğrulandıktan sonra, hasta hastaneye yatırıldı. Günde iki kez 1600 mg favipiravir yükleme dozundan sonra, beş gün süreyle her 12 saatte bir 600 mg favipiravir verildi. Hasta, 23 günlük hastane izolasyonu ve tedaviden sonra şifa ile taburcu edildi. Sonuç olarak, kalp nakli geçirmiş bir alıcının COVID-19 hastalığı mücadelesinde günlük elektrokardiyografi, günlük portatif ekokardiyografi, miyokard hasarının belirleyicileri ve oksimetre ile saturasyon takipleri tedavi süreçlerini etkileyebilir. COVID-19 ile enfekte olan solid organ nakli alıcılarında tedavi protokollerinin eksikliği ve immünsüpresyonun koruyucu etkisine ilişkin çelişkiler, evrensel ve güncel bir tartışma gerektirmektedir.

**Anahtar sözcükler:** COVID-19; kalp nakli; immün yetmezlikli.

Received: June 10, 2020 Accepted: August 11, 2020 Published online: October 21, 2020

**Correspondence:** Ahmet Rüşan Akar, MD. Ankara Üniversitesi Tıp Fakültesi Kalp ve Damar Cerrahisi Anabilim Dalı, 06590 Çankaya, Ankara, Türkiye.  
Tel: +90 312 - 595 60 84 e-mail: akarruchan@gmail.com

### Cite this article as:

Çınar G, Sarıcaoğlu C, İnan B, Dinçer İ, Çakıcı M, Sayın T, et al. Heart transplant recipient survivor from COVID-19: The first case of Turkey. Turk Gogus Kalp Dama 2020;28(4):674-679

©2020 All right reserved by the Turkish Society of Cardiovascular Surgery.

This is an open access article under the terms of the Creative Commons Attribution-NonCommercial License, which permits use, distribution and reproduction in any medium, provided the original work is properly cited and is not used for commercial purposes (<http://creativecommons.org/licenses/by-nc/4.0/>).

The coronavirus disease 2019 (COVID-19) outbreak for solid organ transplant (SOT) recipients is exceptionally complex and dynamic.<sup>[1-3]</sup> The limited data on the impact of the COVID-19 infection on SOT recipients lead to several assumptions. Firstly, SOT recipients are at a higher risk of morbidity and mortality from COVID-19, due to their current immunosuppressed state.<sup>[1]</sup> However, others argue that host-inflammatory response appears to be milder, possibly due to the concomitant use of immunomodulatory drugs in SOTs.<sup>[4,5]</sup> Secondly, advanced age, presence of comorbidities such as hypertension, coronary artery disease, heart failure, obesity, and diabetes are the primary risk factors of myocardial injury during COVID-19 infection.<sup>[6,7]</sup> Indeed, heart transplant recipients have usually numerous comorbidities.

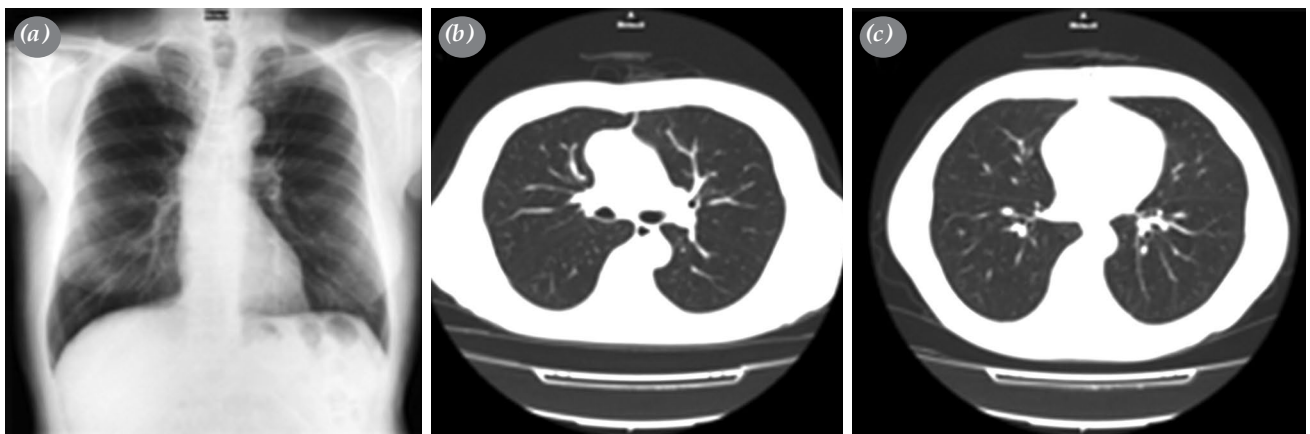
The Republic of Turkey, Ministry of Health (Tr MoH) reported the first COVID-19 case on March 11<sup>th</sup>, 2020 and the first death due to COVID-19 on March 16<sup>th</sup>, 2020 in Turkey.<sup>[8]</sup> As of June 4<sup>th</sup>, 2020, the number of patients with COVID-19 in Turkey exceeds 166,422 with a total of 4,609 fatalities.<sup>[8]</sup> Currently, there are only few reports about the outcomes of heart transplant patients with COVID-19 infection in the literature.<sup>[4,9]</sup>

### CASE REPORT

On April 6<sup>th</sup>, 2020, a 64-year-old man (weight 78 kg; height 170 cm, and body surface area 1.89 m<sup>2</sup>) presented to the outpatient clinic with the symptoms of COVID-19 infection complaining of intermittent fever (maximal temperature: 38.2°C), postnasal discharge, and myalgias. He denied cough, sore throat, shortness of breath, gastrointestinal symptoms, or anosmia. He had a history of orthotopic heart transplantation bridged from

veno-arterial extracorporeal membrane oxygenation (VA-ECMO) for post-infarction refractory cardiogenic shock in December 2013. The marginal donor was a 58-year-old male with a history of hypertension and left ventricular hypertrophy. His post-transplant course was unremarkable except for hypertension, with no episodes of rejection. On further discussion with the patient, he stated that his wife was a pharmacist and COVID-19-positive for two days. Nasopharyngeal and oropharyngeal swabs tested negative for severe acute respiratory syndrome-coronavirus-2 (SARS-CoV-2) by real-time reverse-transcriptase-polymerase-chain-reaction (RT-PCR) assay. No compliant finding with COVID-19 was detected on chest radiograph or computed tomography (CT) (Figure 1). Electrocardiography showed sinus rhythm, 76 bpm with the previously confirmed right bundle branch block. The complete blood count analysis revealed mild leukopenia and lymphopenia. C-reactive protein (CRP) was mildly elevated to 6.1 mg/L (normal range: 0 to 5 mg/L) (Table 1). Considering the history of his close contact, we commenced on hydroxychloroquine 200 mg q12h, self-isolated in a separate home from his wife - the treatment targeted for symptomatic relief at this stage under close follow-up with self-measured pulse oximeter.

The repeated RT-PCR assay of a nasopharyngeal swab on April 7<sup>th</sup>, 2020 tested positive for SARS-CoV-2 and the patient was hospitalized and isolated. On arrival, the body temperature was 36.8°C with a pulse rate of 82 bpm, a blood pressure of 130/80 mmHg, a respiratory rate of 20 breaths/min, and an oxygen saturation of 97% on room air. Auscultation of the chest revealed natural breathing sounds. He did not require oxygen supplementation. According to the blood chemistry tests, mild leukopenia and lymphopenia persisted.



**Figure 1.** (a) A posteroanterior chest radiograph. (b, c) Thoracic computed tomography scans on April 6<sup>th</sup>, 2020 (Day 2) showing no COVID-19-related abnormalities.

**Table 1. Laboratory test results**

Measure	Reference range	Illness Day 2	Illness Day 4, Hospital Day 1	Illness Day 6, Hospital Day 3	Illness Day 7, Hospital Day 4	Illness Day 8, Hospital Day 5	Illness Day 9, Hospital Day 6	Illness Day 11, Hospital Day 8	Illness Day 13, Hospital Day 10	Illness Day 15, Hospital Day 12	Illness Day 17, Hospital Day 14	Illness Day 19, Hospital Day 16	Illness Day 23, Hospital Day 18
White-cell count (per L)	4.5-11×10 <sup>9</sup>	4.46	3.89	3.06	2.08	3.52	3.08	3.33	3.0	2.89	5.87	3.10	3.43
Lymphocyte count (per L)	1.5-4×10 <sup>9</sup>	0.83	0.70	0.90	0.98	1.23	0.86	1.11	1.09	1.11	1.34	0.92	1.24
Platelet count (per L)	150-400×10 <sup>9</sup>	123	127	122	118	120	146	164	163	151	186	180	163
C-reactive protein (mg/L)	0-5	6.1	5.2	5.2	5.1	4.8	8.7	8	6.2	3	3.8	6.2	1.8
Neutrophil lymphocyte ratio	1-2.8	3.3	3.94	2	0.86	1.61	2.13	1.68	1.42	1.32	3.01	2.01	1.47
D-dimer (ng/mL)	0-243	68	74	67	65	59	112	58	70	42	50	62	58
Ferritin (ng/mL)	23-336	-	33	-	52.4	52.6	61.4	70.9	-	56.2	-	46.5	47.6
Troponin (pg/mL)	0-14	12.7	-	9.6	9.6	9.2	10.8	10.2	9.7	9.6	9.7	9.6	11.1
NT-proBNP (pg/mL)	0-125	-	-	185	126	117	164	106	101	82	102	-	115
Fibrinogen (g/L)	2-3.93	-	-	-	3.5	3.62	4.46	4.46	3.62	3.62	3.53	3.33	-
Procalcitonin (ng/ml)	0.05-0.5	0.063	-	-	-	0.033	0.042	0.045	0.034	0.032	0.036	-	<0.02
Lactatedehydrogenase (U/L)	0-248	185	203	188	169	502	166	173	368	159	186	-	179
Lactate (mmol/L)	0.5-2.2	-	-	-	-	-	1.08	0.89	-	0.77	-	-	-
Cyclosporinlevelat 2 <sup>nd</sup> h (ng/mL)	400-600	-	509	786	-	-	-	403	-	-	272	-	509
Maximal body temperature (°C)		37.2	38.3	37.8	36.7	36.7	36.1	36.1	36.6	36.6	36.4	36.6	36.8

NT-proBNP: N-terminal pro-brain natriuretic peptide.

Laboratory results showed normal renal and hepatic function. His immunosuppressive regimen consisted of cyclosporine A 100 mg q12h and mycophenolic acid 360 mg q12h. The dose of cyclosporine was adjusted as 75 mg q12h to achieve a cyclosporine level between 400 and 600 ng/mL at 2h. Other medications were pantoprazole 40 mg per day, acetylsalicylic acid 100 mg per day, candesartan 8 mg per day, and pravastatin sodium 20 mg per day.

Following hospitalization, hydroxychloroquine therapy was discontinued. After a loading dose of favipiravir 1,600 mg b.i.d., 600 mg q12h maintenance dose was initiated under the recommendations of the Coronavirus Scientific Advisory Board of the Tr MoH. Prophylactically, subcutaneous enoxaparin sodium 0.4 mL was commenced q12. Daily electrocardiogram monitoring was performed with particular attention to QT prolongation, and no additional findings were detected. Handheld portable echocardiography revealed a mildly dilated left atrium, hypertrophic myocardium, and abnormal interventricular septal movement with normal left ventricular function. The need for oxygen did not arise. Favipiravir treatment was completed in five days and discontinued thereafter. On Day 23 of the disease, two PCR tests-24-h apart-were negative for COVID-19. The patient was discharged on mycophenolate sodium 360 mg b.i.d. and cyclosporine 100 mg b.i.d.

A written informed consent was obtained from the patient.

## DISCUSSION

Our report of the first confirmed case of COVID-19 in a heart transplant recipient in Turkey illustrates a mild form of the disease, but with unique challenges. At the time of the diagnosis of this case, no formal guidelines were available for the optimal treatment of COVID-19 infection and for the management of immunosuppression in heart transplant recipients. The SOT recipients are at an increased risk of acquisition of COVID-19 infection and progression to severe disease.<sup>[10]</sup> Furthermore, multiple off-label and investigational drugs may interact with immunosuppressive regimens. Some have severe cardiac side effects. However, data have been rapidly accumulated on this subject.<sup>[1,2]</sup>

The initial report from China, with two heart transplant recipients with COVID-19, revealed both severe and mild forms of the disease.<sup>[4]</sup> One patient progressed to respiratory failure, which required the administration of intravenous human gamma globulin and a five-day course of methylprednisolone 80 mg/day; however, both patients survived eventually.

On the contrary, others support corticosteroid-sparing immunosuppression with dose reduction in antiproliferative therapy.<sup>[11]</sup> In case of significant lymphopenia on clinical presentation, Hsu *et al.*<sup>[12]</sup> suggested withholding mycophenolate mofetil. The authors continued tacrolimus and prednisone in a dual heart and kidney transplant recipient. Recently, donor-specific Class II antibodies were detected in a pediatric heart transplant with COVID-19 infection.<sup>[9]</sup> The authors administered intravenous immunoglobulin for desensitization with no adverse outcomes. To date, the most extensive case series, including 28 recipients with a heart transplant who had confirmed COVID-19 infection was reported from New York, US by Latif *et al.*<sup>[3]</sup> Twenty-two patients (79%) were admitted to hospital, seven patients (25%) required mechanical ventilation, and evidence of myocardial injury was present in 13 (77%) patients. The case fatality rate was 25% in this heart transplant cohort with COVID-19. The authors discontinued mycophenolate mofetil in 16 (70%) patients and reduced the dose of calcineurin inhibitors in six patients (26%).

Similarly, we preferred dose reduction in our case instead of cessation of immunosuppression or corticosteroid/immunoglobulin administration. Another issue in heart transplant recipients with COVID-19 infection is the monitoring of cardiac injury biomarkers, daily electrocardiography, and echocardiographic monitoring, which are all critical. After our first case, we suggest that heart transplant recipients who have mild COVID-19 symptoms and no evidence of myocardial injury can be isolated at home to avoid in-person contact. Pulse oximeter self-monitoring may be a useful adjunct for the decision for hospitalization during close daily follow-up. Handheld echocardiography may be also a useful adjunct in monitoring cardiac injury, as well as the biochemical markers during the COVID-19 crisis. Availability at the COVID-19 clinic, examination at the bedside, and the ease of equipment disinfection are the potential advantages.

*In vitro* assays have shown that hydroxychloroquine exerts antiviral activity against certain viruses, such as influenza A and B viruses.<sup>[13]</sup> Several studies have reported that it can also inhibit SARS-CoV-2 *in vitro*, suggesting that it may have utility in fighting against COVID-19.<sup>[14]</sup> However, hydroxychloroquine is known to be associated with significant side effects, including QTc interval prolongation, Torsades de Pointes, and ventricular arrhythmias.<sup>[15]</sup> Even fatal arrhythmias have been also reported.<sup>[15]</sup> Therefore, the use of hydroxychloroquine should be avoided in patients with

congenital long QT syndrome, persistent corrected QT measurements >500 msec, bradycardia, history of ventricular arrhythmias, uncorrected hypokalemia and hypomagnesemia, recent myocardial infarction, or uncompensated heart failure and for patients receiving other drugs which prolong the QT interval and those with heart diseases.<sup>[16]</sup>

Although a decision to administer favipiravir was based on the recommendations of the Coronavirus Scientific Advisory Board of the Tr MoH, caution is still required. Favipiravir was originally developed and licensed as an anti-influenza drug in Japan.<sup>[17]</sup> Favipiravir triphosphate is a purine nucleoside analog, which functions as a competitive inhibitor of ribonucleic acid (RNA)-dependent RNA polymerase. It is a prodrug which is ribosylated and phosphorylated intracellularly to form its active metabolite, favipiravir ribofuranosyl-5'-triphosphate (favipiravir-RTP).<sup>[17]</sup> Recent *in vitro* and human studies have repositioned favipiravir as an experimental agent against SARS-CoV-2. A randomized-controlled trial (ChiCTR200030254) showed that COVID-19 patients treated with favipiravir had a higher recovery rate (71.43%) than those treated with umifenovir (55.86%), and the fever and cough relief time was significantly shorter in the favipiravir group.<sup>[18]</sup> In an *in vitro* study, SARS-CoV-2 was inhibited by favipiravir in Vero E6 cells with an EC50 of 61.88  $\mu$ Mol.<sup>[19]</sup> In another study including patients without severe disease (i.e., oxygen saturation >93%), the use of favipiravir was associated with faster viral clearance rates (mean clearance time: 4 vs. 11 days, respectively) and a more frequent radiographic improvement (on Day 14, 91% vs. 62%, respectively) compared to lopinavir-ritonavir.<sup>[20]</sup> In the light of these findings, the COVID-19 guidelines of the Tr MoH recommend favipiravir for COVID-19 patients who are unable to tolerate the first-line therapy with hydroxychloroquine or who have comorbid conditions (i.e., immunosuppression).

In conclusion, the results of ongoing randomized-controlled trials are critical to gain a better understanding of this subject. Also, subgroup analysis for solid organ transplant recipients is of paramount importance. In the current COVID-19 era, further collaborative, multi-center, and large-scale heart transplant analyses are urgently warranted.

#### Acknowledgements

We would like to thank all the deceased donors and their families. We also acknowledge the work of all the healthcare workers working toward fighting against COVID-19 worldwide.

#### Declaration of conflicting interests

The authors declared no conflicts of interest with respect to the authorship and/or publication of this article.

#### Funding

The authors received no financial support for the research and/or authorship of this article.

#### REFERENCES

1. Siddiqi HK, Mehra MR. COVID-19 illness in native and immunosuppressed states: A clinical-therapeutic staging proposal. *J Heart Lung Transplant* 2020;39:405-7.
2. Michaels MG, La Hoz RM, Danziger-Isakov L, Blumberg EA, Kumar D, Green M, et al. Coronavirus disease 2019: Implications of emerging infections for transplantation. *Am J Transplant* 2020;20:1768-72.
3. Latif F, Farr MA, Clerkin KJ, Habal MV, Takeda K, Naka Y, et al. Characteristics and Outcomes of Recipients of Heart Transplant With Coronavirus Disease 2019. *JAMA Cardiol* 2020:e202159.
4. Li F, Cai J, Dong N. First cases of COVID-19 in heart transplantation from China. *J Heart Lung Transplant* 2020;39:496-7.
5. Aslam S, Mehra MR. COVID-19: Yet another coronavirus challenge in transplantation. *J Heart Lung Transplant* 2020;39:408-9.
6. Shi S, Qin M, Shen B, Cai Y, Liu T, Yang F, et al. Association of cardiac injury with mortality in hospitalized patients with COVID-19 in Wuhan, China. *JAMA Cardiol* 2020;5:802-10.
7. Bonow RO, Fonarow GC, O'Gara PT, Yancy CW. Association of coronavirus disease 2019 (COVID-19) with myocardial injury and mortality. *JAMA Cardiol* 2020;5:751-3.
8. The Republic of Turkey, Ministry of Health COVID Database. Available at: <https://covid19.saglik.gov.tr/TR-66935/genel-koronavirus-tablosu.html>. [Access: June 09, 2020].
9. Russell MR, Halnon NJ, Alejos JC, Salem MM, Reardon LC. COVID-19 in a pediatric heart transplant recipient: Emergence of donor-specific antibodies. *J Heart Lung Transplant* 2020;39:732-3.
10. DeFilippis EM, Farr MA, Givertz MM. Challenges in Heart Transplantation in the Era of COVID-19. *Circulation* 2020;141:2048-51.
11. Johnson KM, Belfer JJ, Peterson GR, Boelkins MR, Dumkow LE. Managing COVID-19 in renal transplant recipients: a review of recent literature and case supporting corticosteroid-sparing immunosuppression. *Pharmacotherapy* 2020;40:517-24.
12. Hsu JJ, Gaynor P, Kamath M, Fan A, Al-Saffar F, Cruz D, et al. COVID-19 in a high-risk dual heart and kidney transplant recipient. *Am J Transplant* 2020;20:1911-5.
13. Zou L, Dai L, Zhang X, Zhang Z, Zhang Z. Hydroxychloroquine and chloroquine: a potential and controversial treatment for COVID-19. *Arch Pharm Res* 2020;43:765-72.
14. Liu J, Cao R, Xu M, Wang X, Zhang H, Hu H, et al. Hydroxychloroquine, a less toxic derivative of chloroquine, is effective in inhibiting SARS-CoV-2 infection in vitro. *Cell Discov* 2020;6:16.

15. Jankelson L, Karam G, Becker ML, Chinitz LA, Tsai MC. QT prolongation, torsades de pointes, and sudden death with short courses of chloroquine or hydroxychloroquine as used in COVID-19: A systematic review. *Heart Rhythm* 2020;17:1472-79.
16. Giudicessi JR, Noseworthy PA, Friedman PA, Ackerman MJ. Urgent guidance for navigating and circumventing the QTc-prolonging and torsadogenic potential of possible pharmacotherapies for coronavirus disease 19 (COVID-19). *Mayo Clin Proc* 2020;95:1213-21.
17. Shiraki K, Daikoku T. Favipiravir, an anti-influenza drug against life-threatening RNA virus infections. *Pharmacol Ther* 2020;209:107512.
18. Chen C, Zhang Y, Huang J, Yin P, Cheng Z, Wu J, et al. Favipiravir versus Arbidol for COVID-19: A Randomized Clinical Trial. *medRxiv* 2020.
19. Wang M, Cao R, Zhang L, Yang X, Liu J, Xu M, et al. Remdesivir and chloroquine effectively inhibit the recently emerged novel coronavirus (2019-nCoV) in vitro. *Cell Res* 2020;30:269-271.
20. Cai Q, Yang M, Liu D, Chen J, Shu D, Xia J, et al. Experimental treatment with favipiravir for COVID-19: An open-label control study. *Engineering (Beijing)* 2020 [Online ahead of print]