

## A subxiphoid uniportal video-assisted thoracoscopic surgery for synchronous bilateral pulmonary metastasis: A case report

*Senkron iki taraflı akciğer metastazında subksifoid uniportal video yardımcı torakoskopik cerrahi: Olgu sunumu*

Tayfun Kermenli<sup>1</sup> , Cebrail Azar<sup>2</sup> 

<sup>1</sup>Department of Thoracic Surgery, Medical Park Elazığ Hospital, Elazığ, Turkey

<sup>2</sup>Department of Chest Diseases, Medical Park Elazığ Hospital, Elazığ, Turkey

### ABSTRACT

The subxiphoid incision has been widely used in videothoracoscopic surgery in recent years. This minimally invasive technique allows to reach both lungs from a single port. With the future development of the surgical instruments required for the technique, it is expected to become more commonly used. Herein, we report the first case of bilateral pulmonary metastasectomy performed with a subxiphoid single incision in Turkey.

**Keywords:** Pulmonary metastasectomy, subxiphoid, uniportal, video-assisted thoracoscopic surgery.

In recent years, the use of subxiphoid video-assisted thoracoscopic techniques has increased in thoracic surgery, particularly to prevent intercostal nerve damage and postoperative pain. Complex lung resections have currently become possible with this method, which was previously used for thymectomy or pericardial interventions.<sup>[1]</sup> There are some reports in the literature suggesting that bilateral procedures can be performed in the same session, as the postoperative pain is minimal with this technique.<sup>[2]</sup> In addition, bilateral lung wedge resection is performed synchronously without any interference from the intercostal region and, thus, does not cause intercostal nerve damage and provides superiority in aesthetic results.<sup>[1,2]</sup>

### ÖZ

Subksifoid insizyon, videotorakoskopik cerrahide son yıllarda yaygın bir şekilde kullanılmaktadır. Bu minimal invaziv teknik ile tek porttan her iki akciğere de ulaşma imkanı vardır. Gelecekte teknik için gerekli cerrahi enstrümanların geliştirilmesi ile bu yöntem daha sık kullanılır hale gelecektir. Bu yazıda, Türkiye’de subksifoid insizyondan gerçekleştirilen ilk iki taraflı pulmoner metastazektomi olgusu sunuldu.

**Anahtar sözcükler:** Pulmoner metastazektomi, subksifoid, uniportal, video yardımcı torakoskopik cerrahi.

In this article, we report the first case of bilateral lung metastasectomy performed with the subxiphoid incision in Turkey.

### CASE REPORT

A 39-year-old female patient was admitted to our clinic with nodular lesions in the bilateral lung. Her medical history revealed that she was operated on the right knee region about three years ago due to an osteosarcoma. Thoracic computed tomography (CT) showed 1x1-cm nodules in the right lung lower lobe basal segment and the left lung upper lobe posterior segment (Figure 1). However, no other nodules were detected in the lung parenchyma, even in millimeters.

Received: January 29, 2020 Accepted: May 07, 2020 Published online: October 21, 2020

**Correspondence:** Tayfun Kermenli, MD. Medical Park Elazığ Hastanesi, Göğüs Cerrahisi Bölümü, 23040 Elazığ, Türkiye.

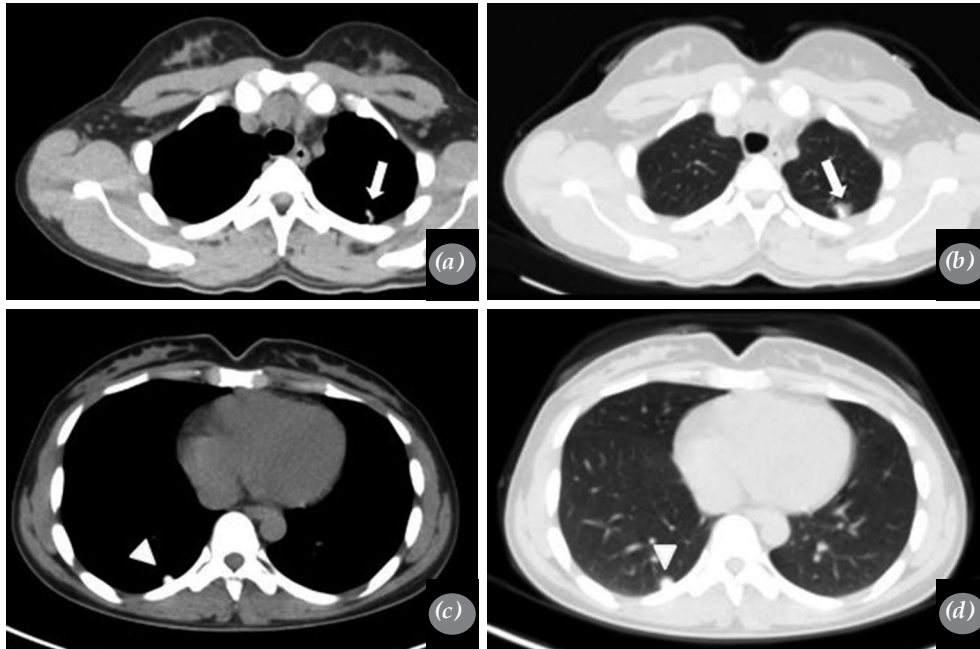
Tel: +90 424 - 234 80 00 e-mail: tayfunkermenli@gmail.com

#### Cite this article as:

Kermenli T, Azar C. A subxiphoid uniportal video-assisted thoracoscopic surgery for synchronous bilateral pulmonary metastasis: A case report. Turk Gogus Kalp Dama 2020;28(4):702-705

©2020 All right reserved by the Turkish Society of Cardiovascular Surgery.

This is an open access article under the terms of the Creative Commons Attribution-NonCommercial License, which permits use, distribution and reproduction in any medium, provided the original work is properly cited and is not used for commercial purposes (<http://creativecommons.org/licenses/by-nc/4.0/>).




**Figure 1.** Computed tomography images showing bilateral pulmonary calcific and solid nodules; (a, b) left lung upper lobe posterior segment (arrow), (c, d) right lung lower lobe basal segment (arrowhead).

Also, the nodules contained calcified areas. We performed whole body positron emission tomography (PET) screening for distant metastases; however, no other fluorodeoxyglucose (FDG) involvement site was seen. Pulmonary nodules were planned to be excised for diagnostic and metastasectomy based on the recommendation of the Oncological Council. Since there were no thoracic CT findings showing adhesion between the lung and the pleura and the patient did not previously undergo any thoracic surgery, we planned to perform metastasectomy in the same session in both

lungs. A written informed consent was obtained from the patient.

Bilateral wedge resection was planned synchronously with uniportal subxiphoid video-assisted thoracoscopic surgery (VATS). To perform wedge resection, the patient was ventilated by performing left selective intubation with a double-lumen intubation tube. Following the endotracheal intubation, a 4-cm incision was made in the subxiphoid in the position. The operating table was, then, placed at 30° right lateral decubitus position.



**Figure 2.** Intraoperative images of pulmonary solid nodules with VATS. (a) Right lung peripheral nodule (arrow), (b) left lung nodule (arrowhead).

VATS: Video-assisted thoracoscopic surgery.

Exploration was performed in the left hemithorax with 5-mm 30° video thoracoscopic optics. Since there was a single and peripheral nodule in both lungs, it was not difficult to detect the localization of the lesion and, therefore, it was not necessary to use carbon dioxide (CO<sub>2</sub>) insufflation during the operation. The nodule in the left lung upper lobe posterior segment was suspended with a grasper and wedge resection was performed using two endostaplers (Figure 2). After bleeding and air leak control, 20-Fr thoracic drains were placed in the thorax. Since no other nodules were seen in the left lung and pleura of the patient, excision of the nodule in the right lung was started. The patient was placed 30° left lateral decubitus position. The VATS camera was entered into the thorax, and wedge resection was applied to the nodule in the lower lobe basal segment of the right lung (Figure 2). To prevent tumor implantation in the incision area, wedge resected nodules were removed out of the thorax using an endobag. The procedure was terminated by placing a 20-Fr drain into the thorax. Both thoracic drains were inserted through the incision line in the subxiphoid area. The drain on the left side was removed on the third postoperative day, and the drain on the right side was removed on Day 4. The patient was discharged on the postoperative Day 4. In the postoperative follow-up in the outpatient setting, chest radiography revealed normal findings. The pathological examination result was reported as an osteosarcoma and the patient was referred to oncology clinic for the treatment.

## DISCUSSION

Lung metastases of sarcoma species are common and metastasectomy is known to improve survival in these patients.<sup>[3]</sup> It has been reported that the rate of sarcomas among tumors treated with pulmonary metastasectomy is about 18%.<sup>[4]</sup> As a surgical technique, thoracotomy, VATS or median sternotomy are utilized. However, it is important to choose less invasive technique in cases in whom the number and location of nodules are apparent on thoracic CT. In the studies of Cangel et al.,<sup>[4]</sup> the results of 118 surgical interventions were reported, and VATS was applied effectively and safely in eligible cases.

Less pain and faster recovery can be achieved by increasingly using the options of VATS such as uniportal and subxiphoid incision in the practice of thoracic surgery. With the incision applied from the subxiphoid area, the surgical procedure can be easily performed without damaging the intercostal nerve. In addition, since it is possible to reach both hemithoraces from this region, surgery can be performed bilaterally

in both lungs in the same session. Bilateral surgery has been shown to be effective, particularly in the presence of a limited number of nodules in the lung and in lesions with a peripheral location. It can be also considered as an advantage that the patient does not receive anesthesia twice in a certain period of time unlike surgeries performed in the right and left separate sessions.<sup>[5]</sup>

With uniportal subxiphoid VATS, the feasibility of all resection options in the lung has been demonstrated. This makes it to be a preferred technique among thoracic surgeons. It has also positive aspects such as reduced pain, favorable cosmetic appearance, early recovery, and less paresthesia in the chest wall. However, it is thought to have a disadvantage in terms of bleeding control in the major bleeding which may occur during lung major resections. Carvalho et al.<sup>[6]</sup> reported that mediastinal lymph node sampling was insufficient, especially when performing lung cancer surgery; however, the same study recommends the subxiphoid approach because of its advantages.

Postoperative pain increases, as the number of ports increases in VATS. With the subxiphoid uniportal VATS, less pain is perceived, as there is no intercostal nerve compression. Therefore, we believe that it should be preferred in suitable cases. As in our case, subxiphoid incision can be used easily in patients with a low number of nodules located peripherally.

In conclusion, subxiphoid uniportal video-assisted thoracoscopic surgery has certain advantages such as excellent pain control, quick recovery, shorter hospital stay, and synchronous bilateral lung intervention. Based on these findings, we can speculate that this technique would be more widely adopted in the near future among thoracic surgeons.

### Declaration of conflicting interests

The authors declared no conflicts of interest with respect to the authorship and/or publication of this article.

### Funding

The authors received no financial support for the research and/or authorship of this article.

## REFERENCES

1. Tezel Ç, Doğruyol T, Evman S, Baysungur V, Yaçınkaya İ. A subxiphoid single-incision video-assisted thoracoscopic lobectomy: A case report. *Turk Gogus Kalp Dama* 2017;25:667-9.
2. Suda T, Ashikari S, Tochii S, Sugimura H, Hattori Y. Single-incision subxiphoid approach for bilateral metastasectomy. *Ann Thorac Surg* 2014;97:718-9.

3. Taslak Şengül A, Başoğlu A, Bilgin Büyükkarabacak Y, Durgun Yetim T, Kutlu T. Assessment of metastasectomy and prognostic factors in the treatment of metastatic lung tumors. *Turk Gogus Kalp Dama* 2009;17:87-91.
4. Cangel G, Turna A, Demirkaya A, Tüzün H, Kaynak K, Demirhan Ö. Results of resection of pulmonary metastasis and prognostic factors. *Turk Gogus Kalp Dama* 2014;22:354-62.
5. Aresu G, Weaver H, Wu L, Lin L, Sponga S, Jiang G, et al. Uniportal subxiphoid video-assisted thoracoscopic bilateral segmentectomy for synchronous bilateral lung adenocarcinomas. *J Vis Surg* 2016;2:170.
6. Carvalheiro C, Gallego-Poveda J, Gonzalez-Rivas D, Cruz J. Uniportal VATS Lobectomy: Subxiphoid Approach. *Rev Port Cir Cardiorac Vasc* 2017;24:141.