

The effect of rutin on pulmonary contusion induced by blunt trauma in rats: Biochemical and histopathological evaluation

*Rutin'in sıçanlarda künt travmaya bağlı pulmoner kontüzyon üzerine etkisi:
Biyokimyasal ve histopatolojik değerlendirme*

Bekir Elma¹, Renad Mammadov², Yasin Bilgin³, Gülce Naz Yazıcı⁴, Halis Süleyman², Taha Abdulkadir Çoban⁵

Institution where the research was done:

Medicine Faculty of Erzincan Binali Yıldırım University, Erzincan, Türkiye

Author Affiliations:

¹Department of Thoracic Surgery, Medicine Faculty of Erzincan Binali Yıldırım University, Erzincan, Türkiye

²Department of Pharmacology, Medicine Faculty of Erzincan Binali Yıldırım University, Erzincan, Türkiye

³Emergency Health Services, Erzincan Health Directorate, Erzincan, Türkiye

⁴Department of Histology and Embryology, Medicine Faculty of Erzincan Binali Yıldırım University, Erzincan, Türkiye

⁵Department of Biochemistry, Medicine Faculty of Erzincan Binali Yıldırım University, Erzincan, Türkiye

ABSTRACT

Background: This study aims to investigate the possible protective effects of rutin, also called vitamin P1, against pulmonary contusion induced by blunt chest trauma in a rat model.

Methods: Thirty male albino Wistar rats were separated into three equal groups as healthy group, trauma group, and trauma+rutin group. After anesthesia provided by intraperitoneal administration of 60 mg/kg ketamine and xylazine by inhalation at appropriate intervals, 200 g weight was dropped from 1 m height to the anterior chest wall of the animals in the trauma group (n=10) and trauma+rutin group (n=10) and pulmonary contusion was created. Thirty min after the trauma, 50 mg/kg of rutin was administered into the stomach of trauma+rutin group animals orally with gavage. The rats received rutin once daily for two days and were sacrificed 48 h later. Their lung tissues were removed and examined biochemically and histopathologically.

Results: Nuclear factor-kappa B, cyclooxygenase-2, and malondialdehyde levels increased in the trauma group compared to the healthy group, and rutin administration prevented this increase. Total glutathione levels decreased in the trauma group, and rutin administration also prevented this decrease. The histopathological findings were compatible with the biochemical findings.

Conclusion: Our study results suggest that rutin has a protective effect on contused lung tissue in rats.

Keywords: Blunt thoracic trauma, pulmonary contusion, rat, rutin.

ÖZ

Amaç: Bu çalışmada, sıçan modelinde P1 vitamini olarak da adlandırılan rutin'in künt göğüs travmasının neden olduğu pulmoner kontüzyona karşı olası koruyucu etkileri araştırıldı.

Çalışma planı: Otuz adet erkek albino Wistar sıçan sağlıklı grup, travma grubu ve travma+rutin grubu olmak üzere üç eşit gruba ayrıldı. İntraperitoneal olarak 60 mg/kg ketamin verilerek ve uygun aralıklarla ksilazin koklatılarak anestezi sağlandıktan sonra, travma grubu (n=10) ve travma+rutin grubu (n=10) hayvanların göğüs ön duvarına 1 metre yükseklikten 200 g ağırlık düşürüldü ve pulmoner kontüzyon oluşturuldu. Travmadan 30 dk. sonra travma+rutin grubu hayvanların midesine ağızdan gavaj ile 50 mg/kg rutin uygulandı. Rutin, iki gün boyunca günde bir kez kullanıldı ve sıçanlar 48 saat sonra sakrifiye edildi. Akciğer dokuları çıkarıldı ve biyokimyasal ve histopatolojik olarak incelendi.

Bulgular: Sağlıklı gruba kıyasla, travma grubunda nükleer faktör-kappa B, siklooksijenaz-2, malondialdehit düzeyleri artmış olup, rutin uygulanması bu artışı önledi. Travma grubunda total glutatyon düzeylerinin azaldığı saptanmış olup, rutin uygulaması bu azalmayı önledi. Histopatolojik bulgular, biyokimyasal bulgular ile uyumlu idi.

Sonuç: Çalışma bulgularımız rutin'in sıçanlarda kontüzyon gelişen akciğer dokusu üzerinde koruyucu bir etkiye olduğunu göstermektedir.

Anahtar sözcükler: Künt göğüs travması, pulmoner kontüzyon, sıçan, rutin.

Received: April 21, 2021 Accepted: August 13, 2021 Published online: July 29, 2022

Correspondence: Bekir Elma, MD. Erzincan Binali Yıldırım Üniversitesi Tıp Fakültesi, Göğüs Cerrahisi Anabilim Dalı, 24100 Erzincan, Türkiye.

Tel: +90 446 - 226 18 18 e-mail: drbekirelma@gmail.com

Cite this article as:

Elma B, Mammadov R, Bilgin Y, Yazıcı GN, Süleyman H, Çoban TA. The effect of rutin on pulmonary contusion induced by blunt trauma in rats: Biochemical and histopathological evaluation. Turk Gogus Kalp Dama 2022;30(3):431-439

©2022 All right reserved by the Turkish Society of Cardiovascular Surgery.

This is an open access article under the terms of the Creative Commons Attribution-NonCommercial License, which permits use, distribution and reproduction in any medium, provided the original work is properly cited and is not used for commercial purposes (<http://creativecommons.org/licenses/by-nc/4.0/>).

Pulmonary contusion (PC) is the most frequently diagnosed lung injury in blunt chest trauma (BCT). It has recently been encountered most due to motor vehicle accidents. A high-energy effect can cause acceleration-deceleration in the spine or compression of the chest, which can cause serious injury to internal organs.^[1] As a life-threatening pathology, PC increases mortality in patients with multiple trauma.^[1] Clinical symptoms can vary from mild dyspnea to acute respiratory distress syndrome (ARDS). A severe PC causes inflammatory lung injury, increased pulmonary vascular permeability and lung weight, decreased ventilation, and hypoxia. Therefore, patients with PC are more likely to develop ARDS, be hospitalized in the intensive care unit, and be connected to a mechanical ventilator.^[2]

Pulmonary contusion progresses with an inflammatory response leading to interstitial edema and protein extravasation. This inflammatory response is due to the early induction of cytokine expression. Indeed, a study reported that alveolar cytokine levels increased rapidly in the early post-trauma period.^[3] Nuclear factor-kappa B (NF- κ B) is responsible for the transcription of genes encoding various proinflammatory cytokines. It is also known that NF- κ B regulates inflammatory cytokine production, and the NF- κ B signaling pathway is essential for acute lung injury (ALI).^[4] Typically, the cyclooxygenase-2 (COX-2) isoenzyme is present at shallow levels in cells, and its production is increased through the NF- κ B signaling pathway. Induced COX-2 is the key enzyme involved in prostaglandin (PG) production from arachidonic acid (AA). It is well known that PGs are also mediators responsible for vasodilation and edema. A study reported that PC developed after trauma and COX-2 increased in the bronchoalveolar fluid.^[5]

Another mechanism responsible for tissue damage is oxidative stress. A review article reveals a relationship between inflammation and oxidative stress.^[6] Oxidative stress is likely to increase inflammation. One of the most remarkable biological targets of oxidative stress is lipids. Peroxidation of lipids (LPO) disrupts the membrane integrity of cells. Malondialdehyde (MDA) is the final toxic product of LPO and is an essential indicator of oxidative stress.^[7] However, various antioxidant mechanisms balance the effects of oxidants in living organisms. As one of these, endogenous glutathione (GSH) is abundant in all cells and is the major soluble antioxidant. Reduced GSH protects membrane lipids from oxidative damage.^[8]

In previous studies, the histopathological findings of the response to traumatic lung injury are consistent with biochemical findings. To illustrate, in a PC model, an increased number of polymorphonuclear leukocytes (PNLs) and a significant degree of intra-alveolar edema in alveolar spaces and interstitium have been reported 24 h after trauma.^[5]

The rutin has biological properties such as antioxidant, anti-inflammatory, inhibition of cytokine expression, and inhibition of PNL infiltration. Regarding the anti-inflammatory effect of rutin, studies have shown that it inhibits the NF- κ B signaling pathway,^[4] inhibits COX-2 increase,^[9] and reduces capillary permeability.^[10] Its antioxidative effect has been reported to prevent increased MDA levels and decreased GSH levels.^[11] Histopathologically, rutin prevents PNL infiltration in the alveoli.^[10]

Although early treatment of progressive lung injury has proven to have a critical role in prognosis, there is no specific treatment for PC, yet. In the present study, we aimed to investigate whether rutin exerted a protective effect against possible lung inflammatory and oxidative damage induced by BCT in a rat model.

MATERIALS AND METHODS

In this experimental study, a total of 30 male albino Wistar rats (weighing 200 to 250 g and 6 to 7-month-old) were used. All rats were obtained from Atatürk University Medicinal Experimental Application and Research Center. All animals were maintained in accordance with the recommendations of the National Institutes of Health Guidelines for the Care and Use of Laboratory Animals. The animals were housed and fed in a suitable laboratory environment at average room temperature (22°C) and under suitable conditions.

Chemical substances

In the experiment, rutin was supplied from Solgar® (Solgar Leonia, NJ, USA), and ketamine was supplied from Pfizer İlaçları Ltd. Sti. (Türkiye).

Experimental groups

We classified the animals into three equal groups as healthy group (HG), trauma group (TG), and trauma+rutin group (TRG).

Experiment procedure

In rats, the trauma procedure was performed with anesthesia administering 60 mg/kg ketamine intraperitoneally and xylazine by inhalation at appropriate intervals. When the animals remained stable supine, the period was considered the appropriate

anesthesia period for administering trauma.^[12] After ketamine injection, the rats were kept waiting for this favorable period to occur. During anesthesia, PC was created by dropping 200 g weight on the anterior chest wall of animals in TG (n=10) and TRG (n=10) groups, and PC was created. The resulting energy was calculated to be 1.96 Joules with the formula of $E=mgh$ (E: energy, m: reduced weight; 0.2 kg, g: gravity; 9.8 m/s², h: height; 100 cm). As a result, PC was induced by administering 1.96 Joules of energy to rats.^[13] Thirty min after the contusion, 50 mg/kg of rutin was administered into the stomach of TRG group animals orally with gavage. The rutin was used once a day for two days. The same volume of 0.9% sodium chloride (NaCl) was administered orally to the HG (n=10) group. At the end of this period, the animals were killed with high-dose ketamine anesthesia, and their lung tissues were removed. The removed lung tissues were examined biochemically and histopathologically. The evaluation was made comparing the results obtained from TG and HG groups with the TRG group results.

Preparing the samples for biochemical analysis

At this stage of the study, 0.2 g from each removed tissue was weighed. Tissues were homogenized in an icy environment completing 1.15% potassium chloride solution for MDA determination to 2 mL in phosphate buffer pH=7.4 for total GSH (tGSH), COX, NF-κB, and protein measurements. It was, then, centrifuged at +4°C and 10,000 rpm for 15 min. The NF-κB, COX-2, MDA, and tGSH levels in the supernatants obtained from the prepared homogenates were determined using appropriate methods as prescribed in the literature.

Protein measurement

Protein concentration measurement was done according to the Bradford MM method.^[14] The principle of the measurement is based on measuring the absorbance at 595 nm of the colored complex

formed by the binding of the Coomassie Brilliant Blue G-250 dye to proteins. All tissue analysis results were standardized by dividing them into protein.

Nuclear factor-kappa B analysis

Tissue-homogenates NF-κB concentrations were measured using rat-specific sandwich enzyme-linked immunosorbent assay. Rat NF-κB ELISA immunoassay kits (Cat. No:201-11-0288, Sun Red). Tissue NF-κB concentration was calculated as μg/g protein.

Measurement of cyclooxygenase activity

Cyclooxygenase activity in rat lung tissue was measured using a COX activity assay kit (Cayman, Ann Arbor, MI, USA). Tissue NF-κB concentration was calculated pmoL/mg protein.

Malondialdehyde determination

The MDA levels were determined spectrophotometrically at 532 nm according to the method described by Ohkawa *et al.*^[15] This method is based on spectrophotometric measurement of absorbance of colored complex, which is formed by thiobarbituric acid and MDA at a high temperature (95°C). Tissue MDA concentration unit was given as μmol/g protein.

Total glutathione determination

5,5'-Dithio-bis (2-nitrobenzoic acid) (DTNB) in the measurement environment was a disulfide chromogen and was easily reduced by sulfhydryl-group compounds. The resulting yellow color was measured spectrophotometrically at 412 nm.^[16] Tissue tGSH concentration unit was given as nmol/g protein.

Histopathological examination

All tissue samples were first identified in a 10% formaldehyde solution for light microscope assessment. Following the identification process, tissue samples were washed under tap water in cassettes for 24 h. To

Table 1. Biochemical results of the study groups

	Healthy group (n=10)	Trauma group (n=10)	Trauma+rutin group (n=10)
	Mean±SD	Mean±SD	Mean±SD
NF-κB (μg/g protein)	3.3±0.1	8.3±0.1*	4.0±0.3*†
COX-2 (pmol/mg protein)	0.2±0.0	3.2±0.1*	1.2±0.0*†
MDA (μmol/gr protein)	2.5±0.5	5.3±0.4*	2.9±0.7*
tGSH (μmol/g protein)	6.4±0.2	3.0±0.3*	6.1±0.3*

SD: Standard deviation; NF-κB: Nuclear factor-kappa B; COX-2: Cyclooxygenase-2; MDA: Malondialdehyde; tGSH: Total glutathione; Statistically significant (p<0.05) compared to * Healthy group, with † TG. The significance of the variations between the groups was determined using the method of one-way ANOVA, followed by the analysis by Tukey test.

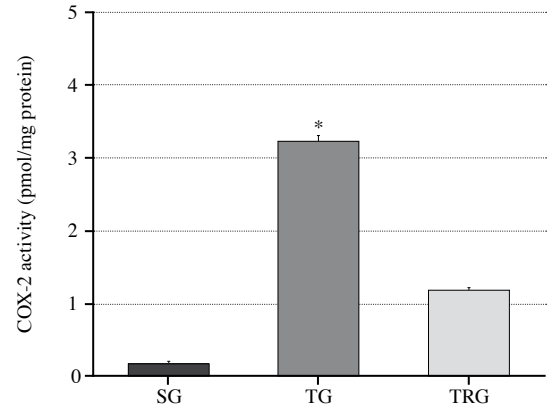
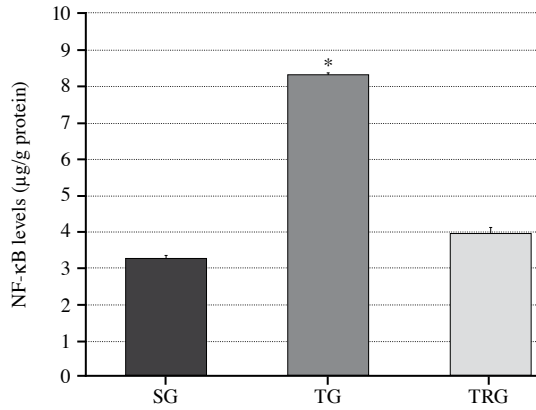


Figure 1. NF-κB and COX-2 levels of the study groups.

* $p < 0.001$ according to HG and TRG groups ($n=10$); NF-κB: Nuclear factor-kappa B; COX-2: Cyclooxygenase-2; HG: Healthy group; TG: Trauma group; TRG: Trauma+rutin group.

remove the water within tissues, samples were treated with a conventional alcohol grade (70%, 80%, 90%, and 100%). Tissues were, then, passed through xylol and embedded in paraffin. Four to five-micron sections were cut from the paraffin blocks, and hematoxylin-eosin staining was administered. Their photos were taken following the Olympus DP2-SAL firmware program (Olympus® Inc., Tokyo, Japan) assessment. The pathologist blind carried out a histopathological assessment for the study groups. The histopathological damage severity in each lung tissue section was scored between 0 and 3 degrees (0-normal, 1-mild damage, 2-moderate damage, and 3-severe damage) and displayed as a table.

Statistical analysis

Statistical analysis was performed using the IBM SPSS for Windows version 19.0 (IBM Corp., Armonk, NY, USA). Descriptive data were expressed in mean \pm standard deviation (SD) for continuous variables. The significance of the variations among the groups was determined using one-way analysis of variance (ANOVA), followed by the Tukey test analysis. The histopathological examination revealed the group differences by the Kruskal-Wallis test, and the Dunn test was used to identify which groups were different. A p value of <0.05 was considered statistically significant.

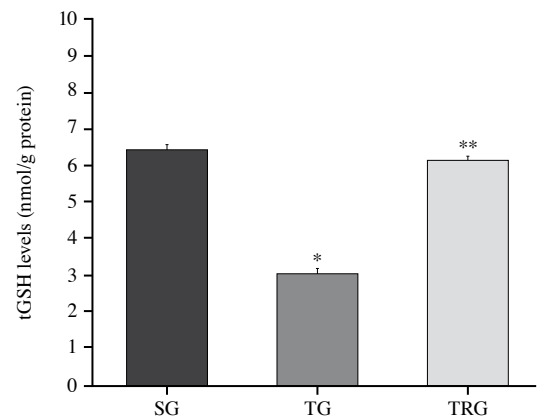
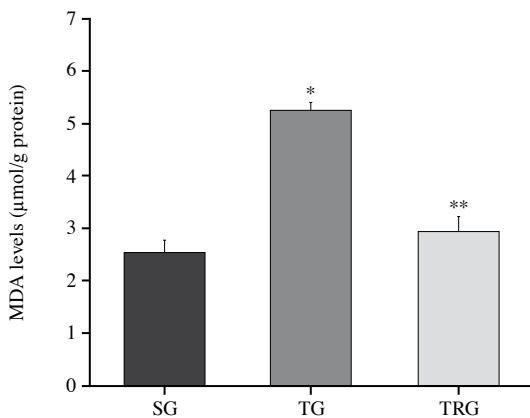


Figure 2. MDA and tGSH levels of the study groups.

*: $p < 0.0001$ according to HG and TRG groups ($n=10$); **: $p > 0.05$ according to HG group; MDA: Malondialdehyde; tGSH: Total glutathione; HG: Healthy group; TG: Trauma group; TRG: Trauma+rutin group.

RESULTS

Biochemical findings

Nuclear factor-kappa B analysis results

The level of NF- κ B increased in the TG compared to the HG, and the increase in NF- κ B level was prevented with its rutin application. There was a statistically significant difference between the HG and the TG ($p=0.001$), and similarly, there was a considerable difference between the TG and the TRG ($p=0.001$) (Figure 1). The differences in mean levels of NF- κ B among the groups are shown in Table 1.

Cyclooxygenase-2 analysis results

As shown in Figure 1, COX-2 enzyme activity in the lung tissues increased in the TG compared to the HG. A statistically significant difference was found between these two groups ($p<0.001$). This increase was prevented by administering rutin, and a statistically significant difference was found between the TG and the TRG ($p<0.001$). The differences in mean levels of COX-2 among the groups are shown in Table 1.

Malondialdehyde analysis results

When the HG and TG were compared in terms of MDA values, there was an increase in the TG compared to the HG, and the difference between these two groups was statistically significant ($p<0.001$). This oxidant increase was prevented administering rutin, and a significant difference was found between the TG and TRG ($p<0.001$). When the TRG and the HG were compared, no statistically significant difference was observed between the two groups ($p=0.415$) (Figure 2). The differences in mean levels of MDA among the groups are shown in Table 1.

Total glutathione analysis results

As shown in Figure 2, a decrease in tGSH level was observed in the TG compared to the HG, and a significant difference was found between these two groups ($p<0.001$). In the TRG, the decrease in tGSH level was prevented, and a significant difference was observed between the TG and TRG ($p<0.001$). There was no statistically significant difference between the TRG and the HG ($p=0.08$). The differences in mean levels of tGSH among the groups are shown in Table 1.

Histopathological evaluation

When the lung tissue sections of the HG were analyzed, the bronchiole structures, alveoli, and vascular structures had typical histological lung tissue images (Figure 3a). When the TG in which PC was induced by blunt trauma was analyzed, the

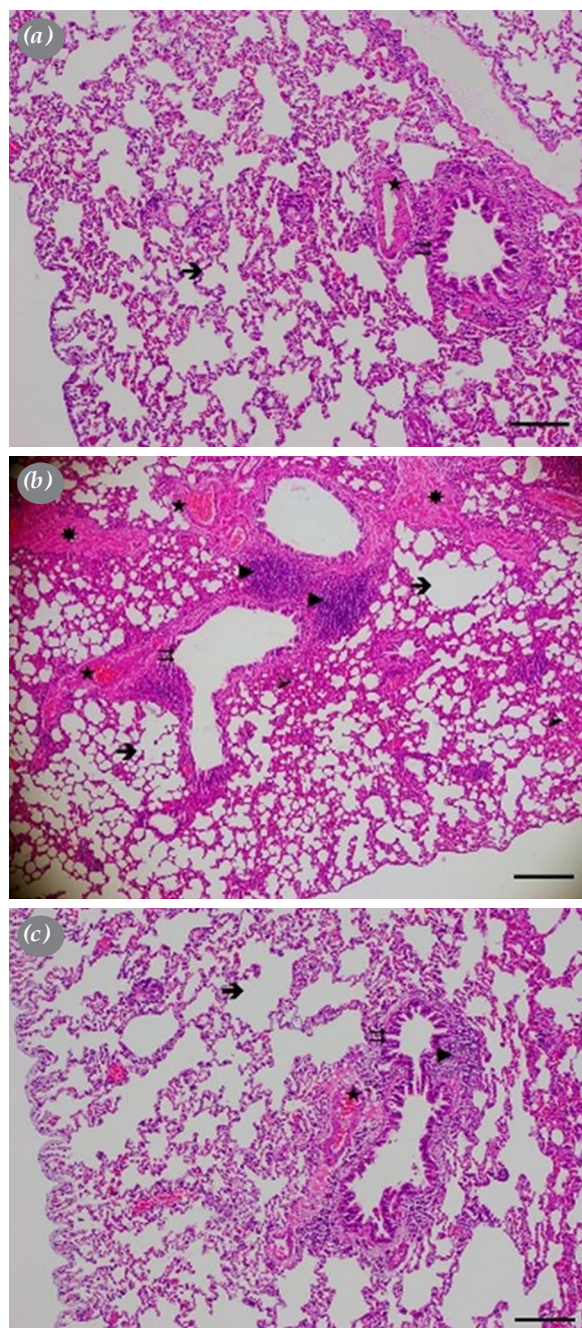


Figure 3. Study groups' histopathological images. (a) Healthy group's lung tissue section (H&E, $\times 100$), \rightarrow : Alveolus, \Rightarrow : Bronchiole, \star : blood vessel, scale bar 200 μ m. (b) Trauma group's lung section (H&E, $\times 100$), \rightarrow : Severe alveolar edema, \Rightarrow : Degenerated bronchiole epithelium, \blacktriangleright : Severe peribronchial lymphocyte infiltration, \blacktriangleright : Severe hemorrhage in the interalveolar area, \star : Congested blood vessel, \star : Perivascular connective tissue increase, scale bar 200 μ m. (c) Treatment group's lung section (H&E, $\times 100$), \rightarrow : Mild edema in the alveoli, \Rightarrow : Normal bronchiole, \blacktriangleright : Greatly reduced lymphocyte infiltration in the peribronchial area, \star : Slightly congested blood vessels. HE: Hematoxylin-Eosin staining, scale bar 200 μ m.

Table 2. Histopathological results of the study groups

	Healthy group (n=10)	Trauma group (n=10)	Trauma+rutin group (n=10)
	Mean±SD	Mean±SD	Mean±SD
Inflammatory cell infiltration	0±0	2.7±0.5*	1.3±0.5*†
Alveolar edema	0±0	2.8±0.4*	1.3±0.5*†
Interalveolar hemorrhage	0±0	2.7±0.52*	0.3±0.5†
Congestion	0±0	2.8±0.4*	0.3±0.5†

SD: Standard deviation; Statistically significant ($p < 0.05$) compared to * Healthy group, with † Trauma group. Kruskal-Wallis test was used and Dunn test was performed as *post-hoc*.

length of the bronchiolar epithelium was shortened and flattened. Bronchial-associated lymphoid tissue increased due to intense inflammatory cell infiltration in the peribronchial area. Furthermore, the presence of intensive intra-alveolar edema and dense hemorrhage in the interalveolar area were observed. Congestion in the blood vessels and increased connective tissue in the perivascular areas were determined (Figure 3b). The bronchiole epithelium was normal, and the inflammatory cell infiltration in the peribronchial area decreased considerably in the treatment group. There was slight edema in the intra-alveolar area, and the interalveolar regions had a normal appearance. The congestion in the blood vessels almost disappeared, and perivascular connective tissue regained its normal appearance (Figure 3c). The severity evaluation of the histopathological findings of the groups is shown in Table 2.

DISCUSSION

Blunt chest trauma is usually induced by a high-energy impact affecting the chest wall.^[11] Immediately after the injury caused by trauma, secondary damage begins to develop due to inflammatory response and oxidative stress. In severe cases, the inflammatory response can result in ARDS.^[17] It has been reported in the literature that PC is associated with a progressive inflammatory reaction mediated by immunological changes.^[18] In an experimental study carried out by Zhang et al.,^[19] NF- κ B was reported to be an essential signaling factor for inflammatory lung injury. The NF- κ B is a transcription factor supporting the expression of inflammatory cytokines and inflammatory pathways. Wang et al.^[20] reported that NF- κ B inhibition caused a decrease in the production of proinflammatory cytokines and an increase in antioxidant levels. In our study, the level of NF- κ B was found to be high in the lung tissue with traumatic

damage. This finding supports that our experimental results are consistent with the literature data.

In the present study, a significant increase in COX-2 activity was observed in damaged lung tissue induced by BCT. One of the primary mechanisms playing a role in inflammatory damage is the COX-2 enzyme accompanied by the AA metabolism. The COX-2 isoenzyme, which is rapidly induced in damaged tissues, plays a key role in shaping inflammation and producing PG from AA. Moreover, it was stated that the induction of COX-2 in damaged tissue causes an increase in the production of reactive oxygen species (ROS).^[21]

As known, changing the oxidant/antioxidant balance in tissues in favor of oxidants causes tissue damage, and this is known as oxidative stress. Excessive ROS in damaged tissue accelerates LPO reaction.^[22] The MDA, the final product of LPO, causes cell death by damaging the cell membrane, impairing ion permeability, and inactivating enzyme activity. It has been known for a long time that high MDA levels are a good indicator of ROS formation.^[15] There are several studies in the literature indicating the increase of MDA levels in damaged tissue. A study on PC induced by BCT revealed an MDA increase in the lung tissues of the rats.^[23]

The ROS is produced in living tissues in a continuous and controlled way. For maintaining tissue integrity and functions at normal levels, overproduced ROS are neutralized in a controlled manner by endogenous GSH and other antioxidants. It has been shown that endogenous GSH protects the sulfhydryl structures of proteins and plays a role in protecting cells against cytotoxic substances.^[24] Dogan et al.^[25] proved that GSH levels decreased in lung tissue after BCT-induced PC. Our experimental results suggested that the post-PC oxidant/antioxidant balance in the lung tissue changed in favor of oxidants, supporting the beginning of oxidative damage in the lung.

It has been histopathologically indicated in almost all studies carried out on PC induced by blunt trauma that inflammation causes an increase in alveolocapillary membrane permeability and alveolar edema. In most of these studies, histopathological density of PNL in the lung tissue was statistically significant compared to the healthy group.^[26] In experimental models, alveolar integrity deterioration, intra-alveolar hemorrhage, interstitial edema, interalveolar and intra-alveolar PNL deposition have been reported in tissues with PC.^[27] In our study, the histopathological results are similar to previous studies in terms of the findings related to intense hemorrhage, inflammatory cell accumulation, edema, and vascular congestion in the TG.

It is obvious that physicians need to control the secondary damage mechanism in lung contusion as early as possible. For this purpose, there are experimental studies using sildenafil and hyperbaric oxygen in the literature.^[28,29] There are more experimental studies to observe the antioxidant and anti-inflammatory effects of vitamins. According to Sirmali *et al.*,^[30] vitamin C had a remarkable antioxidative effect on PC. Satria and Umar^[31] also showed that the combination of vitamins C and E reduced cell death in rats with PC. Gökçe *et al.*^[32] divided the animals with PC into groups and administered coenzyme Q, vitamin C, vitamin E, and dexamethasone to each animal group separately. They obtained the most significant anti-inflammatory response with the coenzyme Q group and the most significant antioxidative result with the vitamin C group. Taken together, these findings suggest that using vitamin derivatives in the early stages of PC is beneficial.

In the literature, there is no study investigating the effect of rutin against PC-associated inflammation. However, in studies in which lipopolysaccharide induces lung damage, it has been shown that rutin exerts its anti-inflammatory effects by inhibiting the NF- κ B signaling pathway.^[4] In a cell culture study, rutin inhibited the inflammatory responses of macrophages by blocking the NF- κ B signaling pathway.^[33] The production of mediators that caused increased capillary permeability occurred through the COX pathway, and this pathway was inhibited by various anti-inflammatory drugs.^[21] A study showed that rutin significantly reduced COX-2 expression depending on the dose.^[34] In our study, the low levels of NF- κ B and COX-2 in the group administered with rutin after trauma supported the finding that rutin inhibited the COX pathway through NF- κ B inhibition.

Previous *in vitro* and *in vivo* studies have shown that rutin can reduce oxidative stress. In the literature,

rutin has been suggested to be a powerful antioxidant agent.^[35] It prevents increased oxidants such as MDA and the decrease of antioxidants such as GSH in both ischemia-reperfusion injuries^[36] and lung injury.^[4] In a study in which oxidative stress was created with pulmonary edema, low MDA and high GSH levels were obtained by rutin administration.^[11] In our study, low MDA and high tGSH levels obtained by administering rutin can be interpreted as rutin to have an antioxidative effect on PC.

In a study in which lung damage was induced, histopathological results indicated that the findings such as bleeding, interstitial edema, thickening of the alveolar wall, and PNL infiltration decreased with rutin administration.^[4] In parallel with this study, several studies reported that rutin decreased protein concentration and inflammatory cell infiltration in bronchoalveolar lavage fluid.^[10,34] Considering our treatment group, rutin reduced inflammation that developed after traumatic lung injury. There were no significant histopathological findings, except for mild inflammatory infiltration and mild alveolar edema.

Nonetheless, there are some limitations to this study. The effect of rutin on lung tissue in pulmonary contusion accompanying multiple organ injuries is unknown. It is also unclear whether the curative effect of rutin is dose-dependent. In our study, we were unable to compare the effect of rutin and other vitamins on PC and superiority of one to another.

In conclusion, our study results showed that the increase in NF- κ B, COX-2, and MDA levels and the decrease in tGSH levels caused inflammation and oxidative stress in PC induced by BCT in rats. Furthermore, lung injury induced by BCT was indicated histopathologically. Biochemical and histopathological findings caused by trauma were found to be improved with rutin administration. These results suggest that rutin seems to be helpful in the treatment of PC complications. However, further clinical studies are needed to confirm these findings,

Ethics Committee Approval: The study protocol was approved by the Atatürk University Animal Experimentation Ethics Committee (No: 75296309-050.01.04-E.2000272506, Date: 02.11.2020).

Data Sharing Statement: The data that support the findings of this study are available from the corresponding author upon reasonable request.

Author Contributions: Idea/concept: B.E., H.S.; Design: B.E., R.M., Y.B., H.S.; Control/supervision: H.S., T.A.Ç.; Data collection and/or processing, analysis and/or interpretation: B.E., R.M., G.N.Y., T.A.Ç.; Literature review: B.E., R.M., Y.B.; Writing the article: B.E., Y.B.; Critical review: H.S., G.N.Y.,

T.A.Ç.; References and fundings: B.E., R.M., Y.B.; Materials: R.M., G.N.Y., H.S., T.A.Ç.

Conflict of Interest: The authors declared no conflicts of interest with respect to the authorship and/or publication of this article.

Funding: The authors received no financial support for the research and/or authorship of this article.

REFERENCES

1. Rendeki S, Molnár TF. Pulmonary contusion. *J Thorac Dis* 2019;11(Suppl 2):S141-S151.
2. Zhou D, Qiu J, Liang Y, Dai W, Yuan D, Zhou J. Epidemiological analysis of 9,596 patients with acute lung injury at Chinese Military Hospitals. *Exp Ther Med* 2017;13:983-8.
3. Maxwell RA, Gibson JB, Fabian TC, Proctor KG. Effects of a novel antioxidant during resuscitation from severe blunt chest trauma. *Shock* 2000;14:646-51.
4. Yeh CH, Yang JJ, Yang ML, Li YC, Kuan YH. Rutin decreases lipopolysaccharide-induced acute lung injury via inhibition of oxidative stress and the MAPK-NF- κ B pathway. *Free Radic Biol Med* 2014;69:249-57.
5. Dolkart O, Amar E, Shapira S, Marmor S, Steinberg EL, Weinbroum AA. Protective effects of rosuvastatin in a rat model of lung contusion: Stimulation of the cyclooxygenase 2-prostaglandin E-2 pathway. *Surgery* 2015;157:944-53.
6. Mittal M, Siddiqui MR, Tran K, Reddy SP, Malik AB. Reactive oxygen species in inflammation and tissue injury. *Antioxid Redox Signal* 2014;20:1126-67.
7. Del Rio D, Stewart AJ, Pellegrini N. A review of recent studies on malondialdehyde as toxic molecule and biological marker of oxidative stress. *Nutr Metab Cardiovasc Dis* 2005;15:316-28.
8. Curello S, Ceconi C, Bigoli C, Ferrari R, Albertini A, Guarnieri C. Changes in the cardiac glutathione status after ischemia and reperfusion. *Experientia* 1985;41:42-3.
9. Lee S-J, Lee SY, Ha HJ, Cha SH, Lee SK, Hur SJ. Rutin attenuates lipopolysaccharide-induced nitric oxide production in macrophage cells. *Journal of Food and Nutrition Research* 2015;3:202-5.
10. Chen WY, Huang YC, Yang ML, Lee CY, Chen CJ, Yeh CH, et al. Protective effect of rutin on LPS-induced acute lung injury via down-regulation of MIP-2 expression and MMP-9 activation through inhibition of Akt phosphorylation. *Int Immunopharmacol* 2014;22:409-13.
11. Bilgin AO, Mammadov R, Suleyman B, Unver E, Ozcicek F, Soyuturk M, et al. Effect of rutin on cytarabine-associated pulmonary oedema and oxidative stress in rats. *An Acad Bras Cienc* 2020;92:e20190261.
12. Demiryilmaz I, Turan MI, Kisaoglu A, Gulapoglu M, Yilmaz I, Suleyman H. Protective effect of nimesulide against hepatic ischemia/reperfusion injury in rats: Effects on oxidant/antioxidants, DNA mutation and COX-1/COX-2 levels. *Pharmacol Rep* 2014;66:647-52.
13. Weber B, Lackner I, Haffner-Luntzer M, Palmer A, Pressmar J, Scharffetter-Kochanek K, et al. Modeling trauma in rats: Similarities to humans and potential pitfalls to consider. *J Transl Med* 2019;17:305.
14. Bradford MM. A rapid and sensitive method for the quantitation of microgram quantities of protein utilizing the principle of protein-dye binding. *Anal Biochem* 1976;72:248-54.
15. Ohkawa H, Ohishi N, Yagi K. Assay for lipid peroxides in animal tissues by thiobarbituric acid reaction. *Anal Biochem* 1979;95:351-8.
16. Sedlak J, Lindsay RH. Estimation of total, protein-bound, and nonprotein sulfhydryl groups in tissue with Ellman's reagent. *Anal Biochem* 1968;25:192-205.
17. Bakowitz M, Bruns B, McCunn M. Acute lung injury and the acute respiratory distress syndrome in the injured patient. *Scand J Trauma Resusc Emerg Med* 2012;20:54.
18. Hoth JJ, Stitzel JD, Gayzik FS, Brownlee NA, Miller PR, Yoza BK, et al. The pathogenesis of pulmonary contusion: An open chest model in the rat. *J Trauma* 2006;61:32-44.
19. Zhang B, Wang B, Cao S, Wang Y, Wu D. Silybin attenuates LPS-induced lung injury in mice by inhibiting NF- κ B signaling and NLRP3 activation. *Int J Mol Med* 2017;39:1111-8.
20. Wang Y, Zhang J, Gao X, Li Q, Sun D. In vitro and in vivo anti-inflammatory effect of Zaluzanin D isolated from *Achillea acuminata*. *Int Immunopharmacol* 2021;90:107130.
21. Suleyman H, Cadirci E, Albayrak A, Halici Z. Nimesulide is a selective COX-2 inhibitory, atypical non-steroidal anti-inflammatory drug. *Curr Med Chem* 2008;15:278-83.
22. Kisaoglu A, Borekci B, Yapca OE, Bilen H, Suleyman H. Tissue damage and oxidant/antioxidant balance. *Eurasian J Med* 2013;45:47-9.
23. Sirmalı M, Solak O, Tezel C, Sirmalı R, Ginis Z, Atik D, et al. Comparative analysis of the protective effects of caffeic acid phenethyl ester (CAPE) on pulmonary contusion lung oxidative stress and serum copper and zinc levels in experimental rat model. *Biol Trace Elem Res* 2013;151:50-8.
24. Knapen MF, Zusterzeel PL, Peters WH, Steegers EA. Glutathione and glutathione-related enzymes in reproduction. A review. *Eur J Obstet Gynecol Reprod Biol* 1999;82:171-84.
25. Dogan G, Dogan G, Karaca O, Ayaz E. Effects of Pelargonium sidoides (UMCA ®) on pulmonary contusion from blunt thoracic trauma in rats. *Ann Med Res* 2020;27:2319-25.
26. Keskin Y, Bedel C, Gökben Beceren N. Investigation of histopathological and radiological effects of surfactant treatment in an experimental female rat model of lung contusion. *Iran J Basic Med Sci* 2019;22:1153-7.
27. Kao RL, Huang W, Martin CM, Rui T. The effect of aerosolized indomethacin on lung inflammation and injury in a rat model of blunt chest trauma. *Can J Surg* 2018;61:S208-S218.
28. Yeginsu A, Ergin M, Gurlek K, Saylan O. The effects of sildenafil on lung contusion. *Turk Gogus Kalp Dama* 2011;19:613-7.
29. Yiyit N, Türüt H, Işıtmangil T, İpçioğlu OM, Uzun G, Berber U, et al. Pulmoner kontüzyon tedavisinde yeni bir yöntem: Hiperbarik oksijen, bir deneysel çalışma. *Turk Gogus Kalp Dama* 2012;20:875-82.

30. Sirmali R, Giniş Z, Sirmali M, Solak O, Şeliman B, Ağaçkiran Y, et al. Vitamin C as an antioxidant: Evaluation of its role on pulmonary contusion experimental model. *Turk J Med Sci* 2014;44:905-13.
31. Bermansyah, Satria G, Umar A. Effectiveness of vitamin C and vitamin E antioxidant combination on caspase-3 expression in Wistar white rat pulmonum contusion. *Sriwijaya Journal of Surgery* 2020;3:31-44.
32. Gokce M, Saydam O, Hanci V, Can M, Bahadır B. Antioxidant vitamins C, E and coenzyme Q10 vs dexamethasone: Comparisons of their effects in pulmonary contusion model. *J Cardiothorac Surg* 2012;7:92.
33. Su KY, Yu CY, Chen YP, Hua KF, Chen YL. 3,4-Dihydroxytoluene, a metabolite of rutin, inhibits inflammatory responses in lipopolysaccharide-activated macrophages by reducing the activation of NF- κ B signaling. *BMC Complement Altern Med* 2014;14:21.
34. Huang YC, Horng CT, Chen ST, Lee SS, Yang ML, Lee CY, et al. Rutin improves endotoxin-induced acute lung injury via inhibition of iNOS and VCAM-1 expression. *Environ Toxicol* 2016;31:185-91.
35. Sharma S, Rabbani SA, Narang JK, Hyder Pottou F, Ali J, Kumar S, et al. Role of rutin nanoemulsion in ameliorating oxidative stress: Pharmacokinetic and pharmacodynamics studies. *Chem Phys Lipids* 2020;228:104890.
36. Nayki C, Nayki U, Keskin Cimen F, Kulhan M, Yapca OE, Kurt N, et al. The effect of rutin on ovarian ischemia-reperfusion injury in a rat model. *Gynecol Endocrinol* 2018;34:809-14.