

Videothoroscopic excision of a diaphragmatic bronchogenic cyst appearing as a pulmonary lesion

Pulmoner lezyon şeklinde gözlenen diyafragmatik bronkojenik kistin videotorakoskopik eksizyonu

Murat Kara¹, Melek Ağkoç¹, Salih Duman¹, Dilek Yılmazbayhan²

¹Department of Thoracic Surgery, Istanbul University, Istanbul Faculty of Medicine, Istanbul, Türkiye

²Department of Pathology, Istanbul University, Istanbul Faculty of Medicine, Istanbul, Türkiye

ABSTRACT

Diaphragmatic bronchogenic cysts are rare, and very few cases have been reported in the literature to date. Herein, we present a 42-year-old male patient who had a diaphragmatic bronchogenic cyst with the radiologic appearance of an intrapulmonary lesion as the 32nd case in the English literature. We performed a videothoroscopic excision of the cyst, which was later found to be originated from the diaphragm. Pathologic examination confirmed the diagnosis of the bronchogenic cyst. Diaphragmatic bronchogenic cysts may present as intrapulmonary lesions radiologically. Videothoroscopic excision is a feasible treatment method for these lesions.

Keywords: Bronchogenic cyst, diaphragm, videothoracoscopy.

Bronchogenic cysts are congenital anomalies that result from the abnormal budding of the primitive foregut during embryogenesis. The most common locations of bronchogenic cysts are the subcarinal and paratracheal areas and the lung parenchyma.^[1] They may occur in various sites, including retroperitoneum, subcutaneous tissue, and pericardium, diaphragmatic cysts, however, are exceedingly rare.^[2-4]

We are aware of very few reports of intradiaphragmatic bronchogenic cysts in the English literature.^[2,5-12] Simonetti et al.^[7] published a review of a total of 26 cases of intradiaphragmatic bronchogenic cysts reported between 1955 and 2017. We identified five additional case reports published until March 2020.^[8-12] Herein, we present the case

ÖZ

Diyafragmatik bronkojenik kistler nadirdir ve bugüne kadar literatürde bildirilmiş çok az olgu vardır. Bu makalede radyolojik olarak intrapulmoner lezyon görünümüne sahip diyafragmatik bronkojenik kisti olan 42 yaşında bir erkek hasta literatürde bildirilen 32. olgu olarak sunuldu. Sonradan diyafram kaynaklı olduğu anlaşılan kistin videotorakoskopik eksizyonu uygulandı. Patolojik inceleme bronkojenik kist tanısını doğruladı. Diyafragmatik bronkojenik kistler radyolojik olarak intrapulmoner lezyon şeklinde ortaya çıkabilir. Videotorakoskopik cerrahi eksizyon bu lezyonlar için uygun bir tedavi yöntemidir.

Anahtar sözcükler: Bronkojenik kist, diyafragma, videotorakoskopi.

of an adult male patient who had a diaphragmatic bronchogenic cyst with a radiological appearance of an intrapulmonary lesion and who underwent a video-assisted thoracoscopic surgery (VATS), which is currently the 32nd report in the English literature.

CASE REPORT

A 42-year-old male with a smoking history of 50 pack-years was admitted due to back pain. The patient had no history of trauma. Physical and laboratory examinations were within the normal limits. Indirect hemagglutination test for a possible hydatid cyst was negative. A chest X-ray showed a retrocardiac 30 mm mass in the left lower zone. Chest computed tomography revealed a 39 mm

Received: March 04, 2020 Accepted: March 28, 2020 Published online: April 27, 2022

Correspondence: Melek Ağkoç, MD. İstanbul Üniversitesi İstanbul Tıp Fakültesi, Göğüs Cerrahisi Anabilim Dalı, 34093 Fatih, İstanbul, Türkiye.
Tel: +90 534 - 810 84 85 e-mail: melek.agkoc1@gmail.com

Cite this article as:

Kara M, Ağkoç M, Duman S, Yılmazbayhan D. Videothoroscopic excision of a diaphragmatic bronchogenic cyst appearing as a pulmonary lesion. Turk Gogus Kalp Dama 2022;30(2):286-288

©2022 All right reserved by the Turkish Society of Cardiovascular Surgery.

This is an open access article under the terms of the Creative Commons Attribution-NonCommercial License, which permits use, distribution and reproduction in any medium, provided the original work is properly cited and is not used for commercial purposes (<http://creativecommons.org/licenses/by-nc/4.0/>).

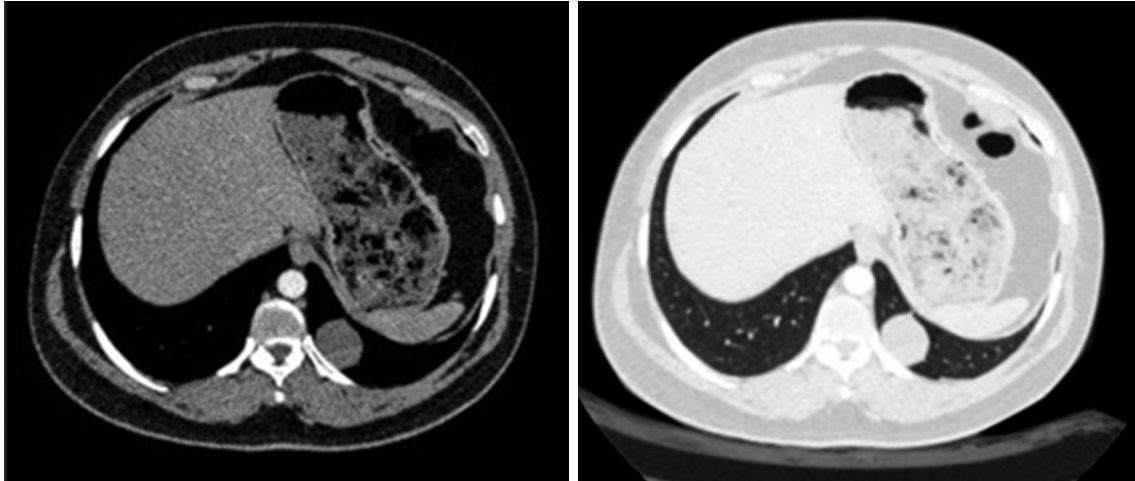


Figure 1. Computed tomography sections showing a supradiaphragmatic, well-circumscribed cystic lesion in the left lower lobe.

ovoid, well-circumscribed cystic lesion located in the medial basal segment of the left lower lobe (Figure 1). Videothoracoscopy revealed a cystic lesion of 6 cm in diameter with a pedicle arising from the muscular part of the diaphragm, which was

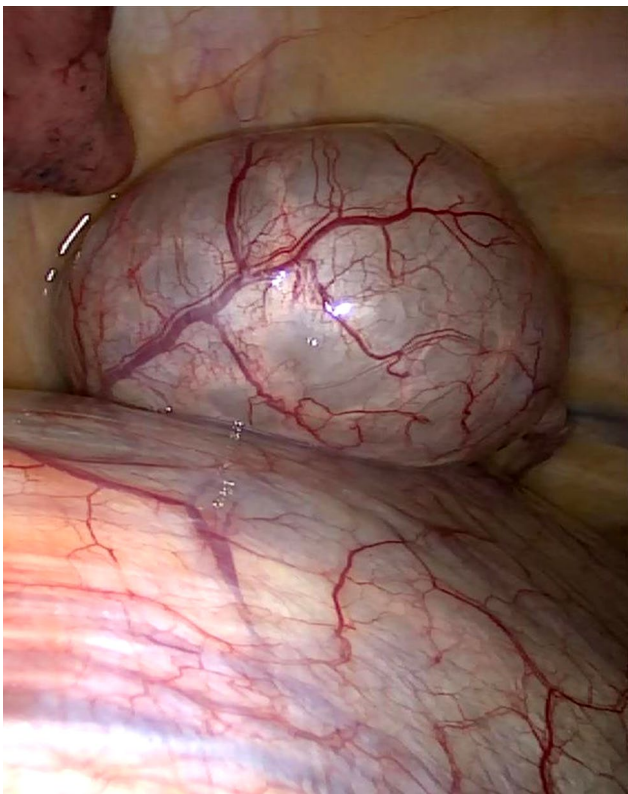


Figure 2. Videothoracoscopic view of the cystic lesion originating from the diaphragm.

located posteromedially and unrelated to the lung parenchyma (Figure 2). We excised the cyst from the diaphragm with a bipolar energy device and an endostapler. It perforated during dissection, and a thick, yellowish mucoid secretion came out of the cyst. We repaired the diaphragmatic muscle defect with No. 0 polypropylene sutures (Prolene, Ethicon, Inc., Somerville, NJ, USA). The chest tube was removed on the second postoperative day, and the patient was discharged. Pathologic examination showed a pseudostratified ciliated columnar epithelial cell-lined cyst containing smooth muscle and loose connective tissue consistent with a bronchogenic cyst (Figure 3). The patient was in good condition at postoperative four months.

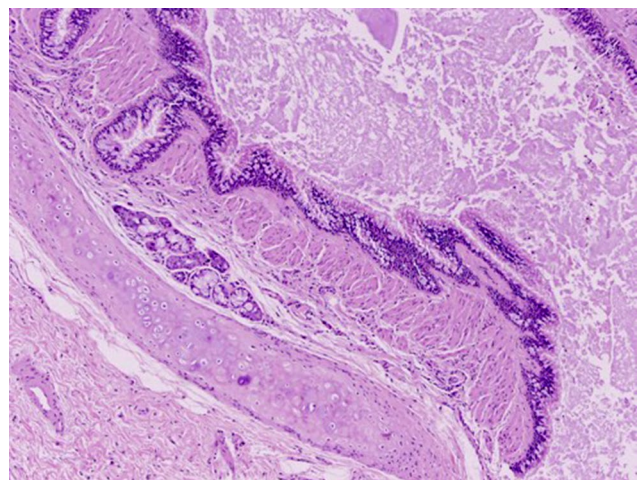


Figure 3. A pathologic section of the mass consisting of smooth muscle, loose connective tissue, and pseudostratified ciliated columnar epithelium (H&E, $\times 100$).

DISCUSSION

Bronchogenic cysts are the most common cystic lesions of the mediastinum, which are thought to arise from an accessory bud of the primitive foregut after the third week of gestation.^[1] They are associated with a heterogeneous group of bronchopulmonary malformations, such as sequestrations, congenital cystic adenomatoid malformations, and bronchial atresia.^[3] Histologically, bronchogenic cysts are lined by ciliated columnar or squamous epithelial cells with accompanied mucus-secreting gland cells that cause the cyst to fill. While bronchogenic cysts predominantly occur in the subcarinal, paratracheal area, and lung parenchyma, the location of the cyst depends on the timing of formation. Mediastinal cysts generally form during early budding and differentiation of the foregut, while peripheral intrapulmonary cysts are likely to arise when the trachea and main bronchi are formed.^[2] Diaphragmatic bronchogenic cysts are rare and thought to be formed from the accessory lung bud of the primitive foregut that migrates through the abdomen during the fusion of the pleuroperitoneal membrane.^[4]

Surgical excision of a bronchogenic cyst is recommended to relieve the symptoms and eliminate the potential risk for malignancy, even in asymptomatic cases.^[8] Excision of the cyst with VATS is a safe and feasible method for uncomplicated and peripheral lesions with minimal morbidity and mortality.^[2] Laparoscopic approaches can also be applied for the excision of intra- or subdiaphragmatic bronchogenic cysts. Complete excision is recommended to prevent recurrences and malignant degenerations. However, aspiration of the cyst or instillation of sclerosing agents can also be done to relieve symptoms in medically inoperable cases.

In conclusion, bronchogenic cysts are the most common mediastinal congenital cystic anomalies that can also be located ectopically in the thoracoabdominal cavity. However, diaphragmatic bronchogenic cysts are very rare and may present as intrapulmonary lesions radiologically. Surgical excision is required for a definite diagnosis, and video-assisted thoracoscopic surgery is a safe and effective approach for diaphragmatic cysts.

Patient Consent for Publication: A written informed consent was obtained from each patient.

Data Sharing Statement: The data that support the findings of this study are available from the corresponding author upon reasonable request.

Author Contributions: Conception, data collection and interpretation, literature review, writer, review - M.K.; Data collection and interpretation, literature review, writer - M.A., S.D.; Data collection and interpretation, materials, review - D.Y.

Conflict of Interest: The authors declared no conflicts of interest with respect to the authorship and/or publication of this article.

Funding: The authors received no financial support for the research and/or authorship of this article.

REFERENCES

1. Balçı AE, Özalp K, Ayan E, Duran M. Bronchogenic cyst in the mediastinum: A case report. *Turk Gogus Kalp Dama* 2005;13:286-9.
2. Jiang C, Wang H, Chen G, Jiang G, Zhang P. Intradiaphragmatic bronchogenic cyst. *Ann Thorac Surg* 2013;96:681-3.
3. Mubang R, Brady JJ, Mao M, Burfeind W, Puc M. Intradiaphragmatic bronchogenic cysts: Case report and systematic review. *J Cardiothorac Surg* 2016;11:79.
4. Jo WM, Shin JS, Lee IS. Supradiaphragmatic bronchogenic cyst extending into the retroperitoneum. *Ann Thorac Surg* 2006;81:369-70.
5. Subramanian S, Chandra T, Whitehouse J, Suchi M, Arca M, Maheshwari M. Bronchogenic cyst in the intradiaphragmatic location. *WMJ* 2013;112:262-4.
6. Anile M, Di Stasio M, Vitolo D, Venuta F. Intradiaphragmatic bronchogenic cyst. *Eur J Cardiothorac Surg* 2006;29:839.
7. Simonetti S, Canalís E, Macías L, Carrasco MA. Clinicopathological features of the intradiaphragmatic bronchogenic cysts: Report of a case and review of the literature. *Pathologica* 2018;110:116-20.
8. Taira N, Kawasaki H, Atsumi E, Ichi T, Kawabata T, Saio M, et al. Mucoepidermoid carcinoma of arising from a bronchogenic cyst of the diaphragm. *Ann Thorac Cardiovasc Surg* 2018;24:247-50.
9. Cheng Y, Gao Y, Juma AN, Zhang C. Delayed bleeding of coronary artery after thoracoscopic intradiaphragmatic bronchogenic cyst resection. *Zhongguo Fei Ai Za Zhi* 2018;21:649-51.
10. Ota Y, Watanabe T, Takahashi K, Suda T, Tachibana S, Matsubayashi J, et al. Bronchogenic cyst removal via thoracoscopic surgery in the prone position: A case report and literature review. *Int J Surg Case Rep* 2019;60:204-8.
11. Suzuki T, Kamata S, Sato N. A case of massive hemothorax associated with an intrathoracic bronchogenic cyst. *Gen Thorac Cardiovasc Surg* 2020;68:396-8.
12. Ikeda T, Nakano J, Sano T. Intraparenchymal bronchogenic cyst; report of a case. *Kyobu Geka* 2019;72:477-9.