

Mitral valve replacement in a 3.9-kg infant with fungal endocarditis: A case report

Fungal endokarditli 3.9 kg'lık bir yenidoğanda mitral kapak replasmanı: Olgu sunumu

Zornitsa Vassileva , Ventsislav Boshnakov , Anna Kaneva , Stojan Lazarov 

Department of Pediatric Cardiology, University National Heart Hospital, Sofia, Bulgaria

ABSTRACT

A three-month-old female infant with a structurally normal heart was diagnosed with fungal endocarditis of the mitral valve with cerebral embolism. After antifungal therapy and a valve-sparing operation with complete removal of the fungal vegetations, a relapse with complete destruction of the valve leaflets and severe mitral regurgitation with decompensated heart failure occurred three months later. A second operation with successful mitral valve replacement was performed. Non-compliance with the anticoagulant treatment with vitamin K antagonist led to thrombosis of the mitral valve prosthesis one year later, and the child died from acute pulmonary edema.

Keywords: Endocarditis, fungal, mitral valve, replacement, vegetation.

Fungal endocarditis is not frequently diagnosed in pediatrics. Ganesan et al.^[1] described 192 cases over 45 years, with the highest number in infants (93/192), including 60 in neonates. It is most often caused by *Candida* spp. and is an extremely debilitating disease with high morbidity and mortality. A high index of suspicion is needed to make a timely diagnosis.

Mitral valve replacement (MVR) in infants is a complex surgery with high mortality (up to 50%) which poses several challenges.^[2,3] First, patient-prosthesis mismatch with oversizing of the mechanical valve leading to complications such as left ventricular outflow tract obstruction or complete atrioventricular block; second, patient growth and need for

ÖZ

Kalp yapısı normal olan üç aylık kız bebeğe, serebral emboli ile mitral kapak fungal endokarditi tanısı kondu. Antifungal tedavi ve fungal vejetasyonların tamamen temizlenmesi ile kapak koruyucu ameliyat sonrasında, üçüncü ayda kapak yapraklarında tamamen tahribat ve dekompanse kalp yetmezliği ile birlikte seyreden şiddetli mitral yetmezlik ile nöks izlendi. Başarılı bir mitral kapak replasmanı ile ikinci ameliyat yapıldı. Antikoagülan tedavi ve K vitamini antagonistine hasta uyumu gösterilememesi nedeniyle, bir yıl sonra mitral kapak protezinde tromboz gelişti ve bebek akut pulmoner ödem nedeniyle kaybedildi.

Anahtar sözcükler: Endokardit, fungal, mitral kapak, replasman, vejetasyon.

subsequent reoperations, and third, need for life-long anticoagulation.

Herein, we report a case of MVR in a 3.9-kg infant with fungal endocarditis with complete destruction of the mitral valve.

CASE REPORT

A three-month-old female infant presented to the pediatrician with low-grade fever, feeding difficulties, and focal left-sided seizures. The infant was born prematurely through emergent cesarean section at 33rd gestational weeks due to maternal preeclampsia, with a birth weight of 1.35 kg. The patient was treated at the neonatal intensive care unit

Received: November 07, 2021 Accepted: February 27, 2022 Published online: July 29, 2022

Correspondence: Zornitsa Vassileva, MD. Pediatric Cardiology Department, University National Heart Hospital, Sofia, Konjovitsa 65, Sofia 1000, Bulgaria.
Tel: +359 898 319 361 e-mail: drvass@abv.bg

Cite this article as:

Vassileva Z, Boshnakov V, Kaneva A, Lazarov S. Mitral valve replacement in a 3.9-kg infant with fungal endocarditis: A case report. Turk Gogus Kalp Dama 2022;30(3):448-452

©2022 All right reserved by the Turkish Society of Cardiovascular Surgery.

This is an open access article under the terms of the Creative Commons Attribution-NonCommercial License, which permits use, distribution and reproduction in any medium, provided the original work is properly cited and is not used for commercial purposes (<http://creativecommons.org/licenses/by-nc/4.0/>).

with non-invasive ventilation and broad-spectrum antibiotic therapy. The echocardiography before discharge at the age of one month showed structurally and functionally normal heart.

At the age of three months, the infant was admitted to the pediatric pulmonology department in impaired general condition, with a weight of 3.3 kg, with low-grade fever, pale, with tachydyspnea, tachycardia, and hepatomegaly; holosystolic heart murmur, and normal neurological status. The hematological tests revealed leukocytosis, mild anemia, and elevated C-reactive protein. *Candida* spp. were isolated from all three blood cultures taken upon admission. On cranial computed tomography (CT), an irregular formation in the right frontal lobe was visualized. The echocardiography revealed an oscillating mass involving both the anterior and the posterior mitral valve (MV) leaflet and causing severe mitral regurgitation with left atrial and left ventricular dilation (Figure 1). After neurology consultation, the patient was given piracetam.

The echocardiographic findings, in combination with the new-onset heart failure symptoms and *Candida*-positive blood cultures, were consistent with the diagnosis of fungal endocarditis with cerebral embolism. After 10 days of combined antifungal therapy with amphotericin B and fluconazole and anticoagulation with unfractionated heparin, together with symptomatic heart failure treatment with diuretics and vasodilators, the infant remained in impaired

general condition, and no reduction in the size of the vegetation on the MV was observed.

The patient was indicated for surgery. The MV was accessed through standard sternotomy, right atriotomy, and transeptal access to the left atrium. Small vegetations were found on the atrial surface of the anterior leaflet, and a solitary mass of 10/10 mm was located on the ventricular surface, extending to the subvalvular apparatus. A valve-sparing operation was performed, with complete removal of the formation from the MV, preserving the integrity of the leaflets. The early postoperative period was uneventful and the result was deemed successful, without any residual formations on the MV and with a decrease in the degree of the mitral regurgitation from severe to moderate (Figure 2a).

After completion of a four-week postoperative antifungal therapy (six weeks in total), with normalization of the markers of inflammation and negative blood cultures, the patient was given oral diuretic and vasodilator and was referred to the pediatric neurology unit where a second cranial CT scan showed an ischemic lesion in the right frontal lobe and the nootropic therapy was continued.

For about three months, the infant stayed at home and did not come to the scheduled follow-up examinations owing to the novel coronavirus disease 2019 (COVID-19) pandemic. Due to several episodes

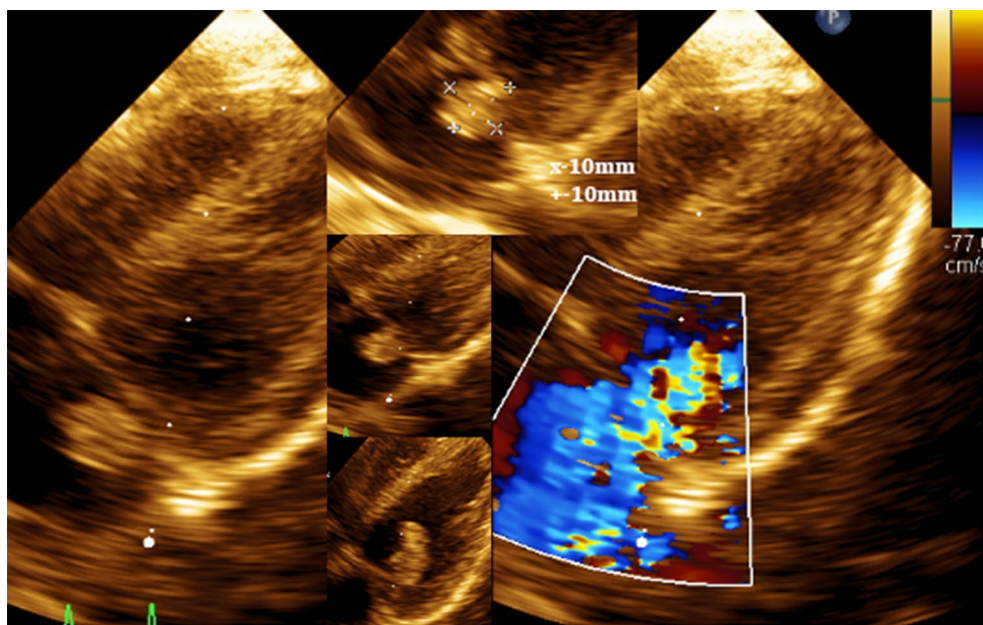


Figure 1. The mobile formation causing severe mitral regurgitation is visible.

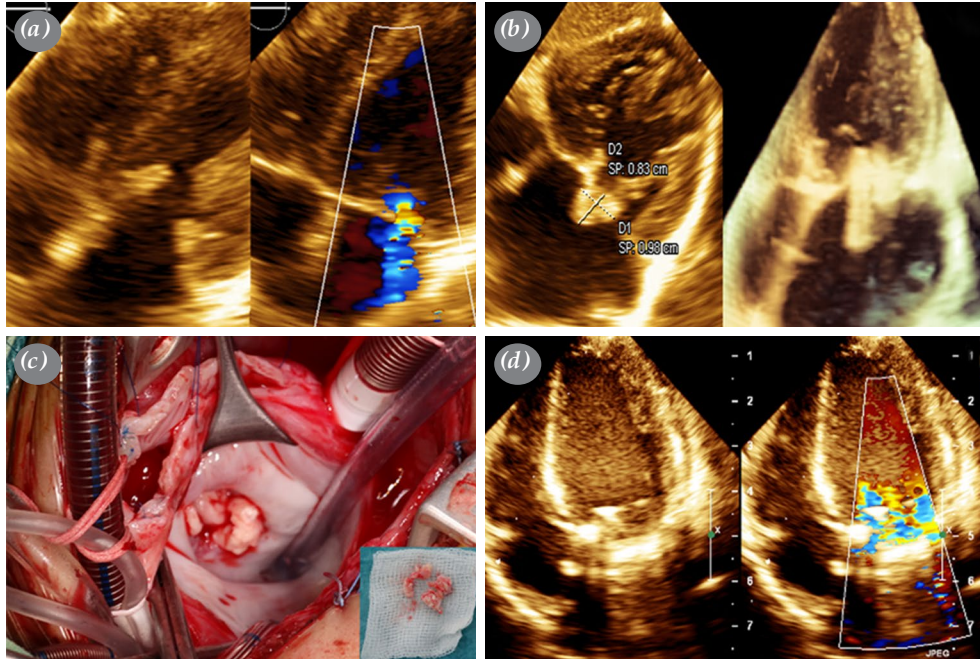


Figure 2. (a) Four-chamber view with and without color Doppler after the first operation - the vegetation from the mitral valve was completely removed and the regurgitation was mild to moderate. (b) Four-chamber view (two-dimensional and three-dimensional) showing relapse of the endocarditis on the native mitral valve. (c) Intraoperative picture at the time of the second operation on which the vegetation on the mitral valve is seen. (d) Echocardiographic image of the mitral valve prosthesis.

of low-grade fever at home, with increased respiration and feeding difficulties, the patient was re-admitted to our clinic. The physical examination revealed severe decompensated heart failure, weight of 3.9 kg, and on echocardiography vegetation on the MV with leaflet destruction and involvement of the subvalvular apparatus with severe mitral regurgitation was visualized (Figure 2b). The laboratory tests showed increased markers of inflammation and the same *Candida* spp. were isolated from three consecutive blood cultures, which confirmed the relapse of the infective endocarditis (IE).

Antifungal therapy with amphotericin B and voriconazole was started and the patient was referred for surgery under general anesthesia and extracorporeal circulation. The left atrial access was through the interatrial groove. The entire surface of the MV was involved by “cherry size” vegetations, which were protruding into the left ventricular cavity toward the chordae tendinae, reducing significantly the valve orifice area; the posterior MV leaflet was practically destroyed (Figure 2c). The remnants of the leaflets and the chordae were removed, leaving the papillary muscles intact. An Open Pivot AP (Medtronic, Inc., MN, USA) 16-mm

mechanical valve was implanted in the original MV annulus, without any obstruction of the neighboring structures (Figure 2d).

Anticoagulation with low-molecular-weight heparin (LMWH) was initiated after the intervention and the antifungal therapy with voriconazole was continued for three months. A good therapeutic effect was achieved with LMWH (anti-Xa level of 0.77 U/mL). After completion of the antifungal treatment anticoagulation with vitamin K antagonist (VKA) was started with target international normalized ratio (INR) values of 2-3. The early postoperative period was uneventful, the child was in stable condition, the MV prosthesis was functioning normally, no vegetations were visualized on the serial echocardiograms, the left atrial and left ventricular sizes were reduced, the blood cultures remained negative; the electrocardiography showed sinus rhythm, and the patient was discharged from the hospital with VKA.

On the follow-up examinations on the first, second, and the third month after discharge, the infant was in good general condition, without heart failure symptoms, with a well-functioning mechanical MV,

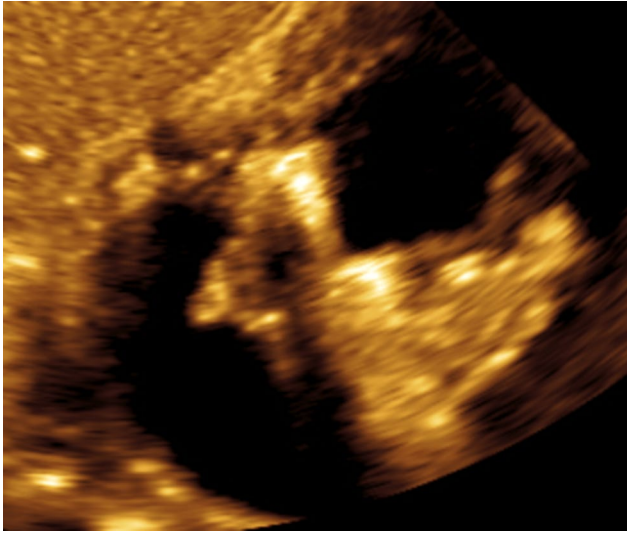


Figure 3. Thrombotic mass located on the atrial surface of the mitral valve prosthesis is visible from subcostal coronal view.

on anticoagulation with VKA with INR within the target range. The patient was lost-to-follow-up for nine months and presented at the emergency department in critical condition with pulmonary edema. The child was admitted to the intensive care unit, was intubated, and put on mechanical ventilation, and treatment with intravenous diuretics and inotropes was started. The echocardiography revealed a thrombotic mass on the atrial surface of the MV prosthesis (Figure 3). Despite intensive treatment and anticoagulation, the patient died several hours after admission.

DISCUSSION

The incidence of pediatric IE is about 0.6 cases per 100,000 per year. About 7% of the cases are diagnosed during the first month of life, 8 to 10% of the affected children have a structurally normal heart, and premature infants are at a particularly high risk^[4] Most often, central venous catheters provide a portal of entry of microorganisms. The most common causative agents by newborns are *Staphylococcus aureus*, coagulase-negative *Staphylococcus* strains, Gram-negative bacterial spp., and *Candida* spp. and *Candida*.^[5] Our patient had predisposing factors - prematurity, long intensive care unit stay with central venous line. The involvement of the left-sided heart valve could be explained by the presence of a patent foramen ovale.

Due to the left-sided endocarditis with early embolic phenomena, the patient was considered high-risk. Due to the lack of pediatric guidelines,

data are extrapolated from recommendations for adults.^[6] According to the European Society of Cardiology (ESC) 2015 guidelines for the diagnosis and management of IE, the child had Class IB indication for urgent surgery.^[7] Since the etiology of the cerebral lesion was septic embolism, the patient did not have indications for anticoagulant or antiaggregant treatment, following the ESC guidelines. Considering the low weight and the potential of valve prosthesis-patient mismatch, it was decided to perform a valve-sparing operation by the first hospital stay.

Due to the relapse of the fungal endocarditis with extensive destruction of the valve and the subvalvular apparatus, the only feasible option by the second hospital admission was complete removal and replacement of the MV. The smallest available MV prosthesis was inserted successfully, without any early complications as obstruction of the surrounding heart structures or any conduction disturbances. Vitamin K antagonist was not initially given due to the concerns about altered hepatic metabolism due to antifungal therapy and difficulties with dose adjustment.

Experience with MVR in infants and young children is limited in the literature.^[8] The most common indications are congenital heart defects (CHDs) - Schone complex, isolated MV anomalies, and atrioventricular septal defect. One of the challenges is the small size of the mitral annulus. To overcome the problem with prosthesis-patient mismatch the valve can be implanted in a supra-annular position, however, this is associated with a high rate of reoperations and pulmonary vein stenosis.^[9] Another surgical option is the placement of the stented bovine jugular vein graft (Melody™; Transcatheter Pulmonary Valve, Medtronic Inc., Minneapolis, MN, USA) in the mitral position, which offers the possibility of balloon dilation when the child grows. The short-term morbidity and mortality, however, are similar to MVR.^[10]

The lack of adequate anticoagulation after the third month after hospital discharge led to thrombosis of the mechanical valve, near-complete obstruction of the inflow to the left ventricle, post-capillary pulmonary hypertension, and pulmonary edema unresponsive to conservative treatment. Furthermore, the child was brought to the hospital in a terminal condition and could not be rescued.

In conclusion, in cases of fever, new-onset heart murmur, and heart failure symptoms, combined with neurological manifestations, particularly in children with predisposing factors, the diagnosis of infective

endocarditis should be considered. Mitral valve replacement by infants weighing less than 4 kg can come into consideration, when no other therapeutic options are left.

Patient Consent for Publication: A written informed consent was obtained from patient.

Data Sharing Statement: The data that support the findings of this study are available from the corresponding author upon reasonable request.

Author Contributions: Idea/concept, design, data collection and/or processing, writing the article: Z.V., V.B.; Control/supervision: A.K., S.L.; Analysis and/or interpretation: Z.V., A.K.; Literature review: S.L., V.B.; Critical review: A.K., S.L.

Conflict of Interest: The authors declared no conflicts of interest with respect to the authorship and/or publication of this article.

Funding: The authors received no financial support for the research and/or authorship of this article.

REFERENCES

1. Ganesan V, Ponnusamy SS, Sundaramurthy R. Fungal endocarditis in paediatrics: A review of 192 cases (1971-2016). *Cardiol Young* 2017;27:1481-7.
2. Colom Seguí M, Escribà Bori S, de la Fuente Sánchez MA, García Algas F. Mitral valve replacement in infants less than 6 months-old. *An Pediatr (Barc)* 2016;84:170-1.
3. Elmahrouk AF, Mashali MH, Ismail MF, Arafat AA, Alamri RM, Baho HA, et al. Mitral valve replacement in infants and younger children. *Sci Rep* 2021;11:15239.
4. Stockheim JA, Chadwick EG, Kessler S, Amer M, Abdel-Haq N, Dajani AS, et al. Are the Duke criteria superior to the Beth Israel criteria for the diagnosis of infective endocarditis in children? *Clin Infect Dis* 1998;27:1451-6.
5. Day MD, Gauvreau K, Shulman S, Newburger JW. Characteristics of children hospitalized with infective endocarditis. *Circulation* 2009;119:865-70.
6. Tiryakioğlu O, Tiryakioğlu Kenar S, Türk T, Özkan H, Bozart T, Yavuz Ş, et al. Timing for surgical therapy in active infective endocarditis. *Türk Gogus Kalp Dama* 2006;14:194-8.
7. Habib G, Lancellotti P, Antunes MJ, Bongiorni MG, Casalta JP, Del Zotti F, et al. 2015 ESC Guidelines for the management of infective endocarditis: The Task Force for the Management of Infective Endocarditis of the European Society of Cardiology (ESC). Endorsed by: European Association for Cardio-Thoracic Surgery (EACTS), the European Association of Nuclear Medicine (EANM). *Eur Heart J* 2015;36:3075-128.
8. Eltayeb OM, Readdy WJ, Mongé MC, Forbess JM, Sarwark AE, Patel A, et al. Mitral valve replacement in infants using a 15-mm mechanical valve. *Ann Thorac Surg* 2019;108:552-7.
9. Kanter KR, Kogon BE, Kirshbom PM. Supra-annular mitral valve replacement in children. *Ann Thorac Surg* 2011;92:2221-7.
10. Pluchinotta FR, Piekarski BL, Milani V, Kretschmar O, Burch PT, Hakami L, et al. Surgical atrioventricular valve replacement with melody valve in infants and children. *Circ Cardiovasc Interv* 2018;11:e007145.