

## An intrapericardial thymoma resected by uniportal video-assisted thoracoscopic surgery

*Uniportal video yardımlı torakoskopik cerrahi ile çıkartılmış bir perikard içi timoma olgusu*

Hasan Volkan Kara<sup>1</sup>, İsmail Sarbay<sup>1</sup>, Şebnem Batur<sup>2</sup>, Akif Turna<sup>1</sup>

<sup>1</sup>Department of Thoracic Surgery, Istanbul University-Cerrahpaşa Cerrahpaşa Faculty of Medicine, Istanbul, Türkiye

<sup>2</sup>Department of Pathology, Istanbul University-Cerrahpaşa Cerrahpaşa Faculty of Medicine, Istanbul, Türkiye

### ABSTRACT

Thymomas are usually located in the normal location of the thymus in the anterior mediastinum. It is very rare for thymomas to arise primarily intrapericardially. A 76-year-old male patient with a known human immunodeficiency virus positivity and has been under close follow-up for five years was admitted to our clinic. Thoracic computed tomography revealed an intrapericardial mass. Uniportal video-assisted thoracoscopic surgery was performed for the resection of the intrapericardial mass. Pathological examination revealed a type AB thymoma with a 3×3×2.5-cm dimensions (Stage 1). He underwent adjuvant irradiation. He has been doing well without any recurrence for 41 months. In conclusion, resection of intrapericardial masses is feasible and safe. This is the first case with a purely intrapericardial thymoma that was resected via uniportal video-assisted thoracoscopic surgery in the literature.

**Keywords:** Intrapericardial tumor, thymoma, uniportal video-assisted thoracoscopic surgery.

Thymomas are usually located in the anterior mediastinum as the normal location of the thymus.<sup>[1]</sup> Involvement of the pericardium by thymic tumors is expected in invasive or metastatic thymoma.<sup>[1]</sup> Thymomas arise primarily in the pericardium.<sup>[1]</sup> It is possible that, during the embryologic stage, some thymic tissues are left behind in the pericardium as the thymus develops.<sup>[2]</sup> Such tissue may turn into an intrapericardial tumor.<sup>[2]</sup> Intrapericardial thymomas-related sudden death events have been reported in the

### ÖZ

Timomalar, genellikle ön mediastinumda timusun normal yerleşiminde izlenir. Timomaların perikard içinde bulunması son derece nadirdir. Yetmiş altı yaşında bilinen insan immün yetmezlik virüs enfeksiyonu olan ve bu hastalık nedeni ile beş yıldır takip edilen hasta kliniğimize başvurdu. Toraks bilgisayarlı tomografisinde intraperikardial kitle saptandı. Uniportal video yardımlı torakoskopik cerrahi ile intraperikardiyal kitle rezekt edildi. Patolojik incelemede 3×3×2.5-cm çapında tip AB timoma (Evre 1) raporlandı. Hastaya adjuvan radyoterapi verildi. Hasta 41 aydır nüks olmadan yaşamını sürdürmektedir. Sonuç olarak, intraperikardiyal kitlelerin rezeksiyonu uygulanabilir ve güvenlidir. Bu, literatürde uniportal video yardımlı torakoskopik cerrahi ile rezekt edilen tamamen intraperikardiyal yerleşimli ilk olgudur.

**Anahtar sözcükler:** İntraperikardiyal tümör, timoma, uniportal video yardımlı torakoskopik cerrahi.

literature.<sup>[3]</sup> Some of the cases were diagnosed during autopsies.<sup>[3]</sup>

In this article, we report a case operated in a certain way that has never been reported before for pericardial thymoma.

### CASE REPORT

A 76-year-old male patient was referred to our department after a computed tomography (CT) scan

Received: August 31, 2020 Accepted: November 02, 2020 Published online: July 29, 2022

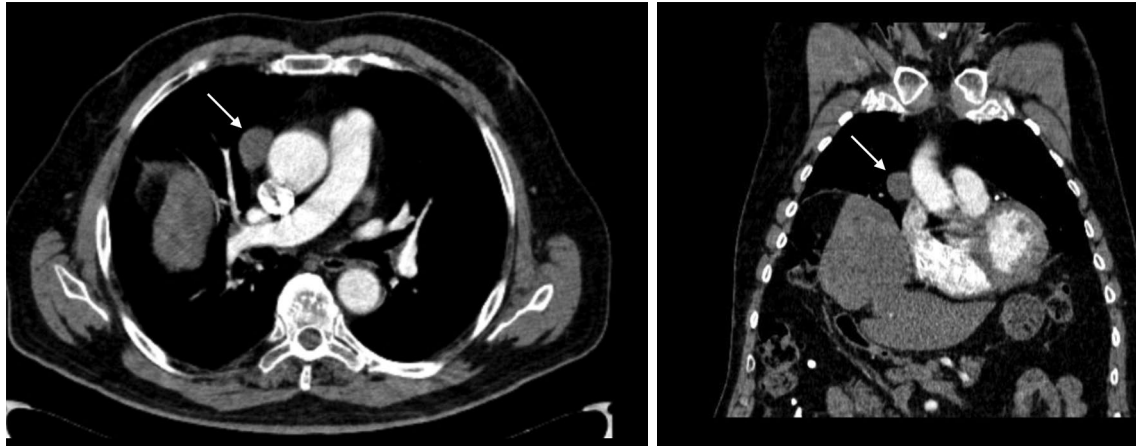
**Correspondence:** Akif Turna, MD. İstanbul Üniversitesi-Cerrahpaşa Cerrahpaşa Tıp Fakültesi, Göğüs Cerrahisi Anabilim Dalı, 34098 Fatih, İstanbul, Türkiye. Tel: +90 212 - 414 33 27 e-mail: akif.turna@gmail.com

#### Cite this article as:

Kara HV, Sarbay İ, Batur Ş, Turna A. Treatment options for synchronous lung and esophagus tumors. Turk Gogus Kalp Dama 2022;30(3):458-461

©2022 All right reserved by the Turkish Society of Cardiovascular Surgery.

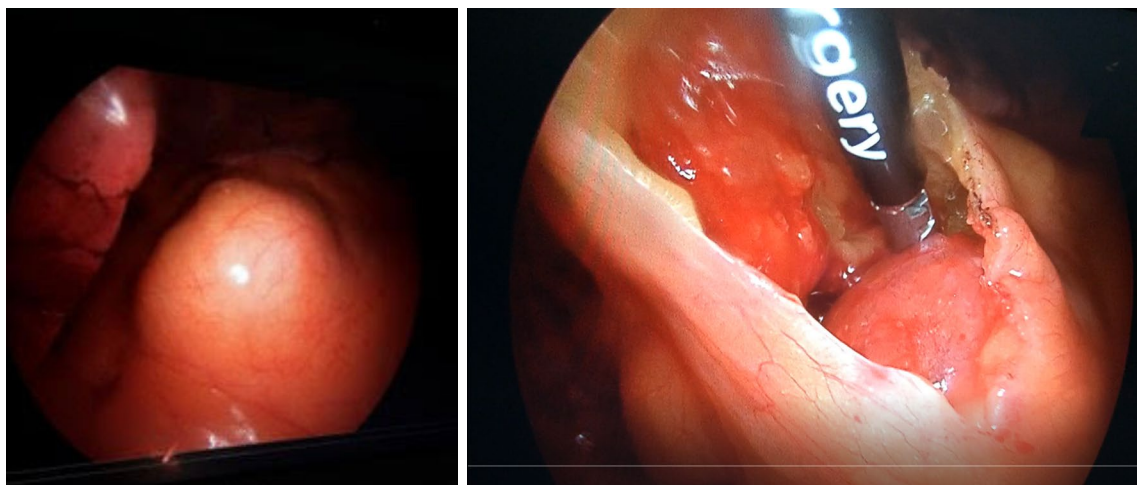
This is an open access article under the terms of the Creative Commons Attribution-NonCommercial License, which permits use, distribution and reproduction in any medium, provided the original work is properly cited and is not used for commercial purposes (<http://creativecommons.org/licenses/by-nc/4.0/>).



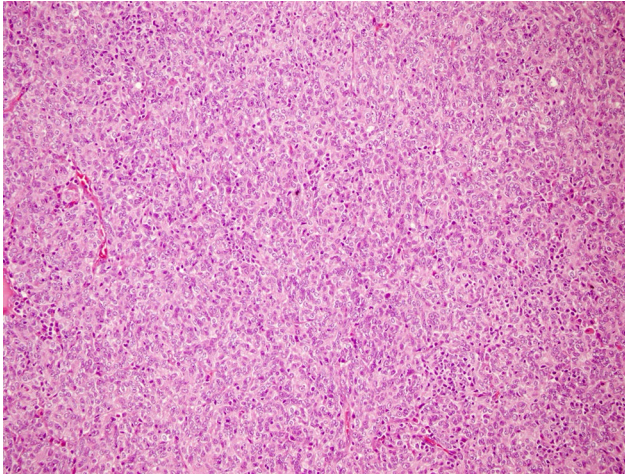
**Figure 1.** Chest computed tomography showing the mass (arrow) located right next to the ascending aorta.

revealing a right intrapericardial mass. He had no relevant medical history other than hypertension. The patient was a non-smoker. His vitals were normal and routine laboratory results were unremarkable. He has been human immunodeficiency virus (HIV)-positive for five years with normal CD4+ T lymphocytes. A chest CT showed a 2.7-cm long, round-shaped intrapericardial mass with soft tissue density (Figure 1) other than Chiladiti syndrome. The mass was located adjacent to ascending aorta. Electrocardiography showed normal sinus rhythm. Transthoracic echocardiography did not detect any other abnormalities. A thoracic magnetic resonance imaging (MRI) revealed a tissue plane between the aorta and the mass. Pulmonary function test was between normal limits. Under general

anesthesia a single 3-cm incision at the fourth intercostal space from the anterior axillary line to explore the mass directly. The chest cavity showed no abnormalities other than elevated hemidiaphragm. The intrapericardial mass was resected totally (Figure 2). The pericardial defect was primarily sutured using 3/0 polypropylene (Ethicon Inc., Johnson & Johnson, Somerville, NJ, USA). Postoperative course was uneventful and the patient was discharged the next day. Pathological examination showed a spindle type AB thymoma with abundant T lymphocytes (Figure 3). There was no microscopic capsular invasion. The tumor was a Stage 1 tumor according to the Masaoka-Koga staging system, T1N0M0 according to the International Association for the Study of Lung Cancer (IASLC)/



**Figure 2.** Left sided image shows the intrapericardial protuberance upon exploration whereas right sided.



**Figure 3.** Pathological analysis of specimen as a type AB thymoma consisting of bland spindle to oval cells with few lymphocytes (H&E,  $\times 200$ ).

International Thymic Malignancy Interest Group (ITMIG) The patient received adjuvant radiotherapy targeted to pericardium. The patient has been doing well for 41 months.

## DISCUSSION

Herein, an intrapericardial Stage 1 type AB thymoma was completely resected with surrounding fatty tissue. In our patient, there was no anterior mediastinal mass. Therefore, thymoma should be named an ectopic intrapericardial thymoma. Stage of this 2.7-cm type A tumor according to Masaoka-Koga system was Stage 1, whereas it was a T1aN0M0 tumor according to 8<sup>th</sup> staging system.<sup>[4]</sup> However, the usability of these systems is questionable, since tumor location is eccentric. Therefore, there is a need for a specific distinction in the expanding chapter of ectopic thymomas.<sup>[5]</sup> Surgical approach is still controversial; however, the entity was reported to cause sudden death in a patient.<sup>[3]</sup> Caramori et al.<sup>[6]</sup> reported a case with an intrapericardial thymoma that was resected via multiportal videothoracoscopy. However, this tumor was previously evaluated to be thymic cyst. Weissferdt and Moran<sup>[7]</sup> also reported a surgically resected ectopic pericardial thymoma case. However, there is no clear definition whether this pericardial thymoma was intrapericardial or extrapericardial, since they reported the tumor as a pericardial tumor. Also, the surgical approach was not mentioned in the report. It should be noted that extrapericardial ectopic thymomas are not rare.<sup>[2]</sup>

The role of HIV in the pathogenesis of thymoma is unknown. Nonetheless, the patient's CD4+

T lymphocyte count was normal and he has been symptom free for three years.

In our patient, we could not perform a preoperative biopsy due to location of the tumor. The tumor was resected completely.

As it has been well described in the literature, complete (i.e. R0) resection is of great importance in the treatment of thymic tumors. Adjuvant radiotherapy is recommended in patients in whom the resectional margin is unknown or patients with Stage 2 or Stage 3 thymoma.<sup>[8]</sup> We were able to perform complete resection of tumor with fatty tissue. However, adjuvant radiotherapy was given due to the fact that microscopic foci were found in the pericardial peritumoral fatty tissue. Thanks to the minimally invasive nature of the uniportal video-assisted thoracoscopic surgery (VATS) approach, the patient needed only one day of hospitalization. Since the patient has been well without any recurrence for 41 months, it is plausible to speculate that surgical resection of the thymoma with intrapericardial fatty tissue dissection followed by adjuvant radiotherapy seems to be curative in this extremely rare entity.

To the best of our knowledge, our patient is the only case with resected purely intrapericardial tumor in the literature. Our case is also the first case who underwent uniportal VATS resection for an intrapericardial tumor. Even the tumor was staged as Stage 1 tumor, staging protocol for thymoma does not consist any special definition for intrapericardial tumors.

In conclusion, very rare pure intrapericardial thymomas can be completely and safely resected via uniportal videothoracoscopic approach. However, evaluation of large case series is warranted to define the treatment of choice in patients with an intrapericardial thymoma.

**Patient Consent for Publication:** A written informed consent was obtained from patient.

**Data Sharing Statement:** The data that support the findings of this study are available from the corresponding author upon reasonable request.

**Author Contributions:** Conception, design: H.V.K.; Writing manuscript, literature review, data collection: İ.S.; Materials: Ş.B.; Writing manuscript, design, critical review, supervision: A.T.

**Conflict of Interest:** The authors declared no conflicts of interest with respect to the authorship and/or publication of this article.

**Funding:** The authors received no financial support for the research and/or authorship of this article.

## REFERENCES

1. Bläker H, Dragoje S, Laissue JA, Otto HF. Pericardial involvement by thymomas. Entirely intrapericardial thymoma and a pericardial metastasis of thymoma with glomeruloid vascular proliferations. *Pathol Oncol Res* 1999;5:160-3.
2. McAllister HA, Fenoglio JJ, editors. Tumors of the cardiovascular system. Fascicle 15, 2nd ed. In: Atlas of tumor pathology. Washington, DC: Armed Forces Institute of Pathology; 1978.
3. Turkmen N, Eren B, Comunoglu N, Fedakar R, Senel B. Pericardial thymoma: An unusual cause of sudden death. *Ann Acad Med Singap* 2008;37:253-4.
4. Dettnerbeck FC, Stratton K, Giroux D, Asamura H, Crowley J, Falkson C, et al. The IASLC/ITMIG Thymic Epithelial Tumors Staging Project: proposal for an evidence-based stage classification system for the forthcoming (8th) edition of the TNM classification of malignant tumors. *J Thorac Oncol* 2014;(9 Suppl 2):S65-72.
5. Mirra M, Zanella M, Bussani R, Falconieri G. Intrapericardial thymoma: Report of two incidental autopsy cases and review of the literature. *Arch Pathol Lab Med* 1997;121:59-63.
6. Caramori G, Calia N, Pasquini C, Arar O, Ravenna F, Guzzinati I, et al. Ectopic thymoma simulating a pericardial cyst. *Monaldi Arch Chest Dis* 2005;63:230-3.
7. Weissferdt A, Moran CA. The spectrum of ectopic thymomas. *Virchows Arch* 2016;469:245-54.
8. Ahmad U, Huang J. Tumors of the thymus in in shields' general thoracic surgery. eds: In: Locicero J, Feins RH, Colson YL, Rocco G, editors. 8th ed. Philadelphia: Wolters Kluwer; 2019. p. 2144-60.